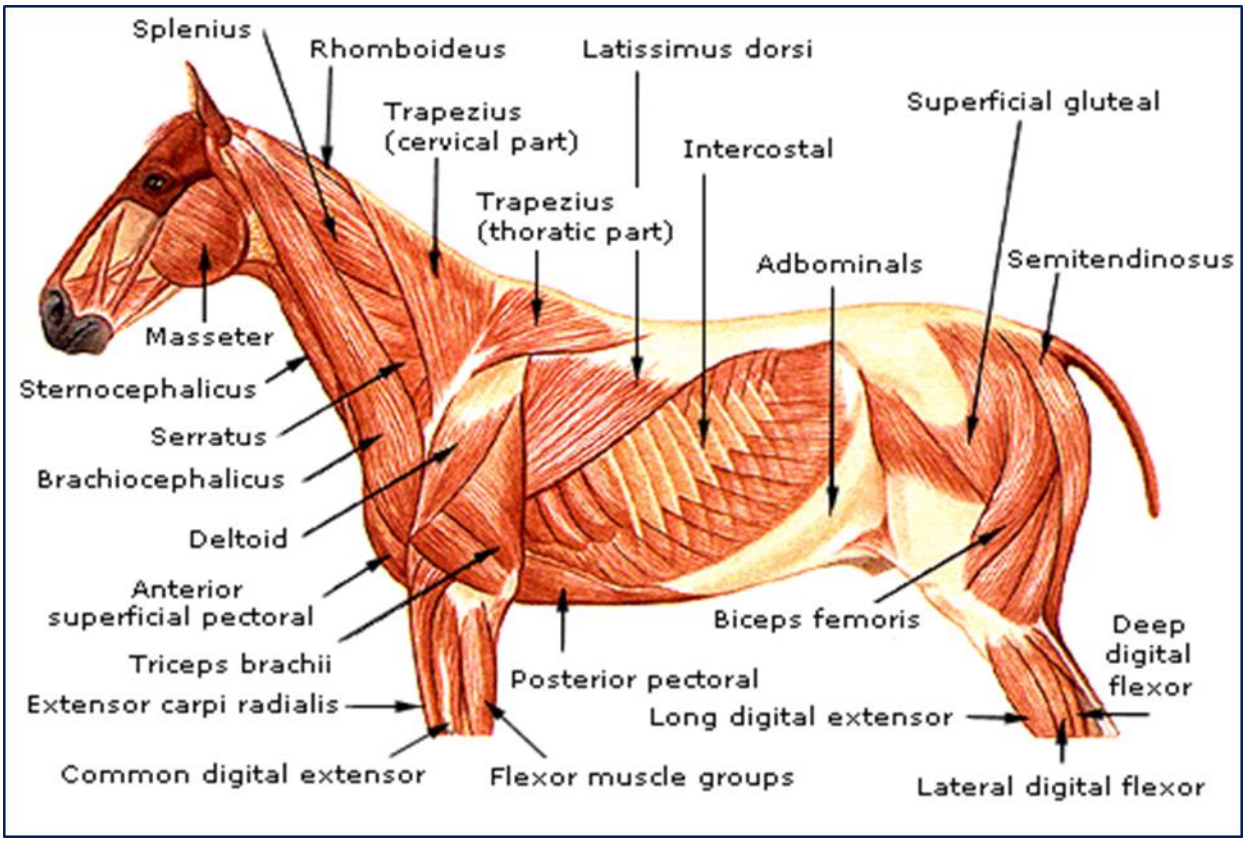
Splenius
Rhomboideus
Latissimus dorsi
Trapezius (cervical part)
Superficial gluteal
Intercostal
Trapezius (thoratic part)
Adbominals
Semitendinosus
Masseter
Sternocephalicus
Serratus
Brachiocephalicus
Deltoid
Anterior superficial pectoral
Biceps femoris
Deep digital flexor
Triceps brachii
Posterior pectoral
Extensor carpi radialis
Long digital extensor
Common digital extensor
Flexor muscle groups
Lateral digital flexor

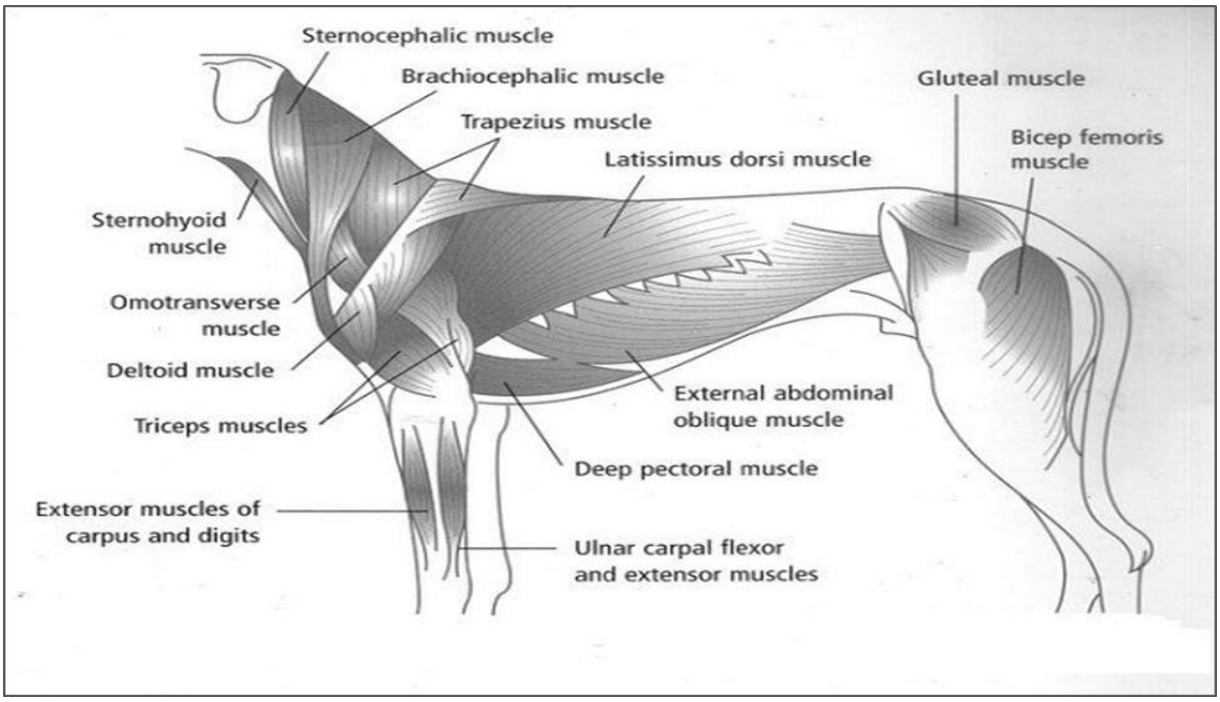
Sternocephalic muscle
Brachiocephalic muscle
Gluteal muscle
Trapezius muscle
Bicep femoris muscle
Latissimus dorsi muscle
Sternohyoid muscle
Omotransverse muscle
Deltoid muscle
External abdominal oblique muscle
Triceps muscles
Deep pectoral muscle
Extensor muscles of carpus and digits
Ulnar carpal flexor and extensor muscles

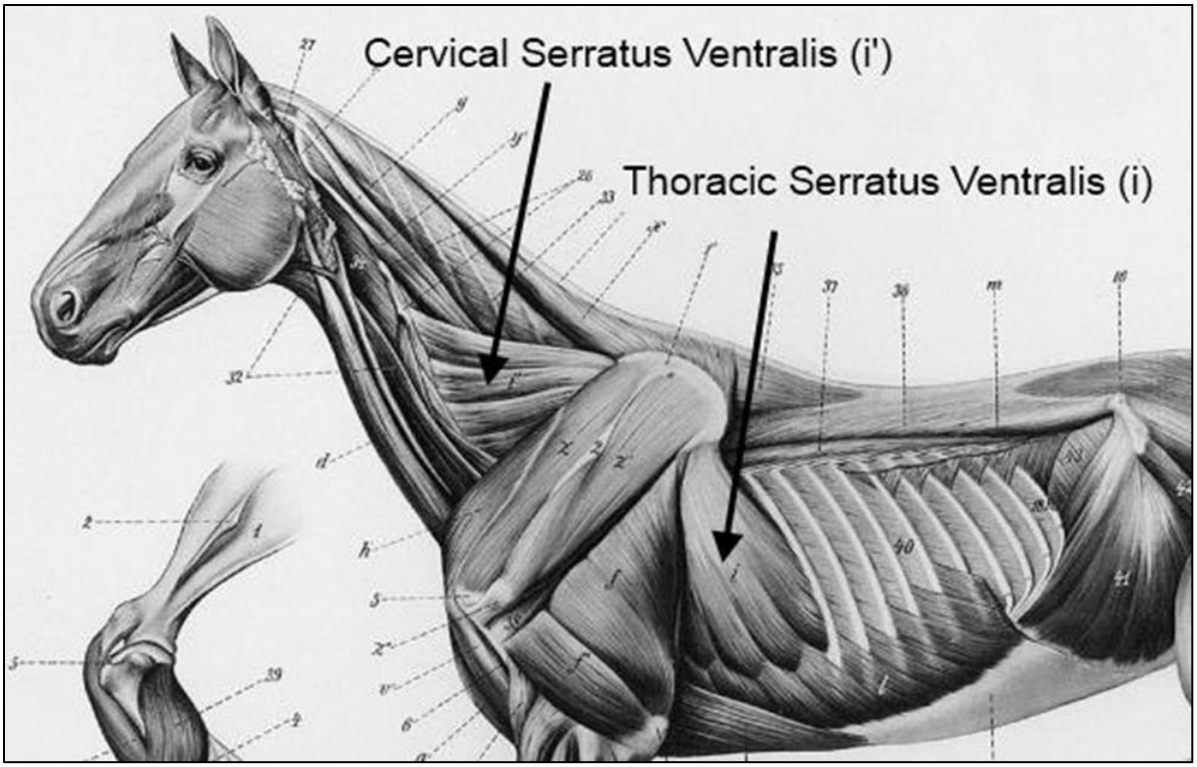
Cervical Serratus Ventralis (i')
Thoracic Serratus Ventralis (i)