

## Muscles of neck

### ❖ The Muscles of neck comprise two pairs:

#### A. Lateral cervical muscles.

1. Cutaneous colli(in both lateral & ventral aspect).
2. Brachiocephalicus muscles.
3. trapezius cervicalies.
4. Serratus cervicis.
5. Rhombideus cervicalis.
6. Splenis muscles.
7. Omotransversarius.
8. Longissmus atlantis.
9. Longissmus capitis.

#### B. Ventral cervical muscles.

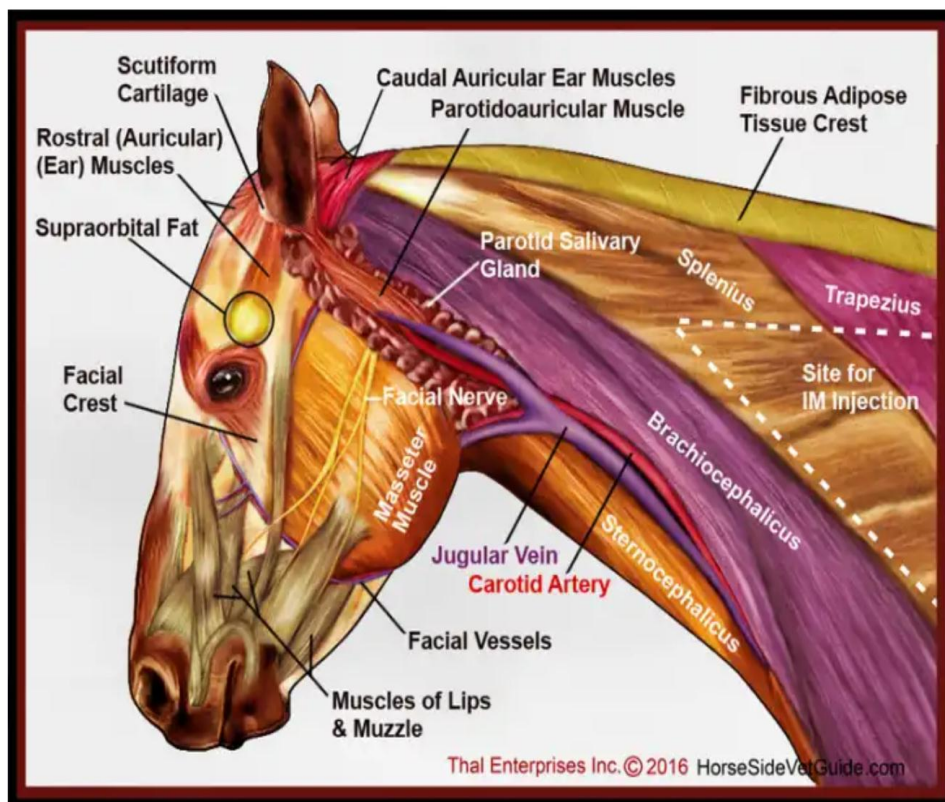
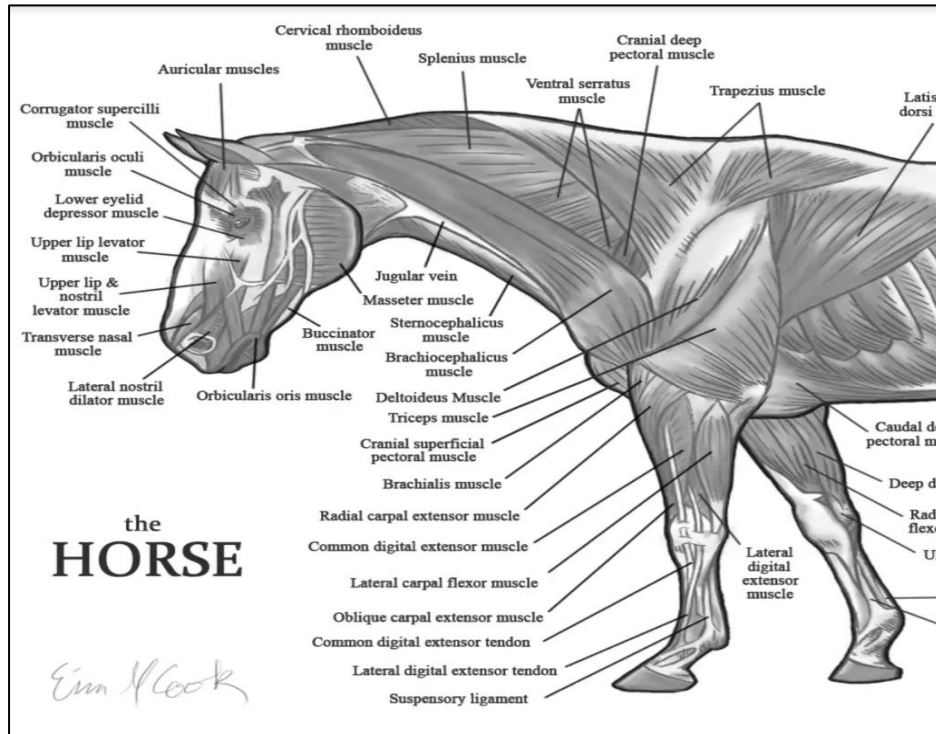
1. Cutaneous colli(in both lateral & ventral aspect).
2. Sternocephalicus muscles.
3. Sternothyrohyoideus muscles.
4. Omohyoideus muscles.

### ❖ Other structure found in the neck

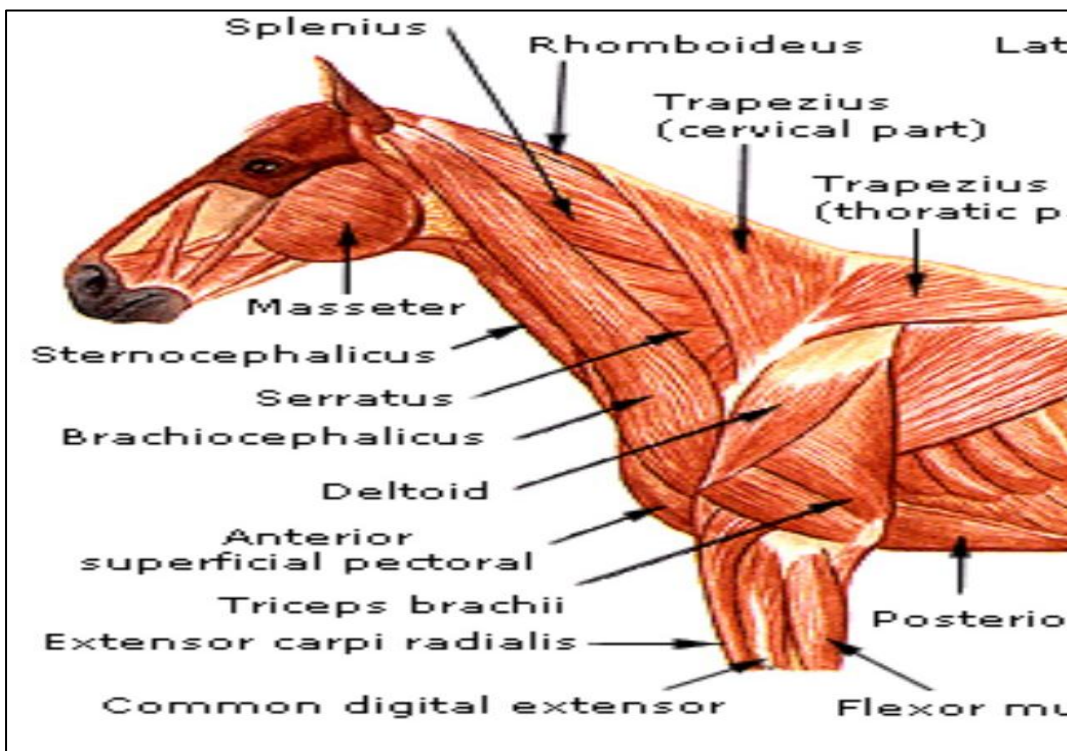
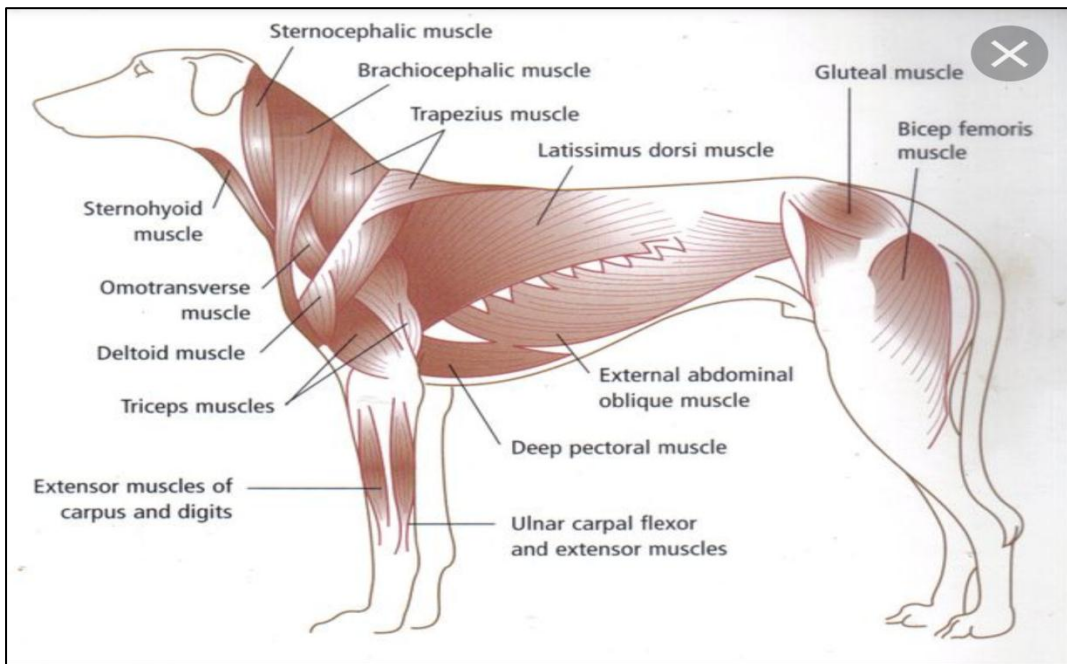
1. Nuchal ligment.
2. Jugular vein.
3. Carotid sheath(common carotid artery,vagosympathetic nerve ,recurrent nerve).
4. trachea .
5. esophagus.

## Muscles of neck

### 6. Thyroid gland.



## Muscles of neck



## Muscles of neck

