

Diseases of Testes and Scrotum 2017-2018

Testicular maldescent

1. Incomplete descent of the testis: the testis is arrested in some part of its path to the scrotum.

2. Ectopic testis: the testis is abnormally placed outside this path.

Incompletely descended testis

Incidence:

1. About 4% of full-term boys have unilateral or bilateral undescended testes (cryptorchidism).

2. The incidence is higher in preterm infants because the testis descends through inguinal canal during the third trimester of pregnancy. The prevalence of cryptorchidism is 30% in premature male neonates.

3. In 10% of unilateral cases there is a family history.

4. About 70% of cryptorchid testicles spontaneously descend within the first year of life (most occurring in the first 3 months of life).

Predisposing Factors: prematurity, low birth weight, small size for gestational age, twinning, and maternal exposure to estrogen during the first trimester.

Aetiology

1. Abnormal descent of gubernaculum.

2. Intrinsic testicular defect: insensitive to gonadotropins.

3. Deficient maternal gonadotropic hormonal stimulation.

Presentation

1. More common on the right side.

2. Bilateral in 20% of cases.

3. Approximately 80% of undescended testes are palpable and 20% are nonpalpable. Nonpalpable testes may be intra-abdominal or absent. Palpable testes may be undescended, ectopic, or retractile.

4. Hypoplastic hemiscrotum.

Treatment

Treatment choices may include

1. watchful waiting,
2. hormonal treatment, or
3. surgery.

In clinical practice, the choice of initial therapy is often selected on the basis of age at presentation and the location of the cryptorchid testicle.

Watchful waiting may be used in boys 1 year of age with low-lying testis in whom spontaneous descent is still a realistic possibility. Hormonal and surgical options are primarily selected on the basis of location and appearance of the undescended testicle. Hormonal treatment with luteinizing hormone releasing hormone (LHRH) analogs and/ or human chorionic gonadotropin (hCG) could theoretically increase circulating androgens that may, in turn, promote testicular descent. Surgical options include various forms of orchiopexy or orchiectomy.

Hazards of Incomplete descent

1. Psychological impact
2. Sterility in bilateral cases
3. Pain as a result of trauma
4. An associated indirect inguinal hernia is often present
5. Torsion
6. Epididymo-orchitis in an incompletely descended right testis can mimic appendicitis.
7. Atrophy of an inguinal testis before puberty may be possibly caused by recurrent minor trauma.
8. Increased liability to malignant disease.

Ectopic testis

The **sites** of ectopic testis are:

1. At the superficial inguinal ring
2. In the perineum
3. At the root of the penis
4. In the femoral triangle.

Absent testis

1. Vanishing testis describes a condition in which a testis develops but disappears before birth. The most likely cause is prenatal torsion.
2. True agenesis of the testis is rare.

Retractile Testis

1. Common requiring no treatment but only monitoring.

2. Occur due to strong cremasteric contraction in cold weather, excitement, and physical activity.
3. Normally developed scrotum
4. Able to bring testis to the normal position.

Torsion of the testis:

Predisposing causes:

1. An abnormally high attachment of the tunica vaginalis predispose to torsion- the bell-clapper.
2. Separation of the testis from the epididymis- torsion about the pedicle between them.
3. Torsion of the appendages of the testis.

Clinical Features

1. Is most common between 10-25 years of age although a few cases occur in infancy.
2. Symptoms vary with degree of torsion most commonly there is sudden agonizing pain in the groin and lower abdomen.
3. Nausea and may be vomiting.
4. O/E: the testis seems high and the tender twisted cord can be palpated above it.
5. Elevation of testis worsening pain. Prehn's sign describes the (relief of pain with elevation of the testicle and) was used to distinguish epididymitis from torsion since the pain associated with torsion is usually not relieved with elevation of the testicle (ie, positive Prehn's = epididymitis).
6. Several studies have found **loss of the cremasteric reflex** to be the most accurate sign of testicular torsion. This reflex is elicited by stroking the ipsilateral thigh which leads to reflex elevation of the ipsilateral testicle by greater than 0.5cm.

Diagnosis

1. History & physical examination
2. Doppler U/S scan will confirm absence of blood supply to affected testis.

Treatment:

1. In the first hour it may be possible to untwist the testis by gentle manipulation.
2. Definitive treatment is Surgical Exploration with orchidopexy of the affected and the contralateral sides.

3.Orchidectomy for non-viable infarcted testis.

Epididymo-orchitis

Epididymitis is inflammation confined to the epididymis. Infection spreading to the testis is epididymo-orchitis.

Mode of infection

- 1.Infection reaches epididymis via vas from primary infection of urethra, prostate or seminal vesicle.
- 2.In men with outflow obstruction, epididymitis may result from secondary urinary infection.
- 3.In young men the most common sexually transmitted infection causing epididymitis is now Chlamydia but gonococcal epididymitis is still prevalent both cause urethritis.
- 4.Blood borne infections are less common.

Causes:

- 1.Urethral instrumentation and urethral catheterization with urinary tract infection.
- 2.Urethral stricture.
- 3.Post-prostatectomy.
- 4.Tuberculosis.
- 5.Mumps

Presentation

- 1.The initial symptoms are those of urinary infection, later an ache in the groin and fever herald onset of epididymitis.
- 2.The epididymis and testis swell and become painful and scrotal wall at first red, oedematous and shiny.
- 3.occasionally an abscess may form and discharge of pus may occur through scrotal skin.

Diagnosis

1. History & physical examination
2. GUE and Culture
3. Colour Doppler ultrasound

Treatment

1. Antibiotics
2. Elevation and scrotal support.
3. If suppuration occur, drainage is necessary.

Varicocele

The term varicocele specifically refers to dilatation and tortuosity of the pampiniform plexus, which is the network of veins that drain the testicle.

The small vessels of the pampiniform plexus normally range from 0.5–1.5 mm in diameter. Dilation of these vessels greater than 2 mm is called a varicocele.

Aetiology

1. **Idiopathic varicocele**: occurs when the valves within the veins along the spermatic cord do not work properly.
2. 98% of idiopathic varicoceles occur on the **left side**, apparently because the left testicular vein connects to the renal vein (and does so at a 90-degree angle), while the right testicular vein drains at less than 90-degrees directly into the significantly larger inferior vena cava. Isolated right sided varicoceles are rare.
3. **Secondary varicocele** is due to compression of the venous drainage of the testicle. A pelvic or abdominal malignancy is a definite concern when a right-sided varicocele is newly diagnosed in a patient older than 40 years of age. The most common cause is renal cell carcinoma (hypernephroma) followed by retroperitoneal fibrosis or adhesions. One non-malignant cause of a secondary varicocele is the so-called "Nutcracker syndrome", a condition in which

the **superior mesenteric artery** compresses the left renal vein, causing increased pressures there to be transmitted retrograde into the left pampiniform plexus.

Diagnosis

1. Palpating a varicocele can be likened to feeling **a bag of worms**. When one is lying down, gravity may allow the drainage of the **pampiniform plexus** and thus make the mass not obvious.

2. The testicle on the side of the varicocele may or may not be smaller compared to the other side.

3. Grades of varicocele

Grade 1 The varicocele is only felt when the patient bears down.

Grade 2 The varicocele can be felt, but not seen.

Grade 3 The varicocele is large enough to be visible.

4. Varicocele can be reliably diagnosed with **ultrasound** which will show dilation of the vessels of the pampiniform plexus to greater than 2 mm. Doppler ultrasound is a technique of measuring the speed at which blood is flowing in a vessel. An ultrasound machine that has a Doppler mode can see blood reverse direction in a varicocele with a Valsalva, increasing the sensitivity of the examination.

Treatment

1. Varicolectomy, the surgical correction of a varicocele.
2. An alternative to surgery and in recurrent cases, **embolization** is considered, a minimally invasive treatment for varicocele that is performed by an **interventional radiologist**. This involves passing a small wire through a peripheral vein and into the abdominal veins that drain the testes.

Hydrocele

Is an abnormal collection of serous fluid in a part of processus vaginalis, usually the tunica.

Pathophysiology ana Aetiology

A hydrocele can be produced in 4 different ways:

1.Excessive production of fluid within the sac e.g secondary hydrocele(acute and chronic epididymo-orchitis, torsion, and testicular tumours)..

2. Defective absorption of fluid. This appears to be the explanation for most primary hydroceles.?

3. Interference with lymphatic drainage of scrotal structures.

4. Connection with peritoneal cavity (Congenital).

Hydrocele fluid contains albumin and fibrinogen.

Clinical Features

1. **Primary vaginal hydrocele** is most common in middle and later life but can also occur in older children.

2. Painless Scrotal swelling and the testis may be palpable within a lax hydrocele.

3. O/E: Hydrocele typically translucent and is possible to 'get above the swelling'.

4. In **congenital hydrocele**, the processus vaginalis is patent and connect with peritoneal cavity and the fluid may drain into peritoneal cavity when the child is lying down.

5. **Encysted hydrocele** of the cord is a smooth oval swelling near the spermatic cord.

6. **Hydrocele of canal of Nuck** : the cyst lies in relation to the round ligament in females.

Complications:

1. Infection

2. Transformation into hematocele after trauma or spontaneous bleeding into the sac.

3. Rupture is rare.

4. The sac may calcify.

Treatment

1. Congenital hydrocele is treated by herniotomy.

2. Established acquired hydrocele: Surgery (**Lord's operation and Jaboulay's**)

3. Secondary hydrocele subsides when the primary lesion resolves.

Spermatocele

Is a unilocular cyst and typically lies above and behind the upper pole of testis. It transilluminates and its fluid contains spermatozoa and resembles barely water in appearance.

Treatment

Small spermatoceles can be ignored. Larger ones should be aspirated or excised.

Idiopathic Scrotal Gangrene (Fournier's Gangrene)

It is a vascular disaster of infective origin that is characterized by:

- 1.Sudden scrotal inflammation.
- 2.Rapid onset of gangrene leading to exposure of the scrotal contents.
- 3.The absence of any obvious cause in over half the cases.

Predisposing Factors

Diabetes mellitus, it can follow minor injuries or procedures in the perineal area such as bruise, scratch, urethral dilatation, injection of hemorrhoids, or opening of a periurethral abscess.

Causative Organisms

Hemolytic streptococci are associated with other organisms(staphylococcus, E.coli, Clostridium welchi) in a fulminating inflammation of the subcutaneous tissue, which results in an obliterative arteritis.

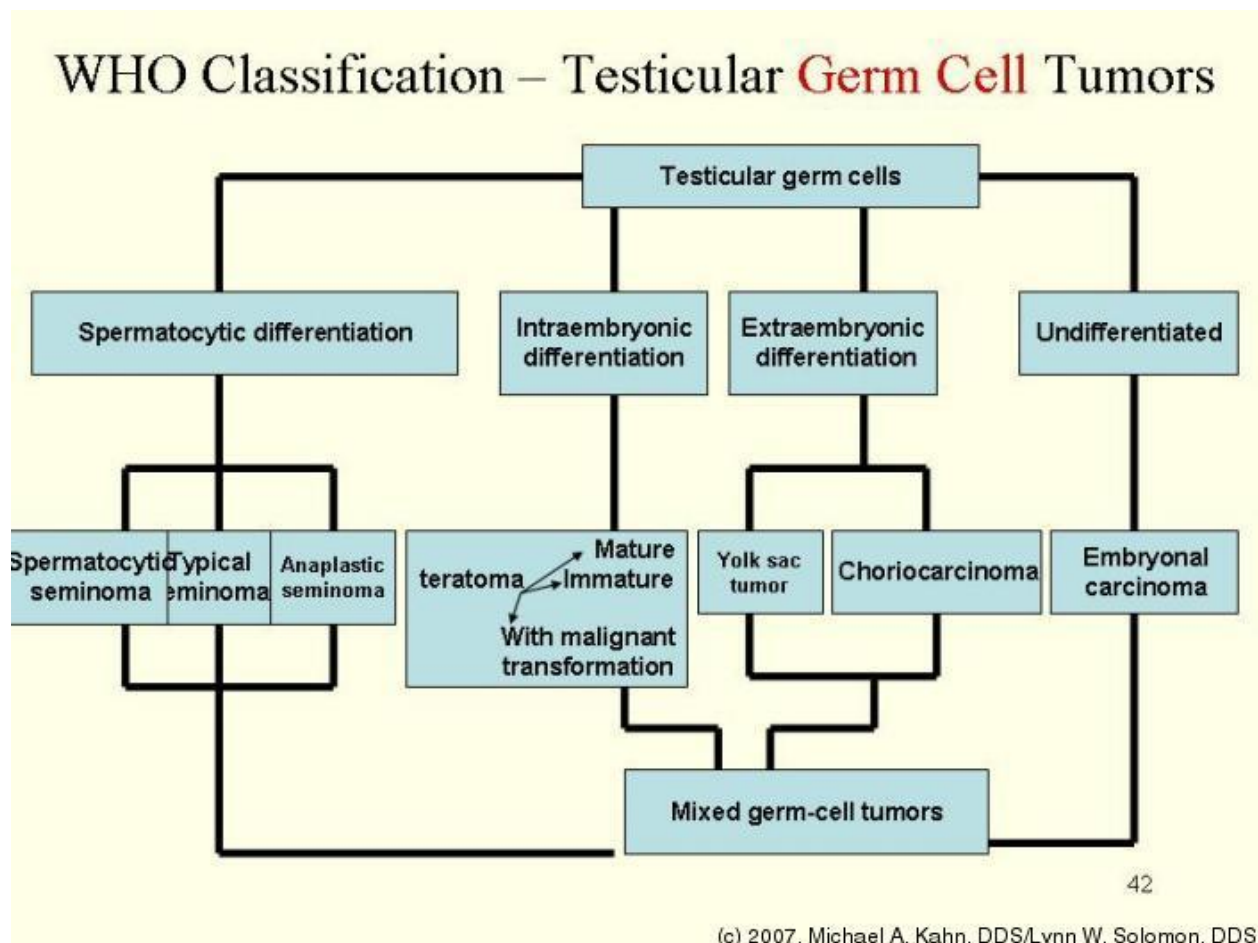
Clinical Features:

- 1.Sudden pain in the scrotum.
- 2.prostration.
- 3.pallor and pyrexia.
- 4.Cellulitis spreads until the entire scrotal covering sloughs, leaving the testes exposed but healthy.
- 5.Crepitus which may spreads along the fascial planes.

Treatment

1. Swab for culture and sensitivity.
2. Antibiotics like gentamicin and cephalosporin until the bacteriological report is available.
3. Wide local excision of the necrotic scrotal skin.

Testicular Tumours



Secondary Testicular Tumours

1.Lymphoma is the most common **secondary** testicular cancer. It occurs more often than primary testicular tumors in men older than 50. The usual treatment is surgical removal, followed by radiation and/or chemotherapy.

2.In boys with **acute leukemia**, the leukemia cells can sometimes form a tumor in the testicle. Along with chemotherapy to treat the leukemia, this might require treatment with radiation or surgery to remove the testicle.

3.Cancers of the prostate, lung, skin (melanoma), kidney, and other organs also can spread to the testicles. The prognosis for these cancers tends to be poor because these cancers have usually spread widely to other organs as well.

Treatment depends on the specific type of cancer.

Clinical Features

1.testicular lump: patient may not seek advice for several months after first noticing that he has lump. A sensation of heaviness occurs when the testis is 2 or 3 times its normal size, but only minority experience pain.

2.The testis is enlarged, smooth, firm and heavy.

3.Secondary hydrocele.

4.the epididymis becomes more difficult to feel when it is flattened or incorporated in the growth.

5.Secondary retroperitoneal deposits may be palpable, especially just above umbilicus on the ipsilateral side.

6.An enlarged supraclavicular L.N is the presenting sign.

7.Occasionally the predominant symptoms are those of metastasis:

A. Intra-abdominal disease may cause abdominal or lumbar pain. There may be hepatic enlargement.

B. Lung metastases: usually silent but they can cause chest pain, dyspnoea, and hemoptysis in the later stages. Pulmonary metastasis occurs especially when the primary tumour is teratoma.

8.Atypical cases may simulate epididymo-orchitis, there may even be urinary infection.

9. Rarely patient presents with severe pain and acute enlargement of the testis because of hemorrhage into the neoplasm.

10. Between 1 and 5% of cases have gynecomastia(mainly teratoma).

Diagnosis of Testicular Cancer

The diagnosis of testicular cancer is based on:

1. **Clinical examination** of the testis and general examination to rule out enlarged nodes or abdominal masses.

2. **Ultrasound of the testis** to confirm testicular mass and always in a young man with a retroperitoneal mass or elevated tumour serum markers and without a palpable scrotal mass.

3. **Serum tumour markers**: (AFP, HCG and LDH).

-Some seminomas can increase blood levels of a protein called human chorionic gonadotropin (HCG).

-Embryonal carcinoma can increase blood levels of alphafetoprotein (AFP), as well as HCG.

-**Yolk sac tumour**: almost always increases blood levels of AFP.

-**Choriocarcinoma**: increases blood levels of HCG.

-**Pure teratomas** do not increase AFP or HCG levels. More often, **teratomas** are seen as parts of mixed germ cell tumors.

4. **Assessment of retroperitoneal and mediastinal nodes and viscera (Abdominopelvic CT scan and thoracic CT scan/X-ray Thorax)**

5. **MRI** is helpful only when the above are inconclusive or in patients with an allergy to contrast agents. Other examinations such as brain or spinal CT, bone scan should be performed if metastases are suspected.

6. **Inguinal exploration and orchiectomy** with en bloc removal of testis, tunica albuginea, and spermatic cord.

TNM Staging

pT	Primary tumour¹
pTX	Primary tumour cannot be assessed (see note 1)
pT0	No evidence of primary tumour (e.g. histological scar in testis)
pTis	Intratubular germ cell neoplasia (testicular intraepithelial neoplasia)
pT1	Tumour limited to testis and epididymis without vascular/lymphatic invasion: tumour may invade tunica albuginea but not tunica vaginalis
pT2	Tumour limited to testis and epididymis with vascular/lymphatic invasion, or tumour extending through tunica albuginea with involvement of tunica vaginalis
pT3	Tumour invades spermatic cord with or without vascular/lymphatic invasion
pT4	Tumour invades scrotum with or without vascular/lymphatic invasion
N	Regional lymph nodes clinical
NX	Regional lymph nodes cannot be assessed
N0	No regional lymph node metastasis
N1	Metastasis with a lymph node mass 2 cm or less in greatest dimension or multiple lymph nodes, none more than 2 cm in greatest dimension
N2	Metastasis with a lymph node mass more than 2 cm but not more than 5 cm in greatest dimension, or multiple lymph nodes, any one mass more than 2 cm but not more than 5 cm in greatest dimension
N3	Metastasis with a lymph node mass more than 5 cm in greatest dimension
pN	Pathological
pNX	Regional lymph nodes cannot be assessed
pN0	No regional lymph node metastasis
pN1	Metastasis with a lymph node mass 2 cm or less in greatest dimension and 5 or fewer positive nodes, none more than 2 cm in greatest dimension
pN2	Metastasis with a lymph node mass more than 2 cm but not more than 5 cm in greatest dimension; or more than 5 nodes positive, none more than 5 cm; or evidence of extranodal extension of tumour
pN3	Metastasis with a lymph node mass more than 5 cm in greatest dimension
M	Distant metastasis
MX	Distant metastasis cannot be assessed
M0	No distant metastasis
M1	Distant metastasis
M1a	Non-regional lymph node(s) or lung
M1b	Other sites
S	Serum tumour markers
Sx	Serum marker studies not available or not performed
S0	Serum marker study levels within normal limits

	LDH (U/l)	hCG (mIU/mL)	AFP (ng/mL)
S1	< 1.5 x N and	< 5,000 and	< 1,000
S2	1.5-10 x N or	5,000-50,000 or	1,000-10,000
S3	> 10 x N or	> 50,000 or	> 10,000

Another staging

Stage 1: Testis lesion only- no spread.

Stage 2: Nodes below diaphragm only.

Stage 3: Nodes above diaphragm.

Stage 4: Pulmonary or hepatic metastases.

The lymphatic drainage of the testis is to the para-aortic L.N near the origin of gonadal vessels. Lymphatics from the medial side of the testis may run with the artery to the vas and drain into a node at bifurcation of the common iliac artery. The contralateral para-aortic L.N are sometimes involved by tumour spread, but inguinal L.N are affected only if the scrotal skin is involved.

Treatment by Staging and Histological Diagnosis(after orchidectomy)

1.Seminomas: Are radiosensitive and excellent results have been obtained by irradiating stage I and II tumours. More recently, the tumour has been shown to be highly sensitive to Cisplatin, which is already used for patients with metastatic disease.

2.Teratomas: Are less sensitive to radiation.

A. Stage I can be managed by monitoring the levels of serum markers and by repeated CT.

B. Stage 2-4 are managed by chemotherapy. Cisplatin, methotrexate, bleomycin and vincristine have been used in combination with great success.

3. Retroperitoneal L.N dissection is sometimes needed when retroperitoneal masses remain after chemotherapy.

Testicular Tumours in Children

These are usually anaplastic teratomas. They occur before the age of 3 years and are often rapidly fatal.

Tumours of Epididymis: They are extremely rare

1. Benign: Mesothelioma
2. Malignant: Sarcoma
3. Secondary carcinoma

Murtadha Al-Musafer

Prof. of Urology

Urology Consultant

Basrah College of Medicine

3/2017