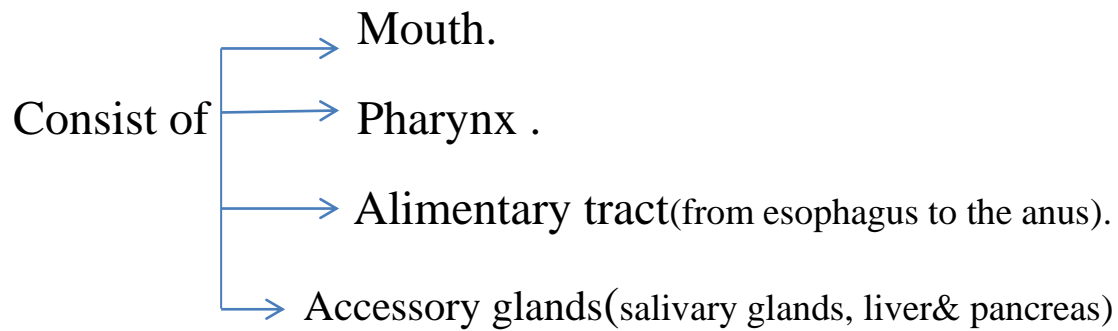
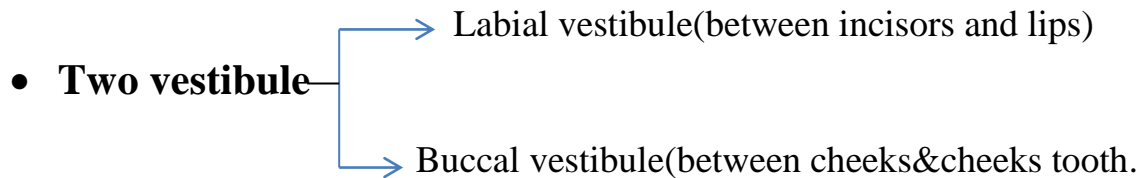


Digestive system



❖ Oral cavity(mouth):-divided in to

- Oral cavity proper
- Vestibule



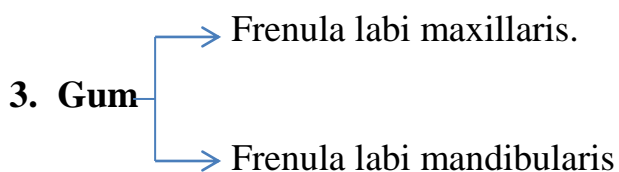
The contents of oral cavity:-

1. Lips

- Upper lips.
- Lower lips.

- The upper lips in cow modified into naso labial plate.
- In small ruminants (sheep&goat) the upper lips divided into philtrum

2. Cheeks(lateral walls)



- ❖ In ruminants (the upper incisors modified into dental pad).

Digestive system

4. Teeth.
5. Hard palate and soft palate(Roof) .

❖ Hard palate consist of:-

- Median palatine raphe.
- Transverse palatine ridges.
- Incisive papillae.

❖ Soft palate consist of:-

- Glossopalatine arch.
- Palatopharyngeal arch.

6.Tongue (floor) :-

Consist of :-

- Apex
 - Body
 - Root
 - Frenulum linguae .
 - Sublingual caruncle.
 - Sublingual recesses.
- ❖ In the root of tongue elevation called(torus linguae) in large ruminants, sheep& goat.
- ❖ In the root of tongue also found fossa called torus fossa more clear in large ruminants than sheep &goat.

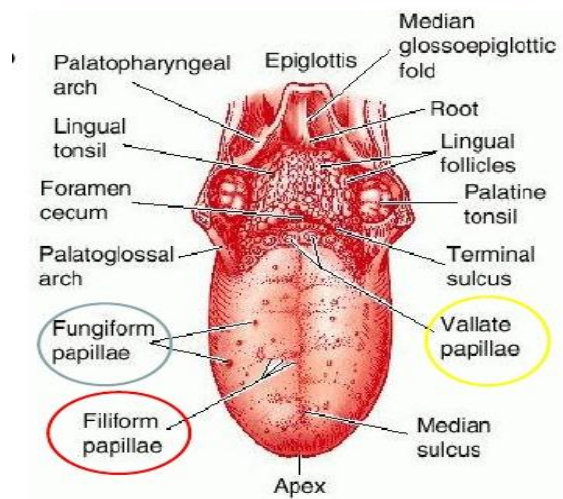
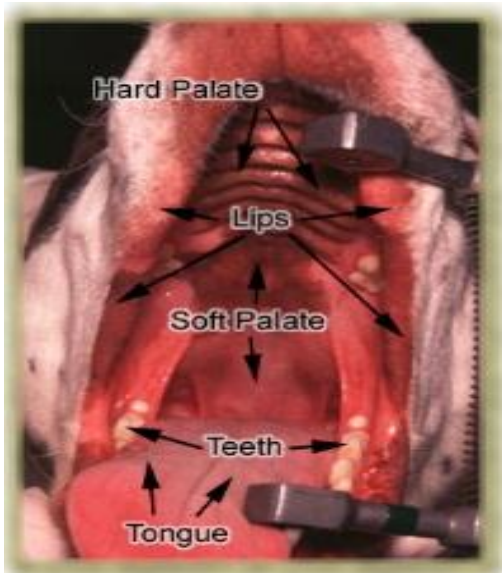
The papillae of tongue:-

1. Filiform papillae.
2. Fungiform papillae.
3. Conical papillae.
4. Vallate papillae.
5. Lenticular papillae.
6. foliate papillae.

Digestive system

The muscles of tongue:-

- Intrinsic muscles.
- Extrinsic muscles :-
 1. genio glosses muscle.
 2. Stylo glosses muscle.
 3. Hyo glosses muscle.



Bovine Tongue

