

Objective : At the end of this lecture you should be able to :

1. Identify the extent of the face.
2. Enlist the layers of the face and recognize their importance
3. Recognize the groups of the muscles of facial expression its origin ,insertion and function
4. Test the muscle of facial expression clinically
5. Discuss some clinical notes regarding the face

Extends from lower border of mandible to the hair line (forehead is common for face and scalp) and laterally to the ear auricle

Layers Of the Face

1.SKIN

The face has elastic and vascular skin. The skin of the face has large number of sweat and sebaceous glands. The sebaceous glands keep the face greasy by their secretion and sweat glands help modulate the body temperature

***Applied Anatomy** :Face is also the common site for acne as a result of presence of large number of sebaceous glands in this region.

2. SUPERFICIAL FASIA

It includes muscles of facial expression, vessels and nerves and varying amount of fat. The fat is absent in the eyelids but is well grown in cheeks creating buccal pad of fat, which gives rounded contour to cheeks.

3. DEEP FASCIA

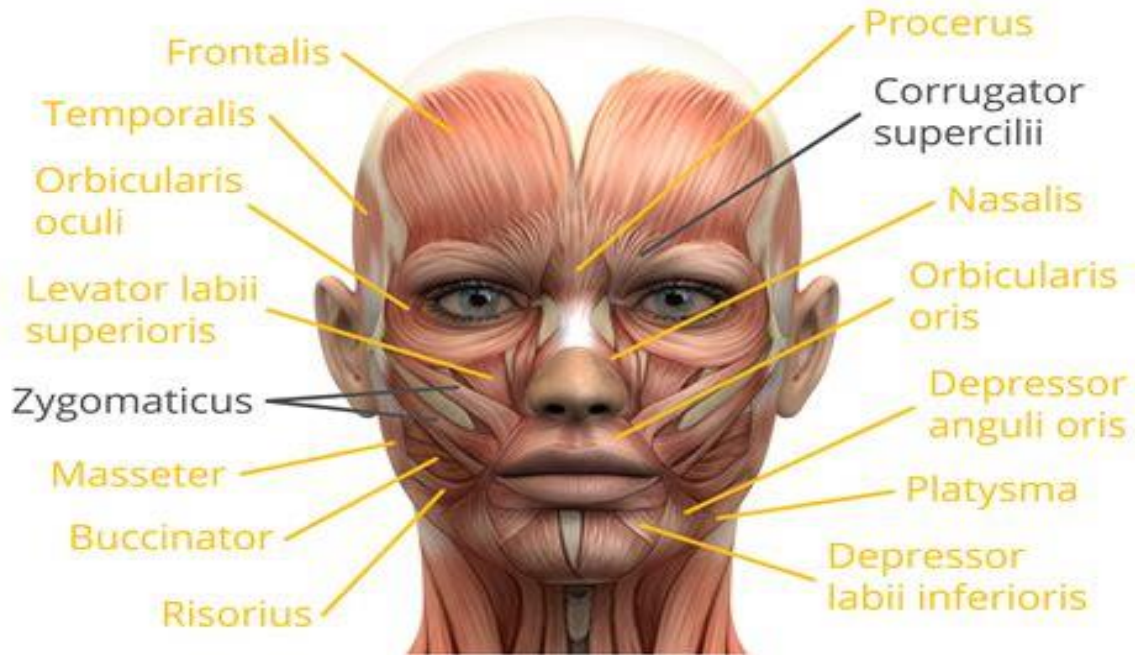
The deep fascia is absent in the region of face with the exception of over the **parotid gland and masseter muscle** that are covered by parotidomasseteric fascia. The absence of deep fascia in the face is important for the facial expression.

The majority of them originate from bones of the skull and are added into the skin.

MUSCLES OF FACIAL EXPRESSION:

- ✓ Embeds in the superficial fascia of the face.
- ✓ Originates from bones of the skull and are added into the skin.
- ✓ Brings about various types of facial expressions, thus the name muscles of facial expression, the activities of many are indicated by their names.
- ✓ These muscles are classified into :

- 1.Head group
2. Orbital group
- 3.Nasal group
- 4.Oral group
- 5.Neck group



1. Head Group

Frontals Muscle

The frontalis muscle originates at the anterior of the galea aponeurotica, which is near the top of the forehead.

Then extends down the forehead and attaches/ends at the eyebrows and upper nose.

.It elevates the eyebrows and creates transverse wrinkles on the brow as an expression of surprise, dread or fright.

Orbital Group

1.Orbicularis Oculi

It includes 3 parts:

- Orbital part: It shuts the eye closely to guard the eye from extreme light and dust particles. Palpebral part: . It closes the eyelids softly as in sleep or in blinking.
- Lacrimal part: . It dilates the lacrimal sac by using traction on the lacrimal fascia, thereby helping in the drainage of lacrimal fluid.

Applied Anatomy: The paralysis of orbicularis oculi ends in drooping of the lower eyelid (ectropion) causing spilling of tear on the cheek (epiphora).

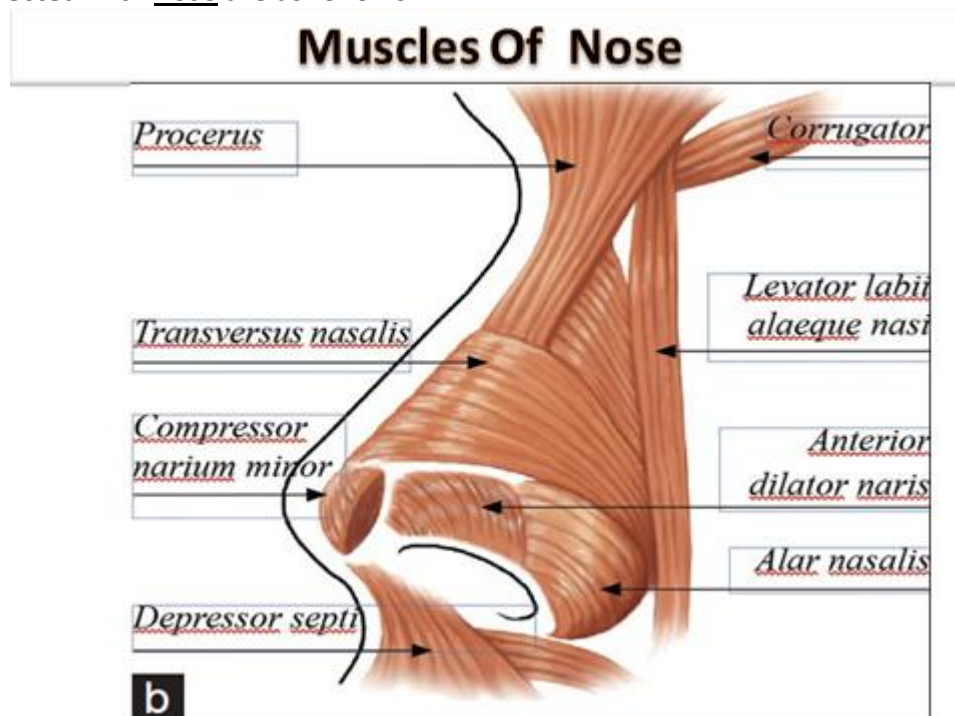
2. Corrugator Supercilii

The corrugator supercilii muscle is a small, pyramidal-shaped muscle that is located above each eye, in the area of the eyebrow. It originates from the inner part of the superciliary arch, muscle then attaches to deep skin tissue located in the middle of the arch of each orbital bone.

It brings the eyebrow medially and downwards creating vertical wrinkles on the brow as in frowning, an expression of irritation.

Nasal Group

The muscles connected with nose are as follows:



1. Procerus:

The procerus muscle is the pyramid-shaped muscle extending from the lower part of the nasal bone to the middle area in the forehead between the eyebrows, where it is attached to the frontalis muscle. Its location allows it to pull the skin between the eyebrows down. It creates transverse wrinkles around the bridge (root) of the nose as in frowning.

2. Nasalis:

The muscle originates in the maxilla inserts into the nasal bone. The nasalis muscle is comprised of two parts:

*transverse part termed compressor naris: It compresses the nasal aperture

*alar part named dilator naris: It dilates the anterior nasal apertures as in deep inspiration.

The buccal branch of the facial nerve serves the nasalis muscle and many other muscles within the face.

3. Depressor Septi nasi:

The muscle emerges from incisive fossa. It inserts into both the nasal septum and the ala .

It fixes the nasal septum to enable dilatation of anterior nasal aperture by dilator naris as in anger.

Oral Group

The muscles in the oral group move the lips and cheek. They include the orbicularis oris and buccinator muscles, and a lower and upper group of muscles.

1. Orbicularis oris:

A ring-like muscle that encompasses the lips. From the mandible and maxilla, the orbicularis oris muscle inserts into the tissues of the upper and lower lips. The orbicularis oris muscle produces several movements of the mouth, which includes closing and puckering of the lips. The closing and puckering of the lips can allow you to perform several different actions.

Applied Anatomy: The paralysis of 1-half of orbicularis oris prevents the correct close of lips on this side. Thus the address is slurred and the spit escapes between the lips at the angle of the mouth (dribbling of spit from the angle of the mouth).

2. Buccinator (Bugler's muscle/trumpeter's muscle) is muscle of the cheek

Origin: The maxilla, the mandible, and deep to the mandible, along the pterygomandibular raphe.

Insertion: Attaches to the orbicularis oris and the fibers from the deep portion of the lips

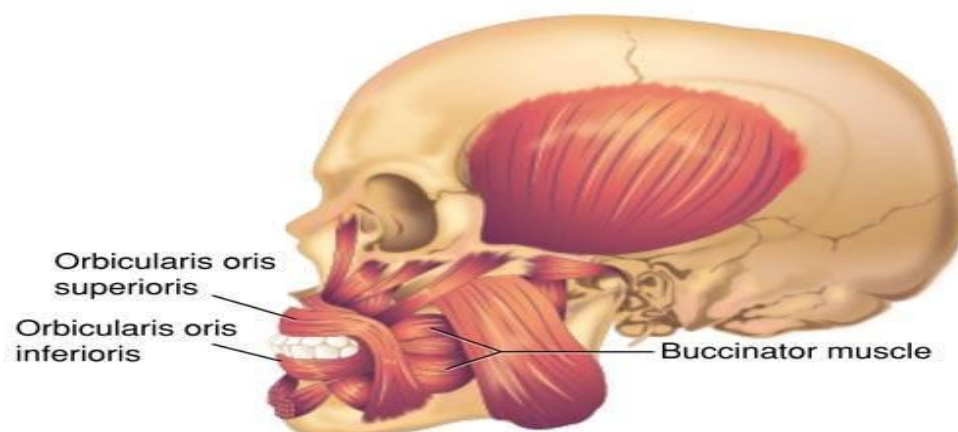
Actions: Are

- *Compresses the cheek
- *Flattens cheek against gums and teeth
- *Puffing of mouth
- *Forceful expulsion of air from the cheeks (whistling)

Innervation: Buccal branch of the facial nerve (cranial nerve VII)

Blood Supply: Branches from the facial artery

Applied Anatomy: If the buccinator muscle is paralyzed, as it happens in facial palsy, the food collects in the vestibule of mouth during mastication and the man can not blow his cheek .



*Upper Group Of Oral Muscles

1. Levator labii superioris alaeque nasi .

The muscle is attached to the upper frontal process of the **maxilla** and inserts into the skin of the lateral part of the nostril and upper lip.

It elevates the upper lip and helps to dilate the nostril.

2. Levator labii superioris .

It is shaped like a broad, flat sheet that starts next to the nose and extends to the zygomatic bone, which is more commonly referred to as the cheekbone. It elevates the upper lip (dilator to upper lip).

3. Levator anguli oris .

There are two levator anguli oris muscles, each located symmetrically on either side of the mouth. When the two work in unison, the corners of the mouth move upwards. It is located deep to levator labii superioris. It lifts the angle of the mouth. It helps the face form one of the most universally known expressions the smile.

4. Zygomaticus minor :

It is a slender band of muscle on each side of the face arising from the zygomatic bone. The muscle attaches at the top of the cheek below each eye and extends diagonally down and to the outside of each end of the upper lip. It elevates the upper lip (dilator to upper lip).

The zygomatic and buccal branches of the facial nerve innervate the zygomaticus minor. The facial artery supplies blood to the muscle.

5. Zygomaticus major

The zygomaticus major muscle starts at the cheekbone and extends to the corner of the mouth. This muscle causes the corners of a person's mouth to rise when they smile. It pulls the angle of the mouth upward and laterally(dilator to upper lip). Short zygomaticus major muscle cause dimples to form.

6. Risorius :

The risorius begins around the parotid gland, a salivary gland in the back of the jaw, and wraps around the platysma muscle, then continues to the skin of the corner of the mouth, where it ends. The facial nerve is directly connected to the risorius muscle. It retracts the angle of the mouth softly as in grinning or insincere smile.

*Lower Group Of Oral Muscles

7. Depressor labii inferioris:

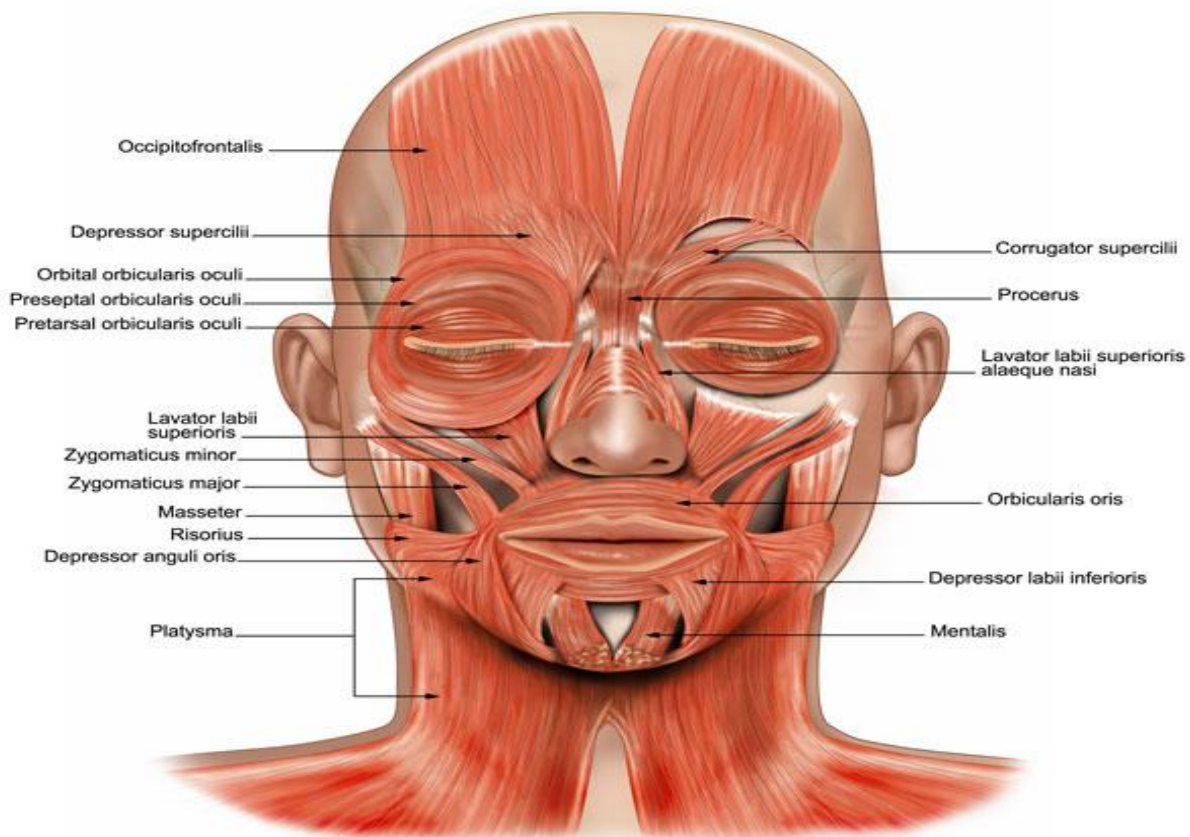
Originating from oblique line of the mandible and inserts into the skin of the lower lip and blends with the orbicularis oris muscle. It pulls the lower lip downwards and somewhat laterally.

8. Depressor anguli oris :

The depressor anguli oris muscle is attached to the mandible. It ends at the orbicularis oris. It is attached at the edge of the lips. The depressor anguli oris muscle is associated with frowning, as it works to pull down the edges of the lips. It pulls the angle of the mouth downwards and laterally.

9. Mentalis:

A muscle that arises from the mandible just inferior to the incisor teeth and helps position the lip during drinking from a cup. It raises and protrudes the lower lip as it wrinkles the skin on the chin. It puckers the chin and protrudes the lower lip.



Neck Group :

Platysma:

It is expansive in size, with a broad width that spans the clavicle, and the side of the neck. It originates from the upper portions of the pectoral, or chest, and the deltoid, or shoulder. The muscle narrows in size once it reaches the neck, extending upwards to the mandible. It depresses the mandible and pulls the angle of the mouth downwards as in horror or surprise.

Clinical testing of the muscles of facial expression

1. Frontalis, by requesting the patient to look upwards without moving his head and after that look for horizontal wrinkles on the brow.
2. Corrugator supercillii, by requesting the patient to frown and after that look for vertical wrinkles between both eyebrows.
3. Orbicularis oculi, by requesting the patient to shut the eyes closely.
4. Orbicularis oris, by requesting the patient to whistle.
5. Dilators of the mouth, by requesting the patient to reveal his teeth.
6. Buccinator, by requesting the patient to smoke his mouth and after that blow out the air powerfully.
7. Zygomaticus major, by requesting the patient to laugh.
8. Risorius, by requesting the patient to smile softly.

Answer the following questions

1. Which of the following muscles can produce transverse wrinkles on the forehead?

- a. orbicularis oculii
- b. corrugator supercillii
- c. frontalis
- d. procerus

2. Regarding the muscles of facial expression, one statement is true

- a. levator labii superioris can elevate the lower lip
- b. Risorius can dilate the lip
- c. frontalis can produce transverse wrinkle over the root of the nose
- d. corrugator supercillii brings the medial ends of the eye brows away

3. There is no deep fascia in the region of the face. Explain (why?)