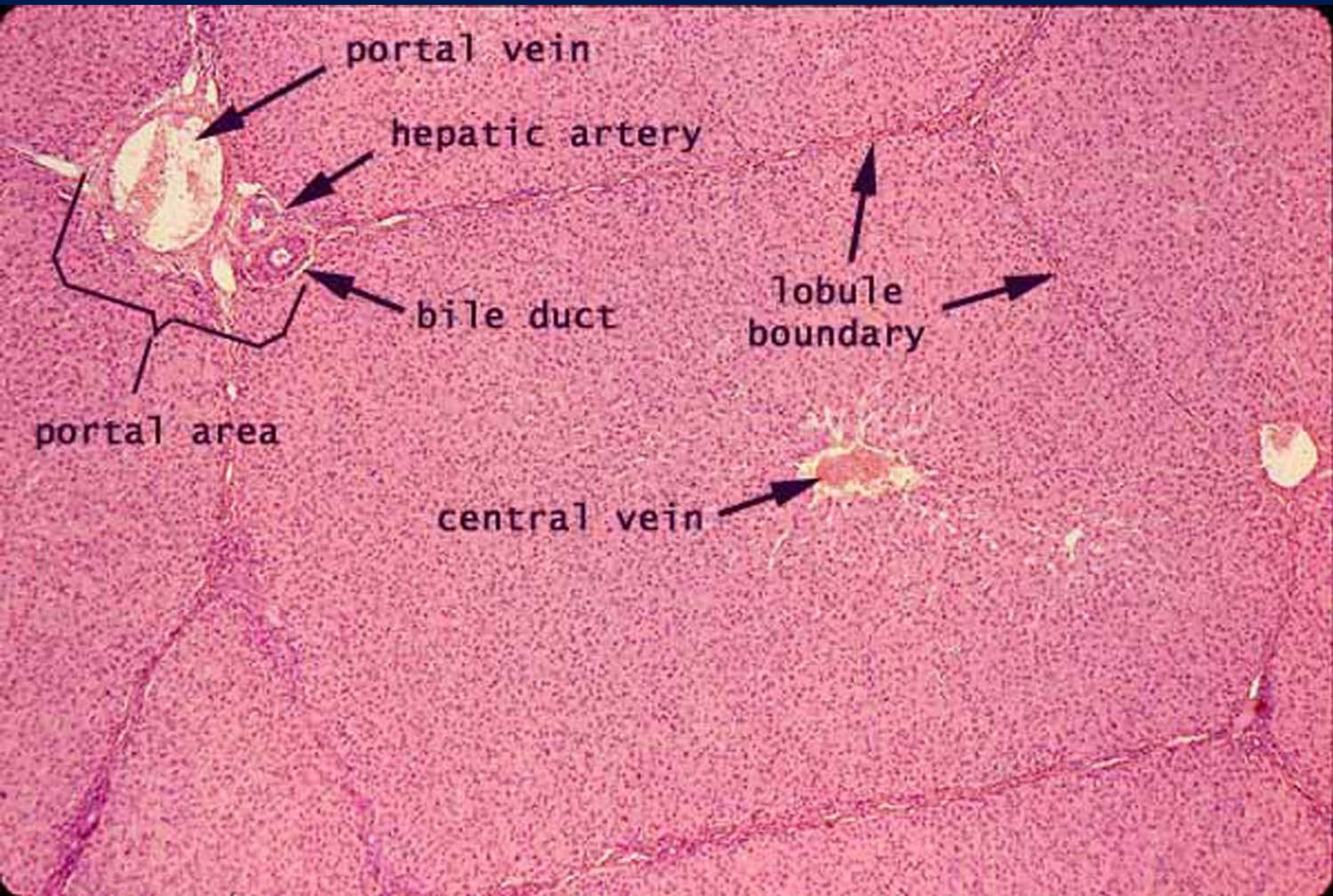


Accessory glands

Liver

- covered by Glasson's capsule.
- trabeculae separated the lobe into lobule each lobule contain:
 - central vein ,hepatocytes(cuboidal and binucleated).
- sinusoids lining by endothelial and Kupffer cells.
 - at the angle of lobule there is (portal area).contain
 - 1-hepatic artery.
 - 2-portal vein.
 - 3-bile duct .

Liver Lobule and Portal Tract



Liver Portal Tract

- Portal vein (PV)
- Hepatic artery (A)
- Bile Duct (B)
- Lymphatic vessels (L)

S = sinusoids

