


FETAL MALPOSITION & MALPRESENTATION

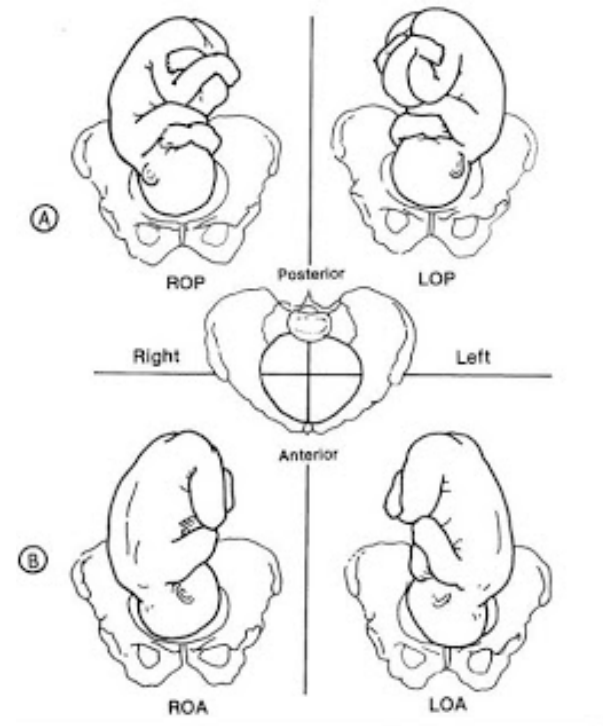
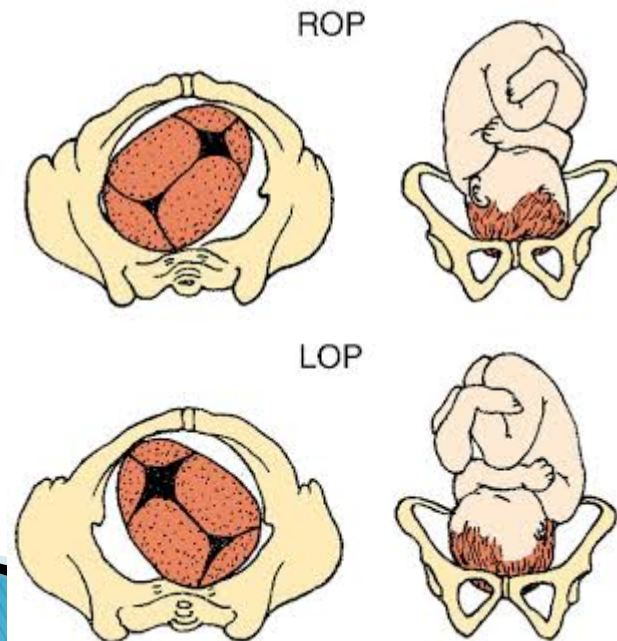
Dr. Ali F. Al-Assadi
Prof. of Obst. & Gyne.
Basra Medical College

Definitions


- ▶ **Malposition**: Is one where the fetal head is presenting but not as a well flexed vertex with the occiput in the anterior quadrant.
 - ▶ **Malperresentation**: Includes conditions where the fetal head is not the presenting part.
- 

Occipito-posterior position

- ▶ 20 % of cephalic presentation during early labour.
- ▶ The sagittal suture is in one of the oblique diameter usually the right.



Aetiology

- ▶ The head can enter the brim in the direct OP position when the fetus is small & the pelvis is capacious or when a large fetus engages in a pelvis which has a brim which is longer anteroposteriorly than transversely.
 - ▶ Anterior sited placenta.
 - ▶ Deflexed head → brigma meet the pelvic floor resistance & rotate anteriorly.
- 

Diagnosis

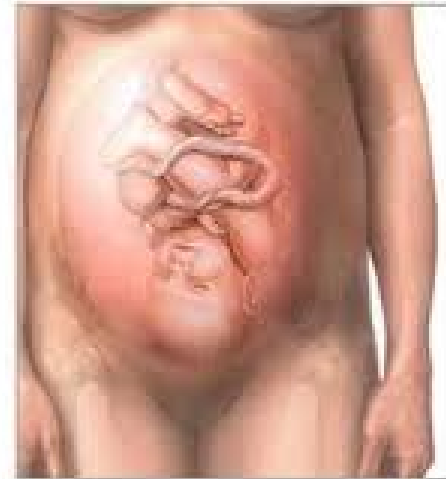A- During pregnancy: Is of no importance except it might be a cause of non-engagement.

B- During labour:

1- suspicion made if the patient develops early rupture of membranes with poorly engaged head.

2- **Abdominal examination:** slight the lower abdomen, the limbs are the back is difficult to be felt with hear the fetal heart.

Fetus in posterior presentation

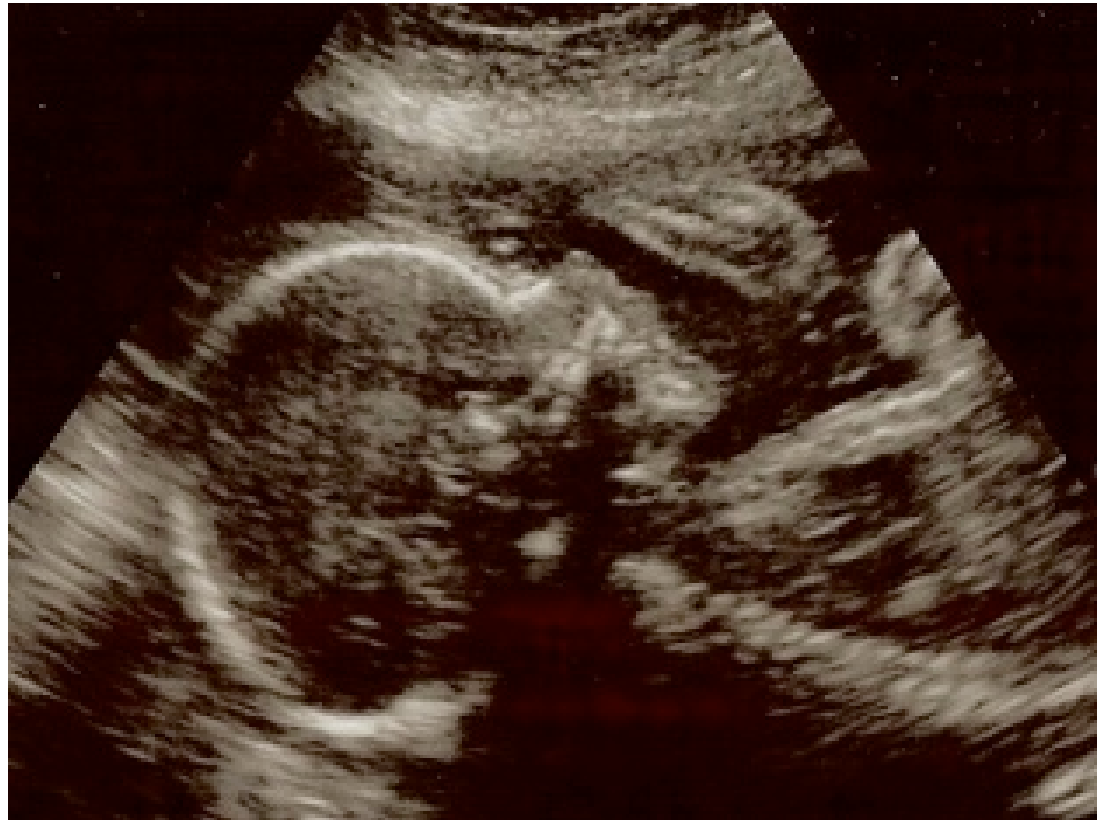


Diagnosis

3- **Vaginal exam.:** high presenting part early in labour, easy to feel the ant. Fontanel behind the pubis. Late in labour there may be moulding with caput succedaneum over the presenting part.

Diagnosis (continue)


4- Ultrasound in labour may be helpful.



The course of labour

- ▶ 70 % :spontaneous rotation to OA.
- ▶ 10 % : short rotation to direct OP position & delivery as face to pubis.
- ▶ 20 % persist as R or L OP where assisted rotation will be required.
- ▶ Prolong 1st & 2nd stages is a feature.


Management of the 1st stage

- ▶ Managed as in a normal case; nothing can be done to correct the abnormality.
 - ▶ Partogram.
 - ▶ Epidural anesthesia.
 - ▶ Augmentation should be done if there is no satisfactory cervical dilatation & if this doesn't result in better progress in few hours CS is performed which is also indicated for fetal distress.
- 

Management of the 2nd stage

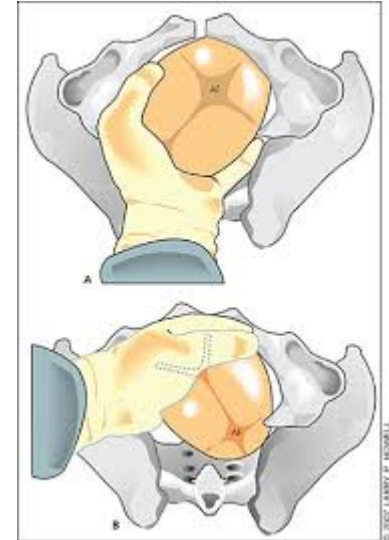
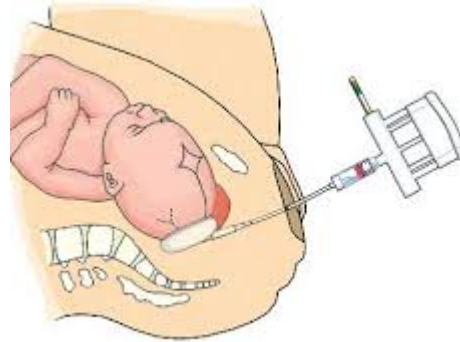
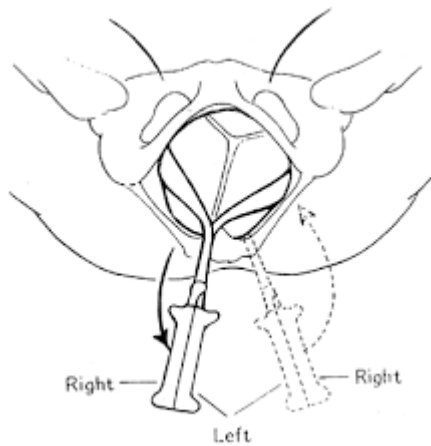
- ▶ Diagnosed by VE.
- ▶ The degree of flexion & position of the head are determined by palpation of the fontanel,
- ▶ Continue deflexion, large caput & marked moulding suggest that spontaneous rotation may not occur.
- ▶ With good uterine contractions & good maternal expulsive forces, spontaneous rotation & normal delivery takes place. In 10 % delivery in face to pubis & this carries a greater risk of perineal tear.

Management of the 2nd stage

- ▶ Interference is indicated in cases of:
 - 1– Failure of descent.
 - 2– Fetal distress.
 - 3– Maternal distress.
- 

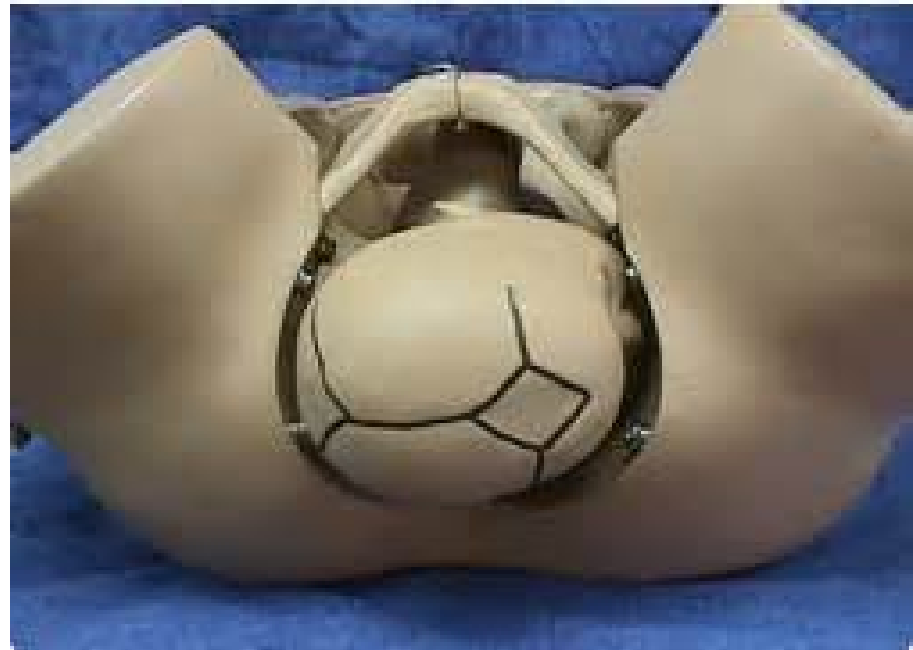Assisted delivery

- 1– Manual rotation & forceps delivery. Requires GA or epidural.
- 2–Kjellands' forceps.(Rotation & traction)
- 3– Vacuum extractor.




Deep Transverse arrest of the fetal head

- ▶ Is arrest in labour when the fetal head has descended to the level of the ischeal spines & the sagittal suture lies in the transverse diameter of the pelvis.



Diagnosis

- ▶ The condition is only diagnosed during the second stage of labour.
 - ▶ The occiput may have been obliquely posterior at the onset of labour & only partly rotated forward, or
 - ▶ It may have descended from an initial transverse position.
 - ▶ In android pelvis the head fails to descend to the pelvic floor, where rotation normally occur.
- 

Diagnosis (cont.)

- ▶ By vaginal exam during the second stage when progress of labour ceased, the head arrested at the level of the ischeal spines, with sagittal suture at the transverse diameter of the pelvis.

Management

1–Augment inefficient uterine contractions with oxytocin.

2–Rotation & traction as with OP.