

بِسْمِ اللَّهِ الرَّحْمَنِ الرَّحِيمِ

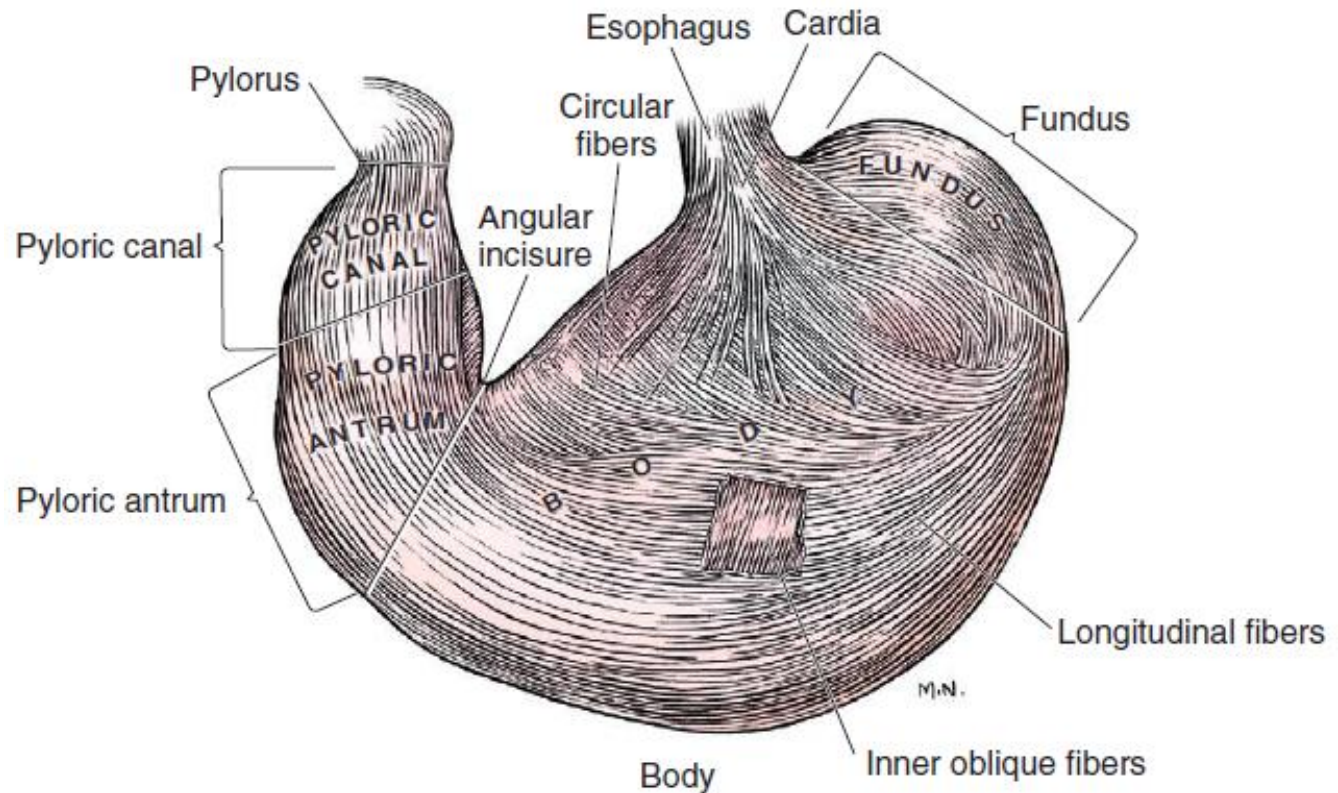


Surgery of Simple Stomach

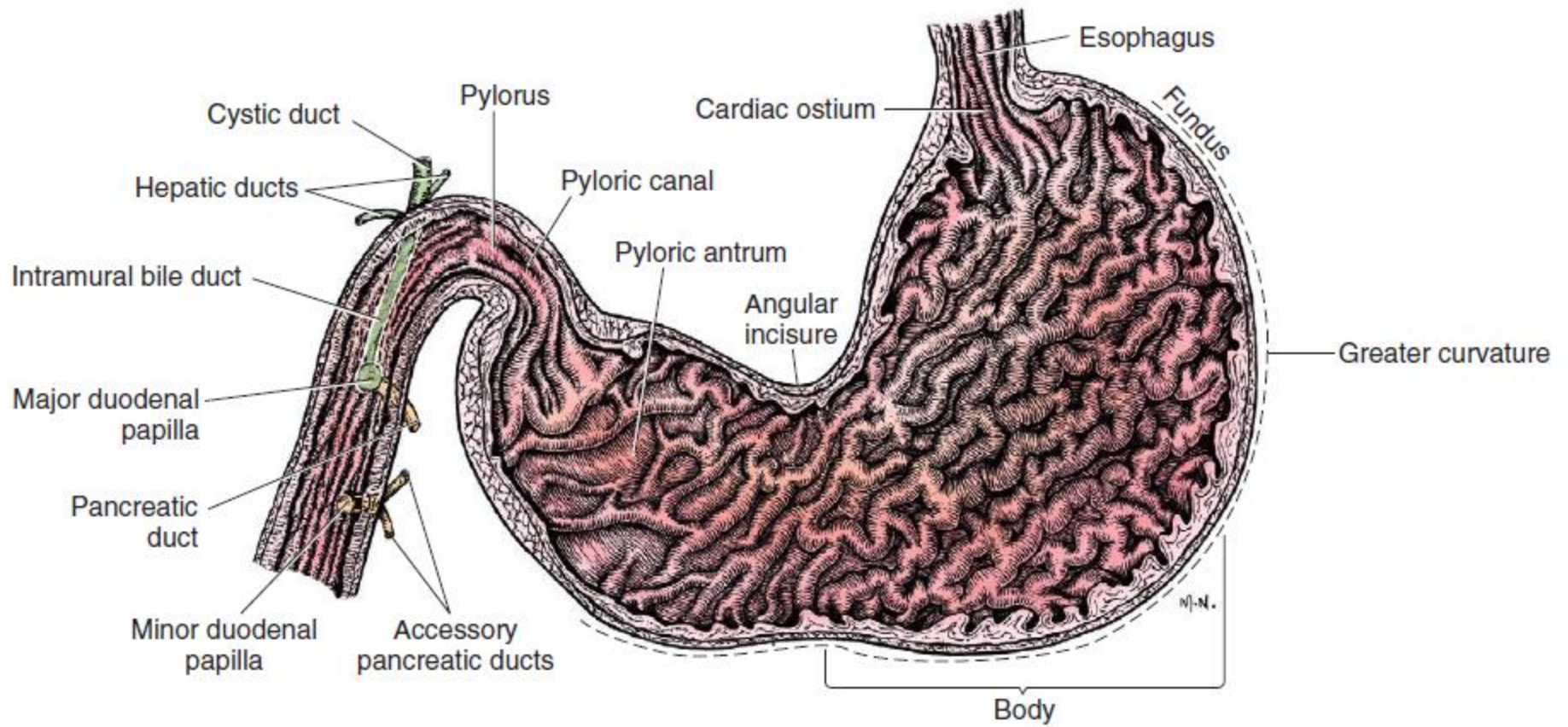
Dr. Rafid Majeed Naeem Alkhalifa

anatomy

- Grossly, the stomach is divided into
- the cardia,
- fundus,
- body,
- and pyloric



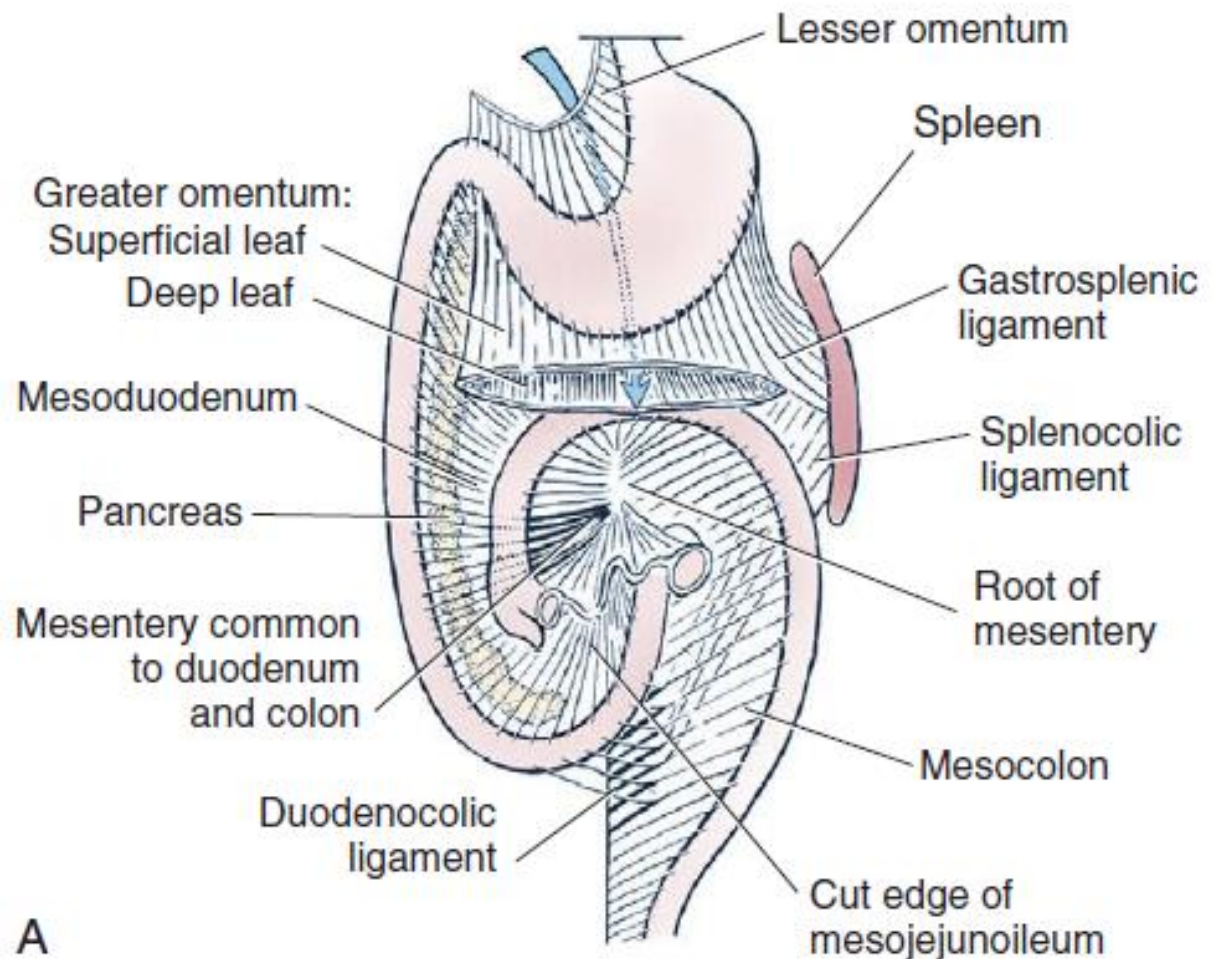
The pyloric portion of the stomach is divided into the thinner walled pyloric antrum and the area known as the pyloric sphincter, which is defined by the double muscle layer that surrounds it.



Omentum

The greater and lesser omentum are attached to the stomach at the greater and lesser curvatures, respectively. The greater omentum is divided into three portions known as:

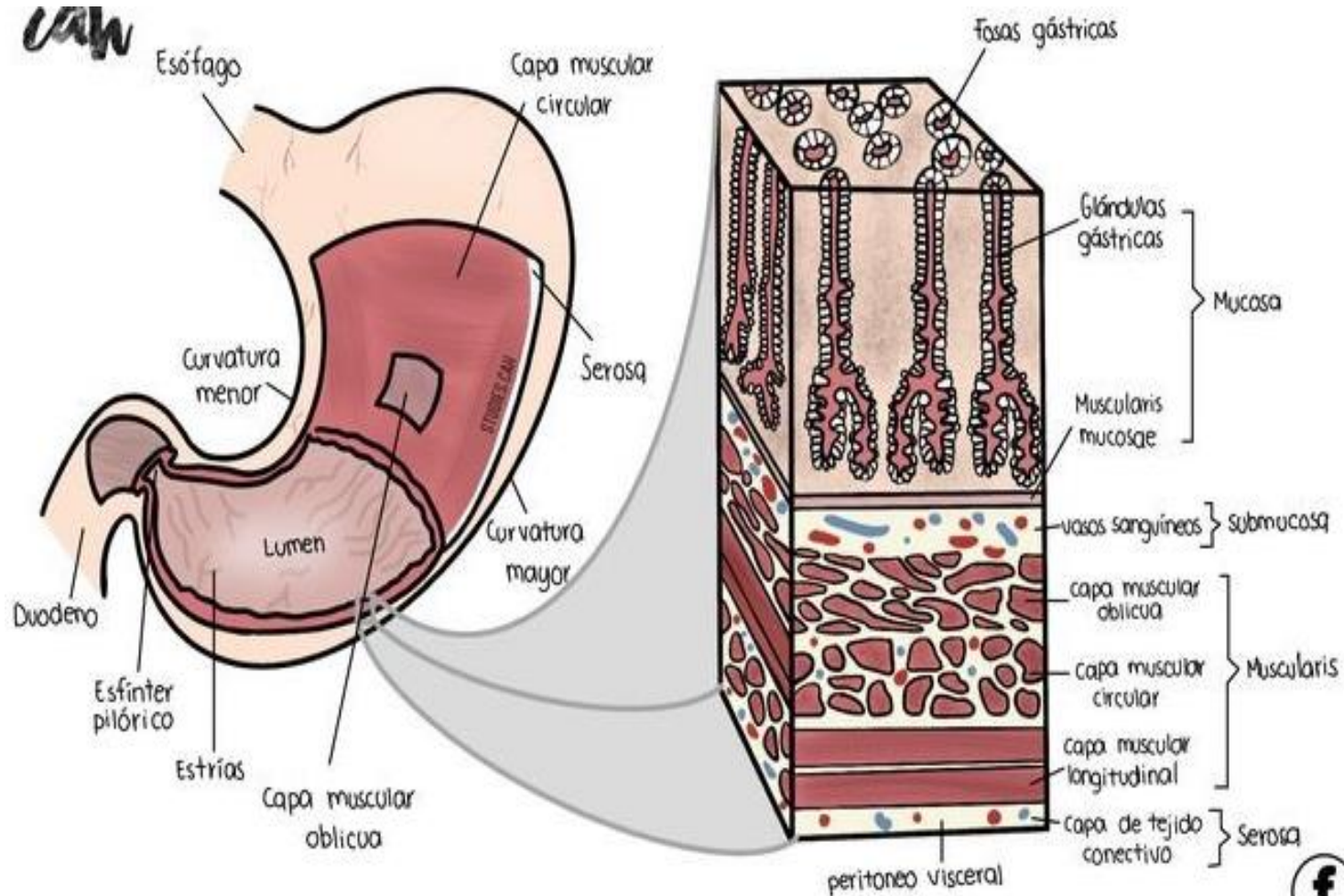
- the bursal,
- splenic, and
- veil portions



histology

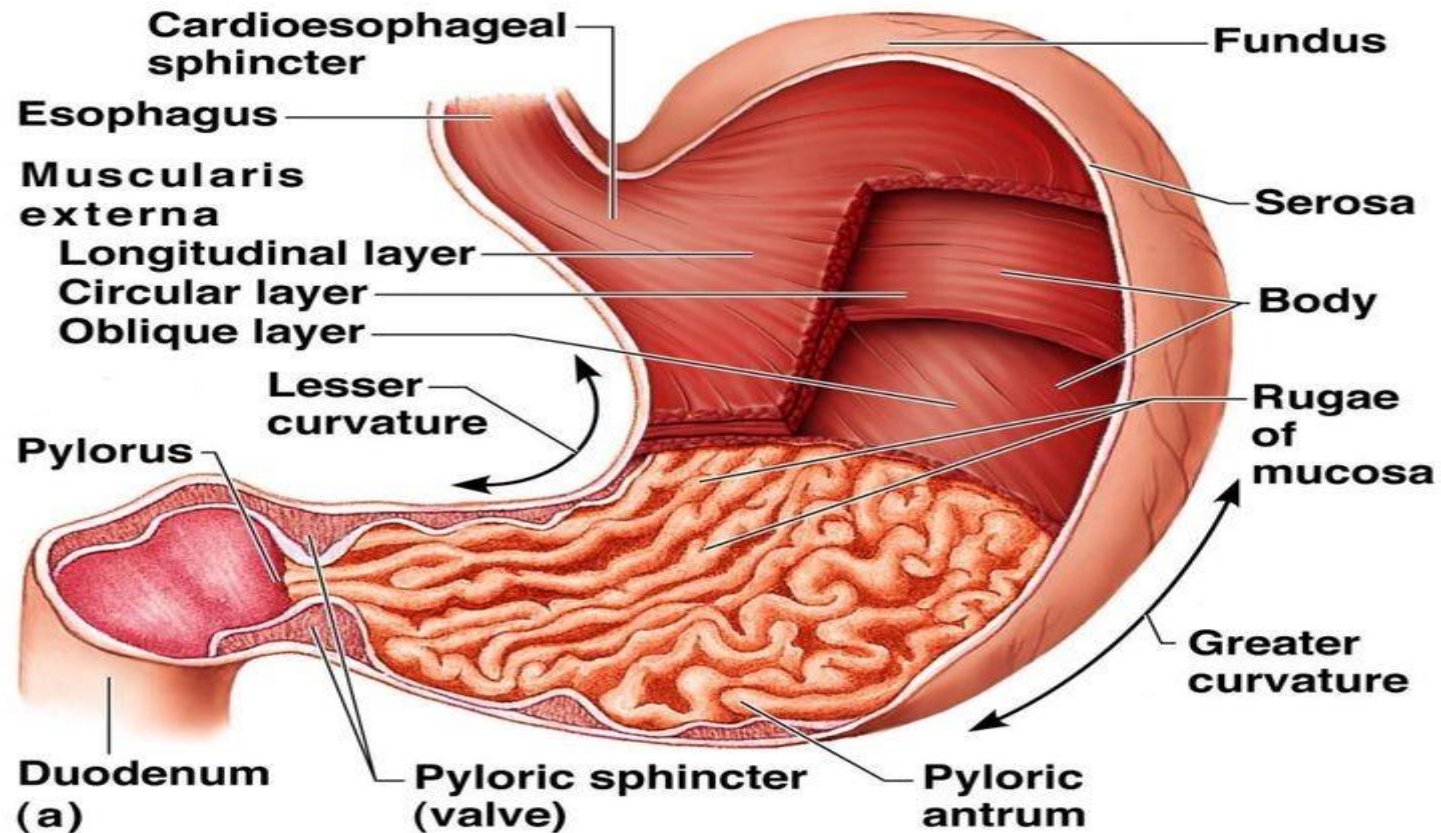
The stomach wall is composed of four distinct layers; from the external to the internal surface, they are

- the serosa,
- muscle,
- submucosa,
- and mucosa.

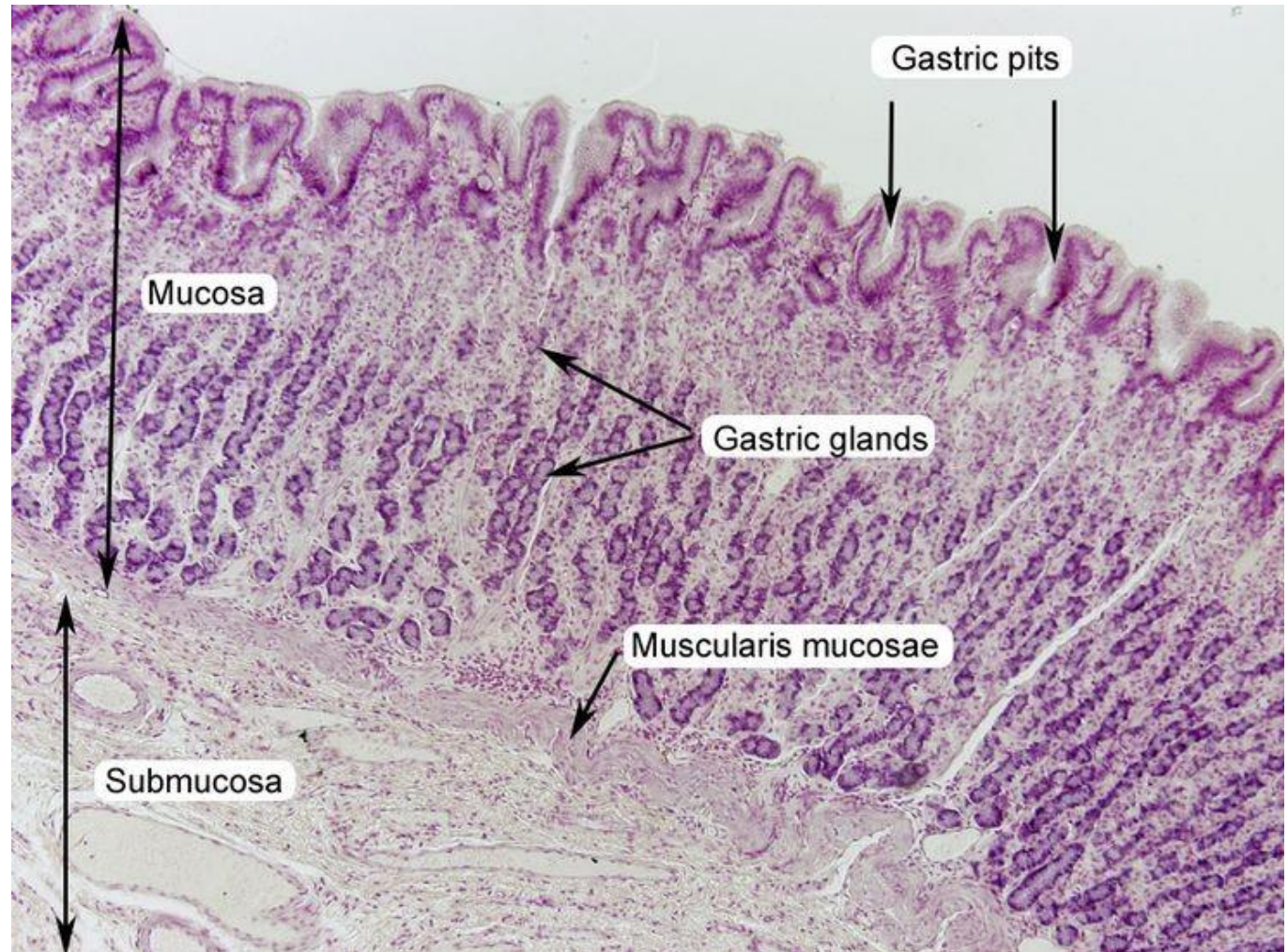


The muscular composition of the stomach is divided into three layers.:

- *The longitudinal layer.*
- *The inner circular layer.*
- *The oblique muscle fibers,*

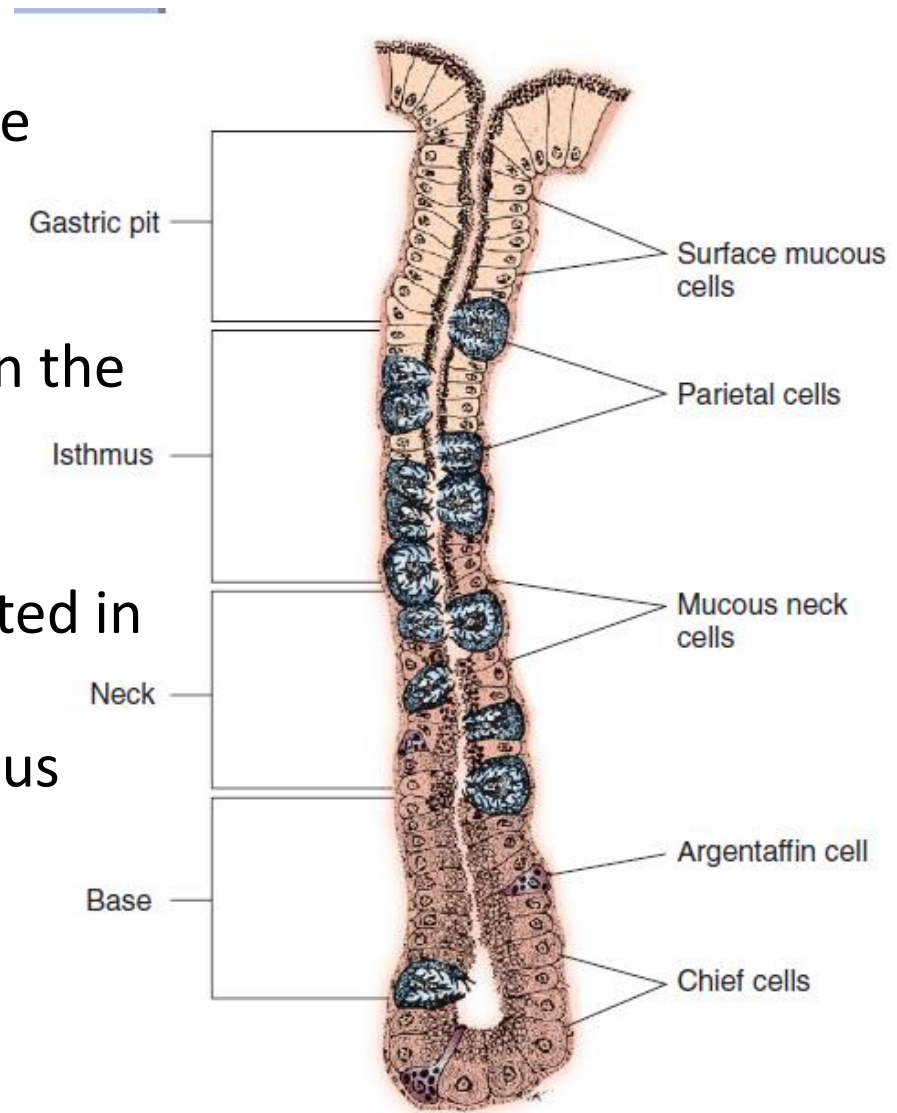


- The submucosa is composed of a thin elastic layer of areolar tissue and serves as the critical holding layer during surgical closure of gastric incisions.
- The mucosal layer is made up of columnar surface epithelium, a glandular lamina propria, and a lamina muscularis mucosa



Glands of the stomach include

- The cardiac glands are located primarily around the cardia but are also present in the antrum; they produce a serous secretion.
- The pyloric glands may be found in the pylorus and gastric body; they primarily produce mucus
- The gastric glands proper are located in the fundus and body and are composed of parietal, chief, mucous neck, and endocrine cells



Healing Characteristics

mucosa

- mucosa is protected by normal cytoprotective mechanisms from autodigestion by gastric acid and digestive enzymes.
- *When superficial epithelial injury occurs, it is repaired rapidly by epithelial migration without proliferation.*
- *Gastric mucosa erosions heal rapidly by epithelial regeneration*

Submucosa

- *Injury that extends into the submucosal layer is considered **an ulcer** and is associated with a **fibrotic repair process**.* Scar formation with fibrous protein synthesis occurs and predominates over wound contraction.
- If the depth and duration of gastric insult are minimized, the resultant scar is often resorbed. In long-term injury, a profound fibrotic response may result in permanent scar formation.

Healing Characteristics

- *Incisional healing differs from the previously described healing process because, although a full-thickness injury is created, it is of short duration.*
- *Standard phases of wound healing, including inflammation, debridement, repair, and maturation, occur in gastric healing.*
- *In contrast to other healing tissues in which **collagen is produced by only fibroblasts**, smooth muscle cells of the gastrointestinal tract contribute to collagen production during gastrointestinal wound healing.*
- *Healing in the stomach is enhanced by its extensive and وافر redundant blood supply*

Anesthetic Considerations

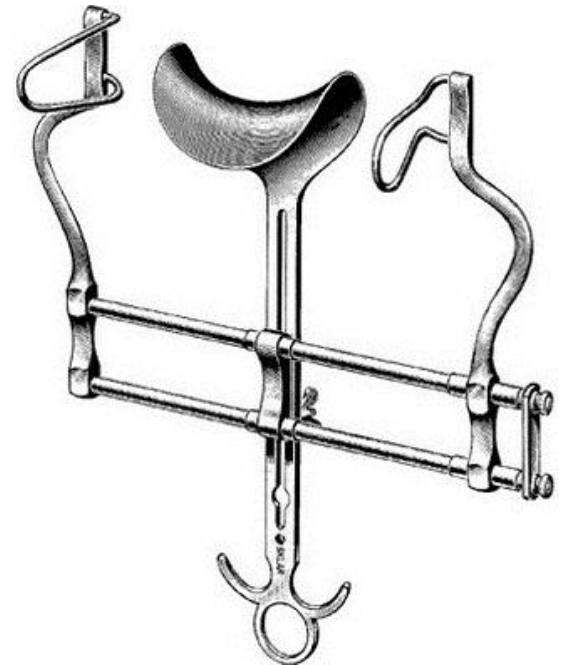
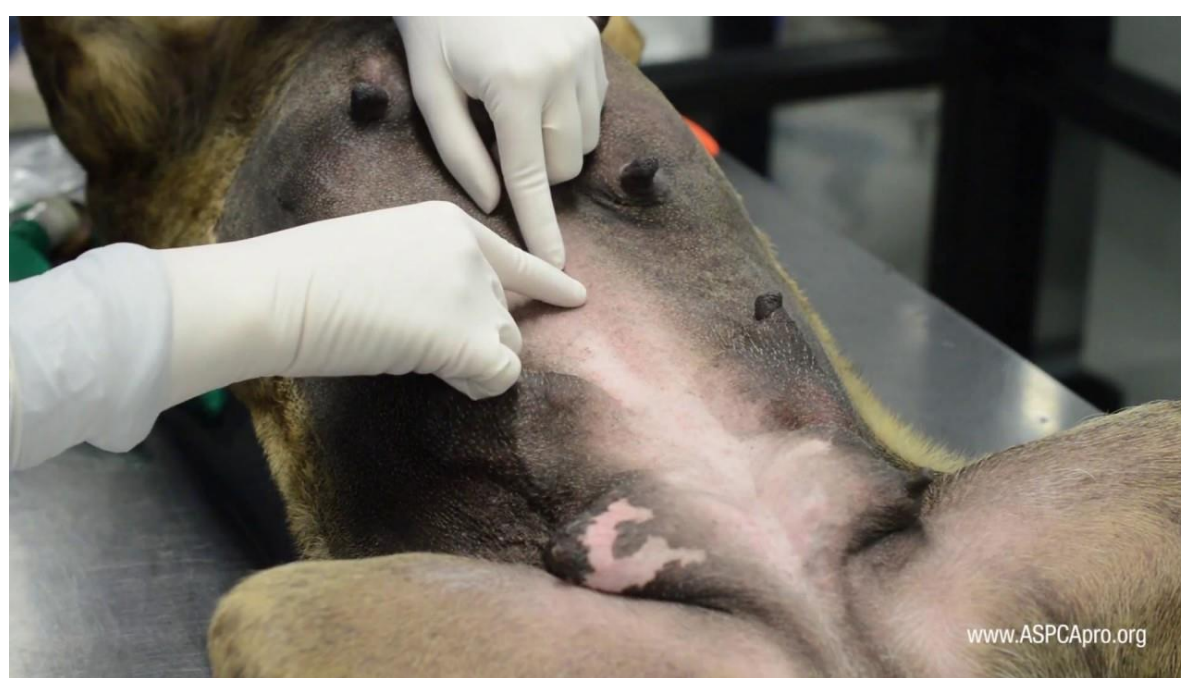
- Clinical signs frequently associated with gastric disorders include vomiting and regurgitation; as such, administration of anticholinergics such as *atropine* or *glycopyrrolate* should be considered in an effort to reduce gastric secretions.
- When gastric reflux into the esophagus is considered likely, preoperative administration of an *H₂ receptor blocker* such as *cimetidine*, *ranitidine*, or *famotidine* may be indicated to decrease gastric pH and minimize esophageal damage.
- When vomiting is a significant concern, rapid induction (e.g., *intravenous propofol*) and intubation (trachea tube) without delay are indicated to provide immediate airway protection.
- Mechanical ventilation may be required in cases in which the abdominal *incision* must be extended *through the diaphragm*.

Antimicrobials

- *Bacterial numbers in the stomach are significantly less than in the remainder of the gastrointestinal tract because of the acidic nature of stomach secretions.*
- *But for example, gastric perforation, obstructive disease with possible bacterial overgrowth, and gastric dilatation and volvulus, In other instances when the lumen of the stomach must be entered and the surgeon believes there is an increased risk of contamination, administration of prophylactic antibiotics should be considered*

Approach

- Gastric surgery of the small animal patient is most commonly performed through a ventral midline abdominal incision that extends from the xiphoid process of the sternum to a point caudal to the umbilicus and, in many instances, to the cranial extent of the pubis.
- visualization is maximized by the use of a Balfour retractor to retract the abdominal wall.

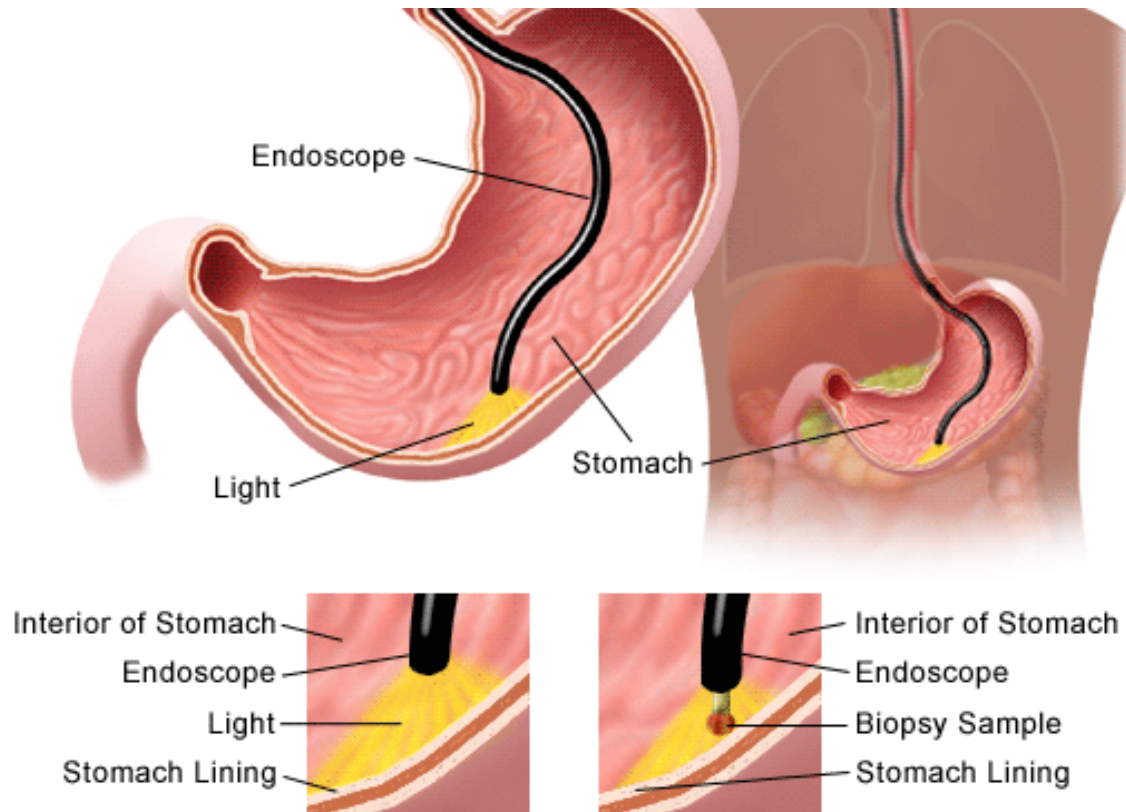


GENERAL SURGICAL TECHNIQUES

1. Gastric biopsy

It is indicated in the presence of gross disease of the stomach and when clinical signs are consistent with upper gastrointestinal disease.

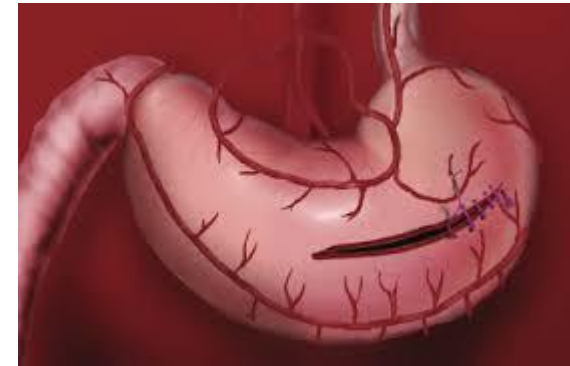when the disease is submucosal or scirrhus in nature, *endoscopic biopsy is inadequate because of the inability to obtain a full-thickness gastric wall sample*



GENERAL SURGICAL TECHNIQUES

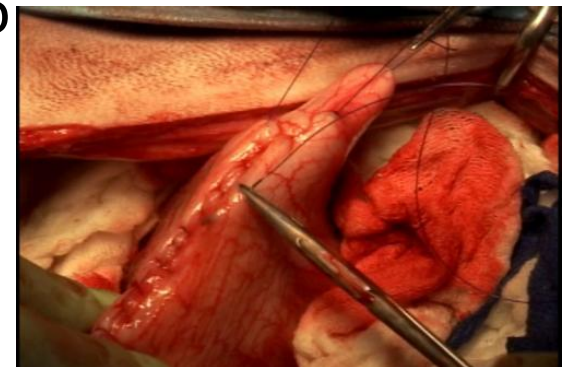
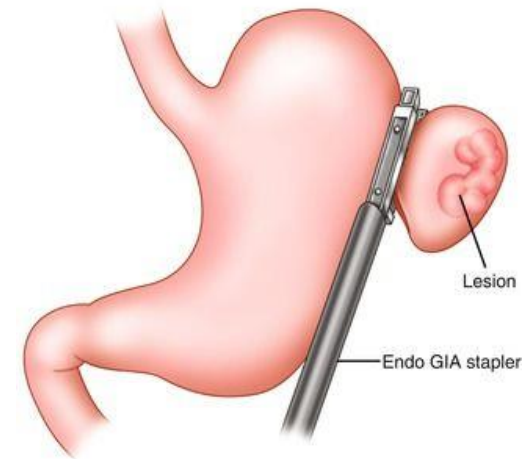
2. Gastrotomy

It is performed on the ventral surface of the stomach midway between its lesser and greater curvatures in the area with the least vascularity.



3. Partial Gastrectomy

- Partial gastrectomy is performed to remove necrotic stomach wall associated with gastric dilatation and volvulus or to resect a neoplasm.
- When the lumen diameter is not adequate to allow inverting closure, a simple continuous suture pattern is most appropriate.



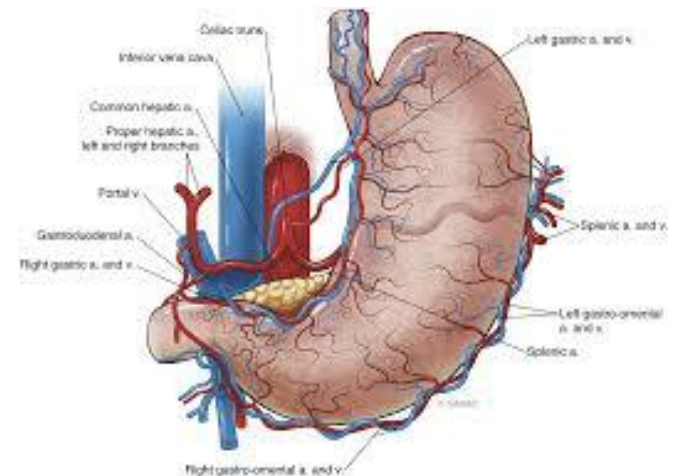
Determining Tissue Viability

Viability of gastric mucosa does not predict overall health of the gastric wall but viability is measured as follow:

- gastric wall thickness, as measured by palpation;
- serosal surface color;
- evidence of serosal capillary perfusion; and
- presence of peristalsis.

nonviable gastric wall include a wall that is thinner than normal or serosal surface color of grey-green to black. the seromuscular layer can be incised to evaluate arterial vascular supply

Other methods : fluorescein dye injection, scintigraphy, and laser Doppler flowmetry



Gastropexy

itis the creation of a permanent adhesion of the stomach to the adjacent body wall.

Gastropexy is most commonly performed for prevention of gastric dilatation and volvulus but is also used in the treatment of hiatal hernia.

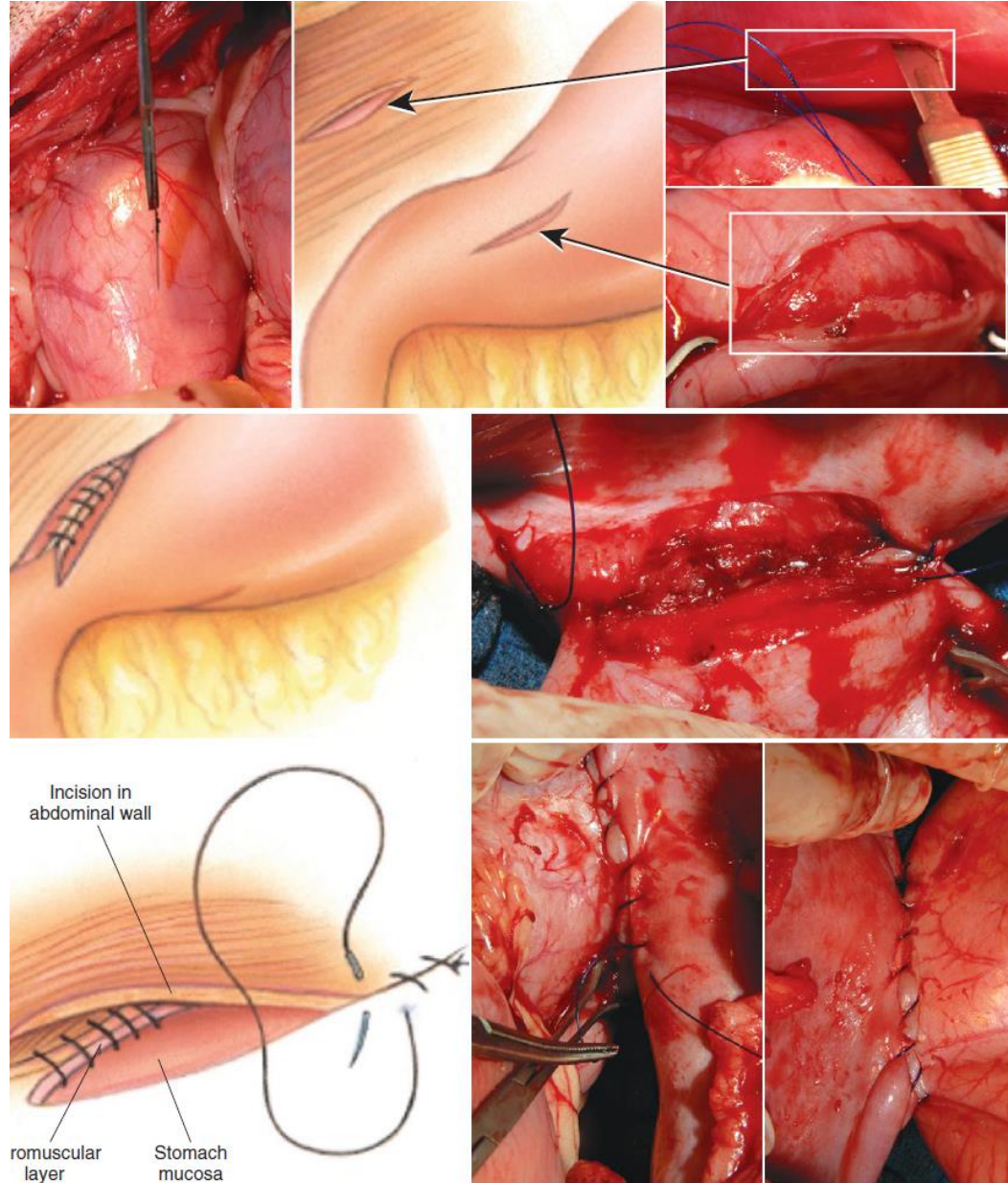
- Gastropexy for prevention of **gastric dilatation and volvulus** is performed between the pyloric antrum and the **right abdominal wall**.
-
- A variety of gastropexy techniques have been reported with varying degrees of success. Techniques include:
 1. incisional,
 2. beltloop,
 3. circumcostal,
 4. endoscopically assisted, and
 5. laparoscopic gastropexy;
 6. gastrocolopexy;
 7. incisional gastropexy through a grid approach; and
 8. incorporating gastropexy, in which the gastric wall is included in the linea alba closure.

Regardless of the type of gastropexy technique, the goal is to anchor the stomach in as normal an anatomic position as possible.

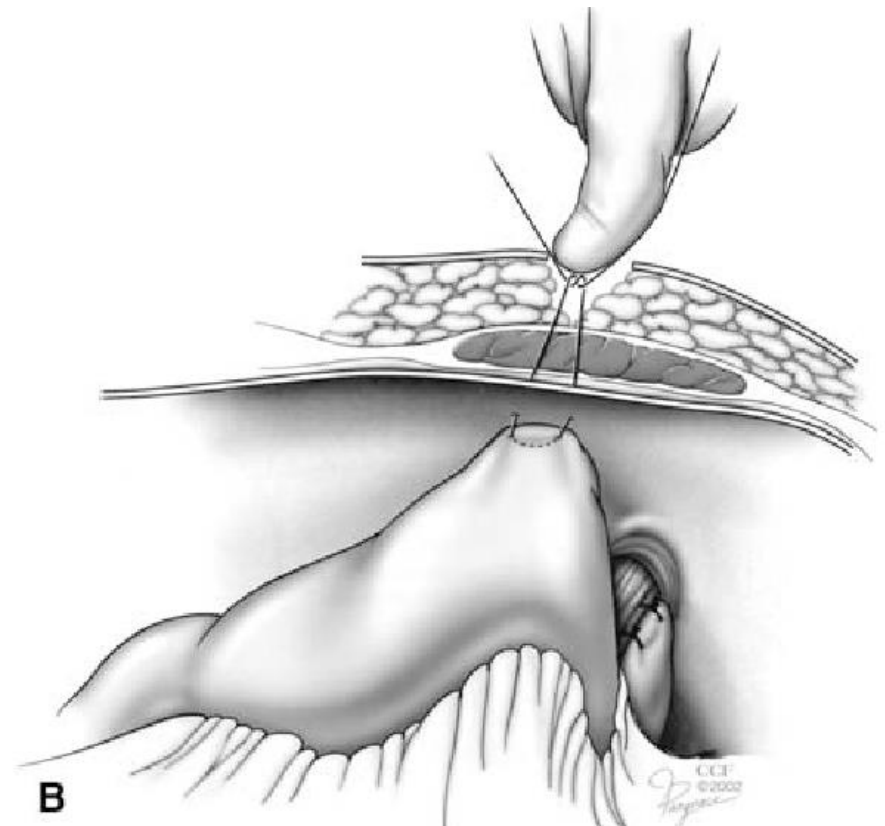
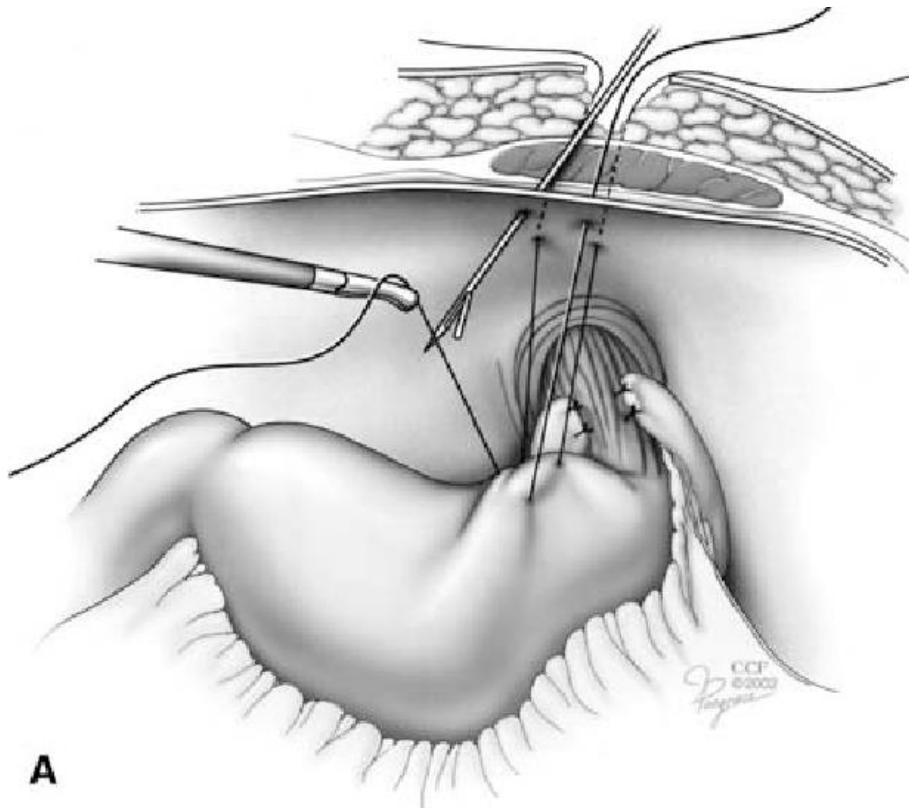
Incisional Gastropexy

creating a 4- to 5-cm seromuscular incision in the gastric antrum either parallel or perpendicular to the long axis of the stomach.

A second incision is made through the peritoneum and the transverse abdominis muscle on the lateral or ventrolateral right abdominal wall approximately 2 to 3 cm caudal to the last rib incisions are apposed using 2-0 monofilament absorbable suture in a simple continuous suture pattern



- The technique for incisional gastropexy for treatment of hiatal hernia is similar in all respects, except that it is performed on the left side of the abdomen. The incision through the seromuscular layer of the fundus corresponds with an incision through the peritoneum and transverse abdominis muscle on the left side of the abdominal wall caudal to the last rib
- Care should be taken when making this gastric incision because the gastric wall is not as thick in this area as in the antrum, and penetration of the gastric mucosa is undesirable..



2. *Belt-Loop Gastropexy*

- a **seromuscular flap** is elevated from **the pyloric antrum** and passed through a tunnel created between two parallel incisions in the abdominal wall.

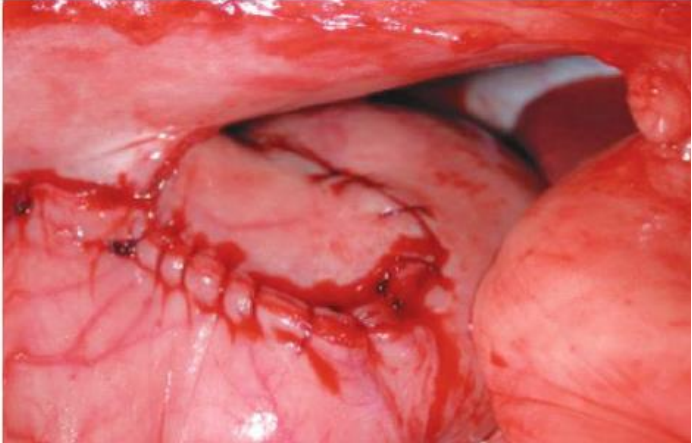
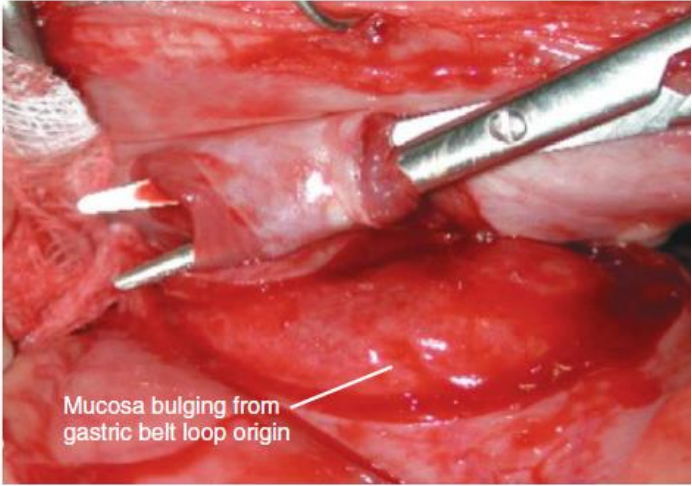
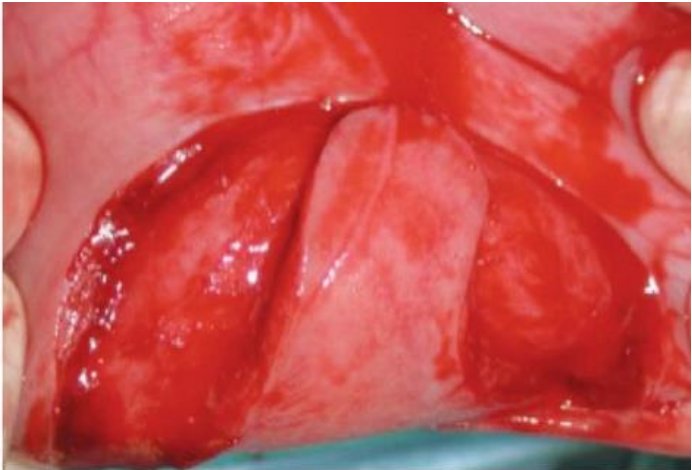
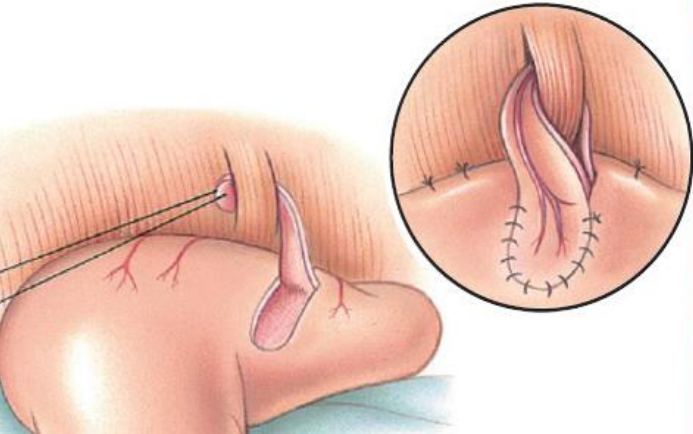
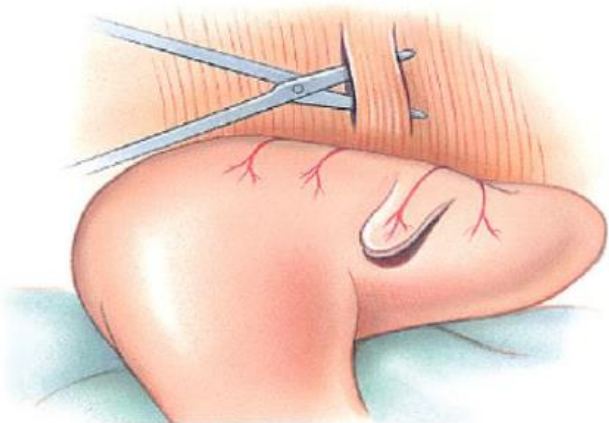
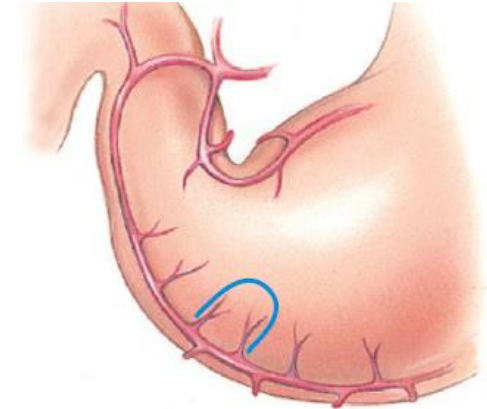
• ملاحظة الصورة توضح العملية

3. seromuscular gastric flap is based along **the greater curvature** of the stomach and **incorporates branches of the gastroepiploic artery in its origin**. The flap is created by making two parallel incisions approximately **4 cm long and 3 cm apart** and connecting these incisions at their most cranial aspect.

The resultant seromuscular flap is undermined from the mucosal layer below. Next, **two 5-cm-long** abdominal wall incisions that penetrate the peritoneum and transverse abdominis muscle are made approximately **3 cm apart**. Muscle between the two incisions is undermined, creating a tunnel through which the seromuscular gastric flap is passed.

- The gastric flap is passed through the tunnel by first bringing the stomach close to the body wall to decrease tension applied to the flap as it is passed and then using a stay suture placed in the free end of the flap to direct the flap through the tunnel. The flap is sutured back to the site from which it was elevated using a simple interrupted or continuous pattern of **2-0 or 3-0 absorbable monofilament**.

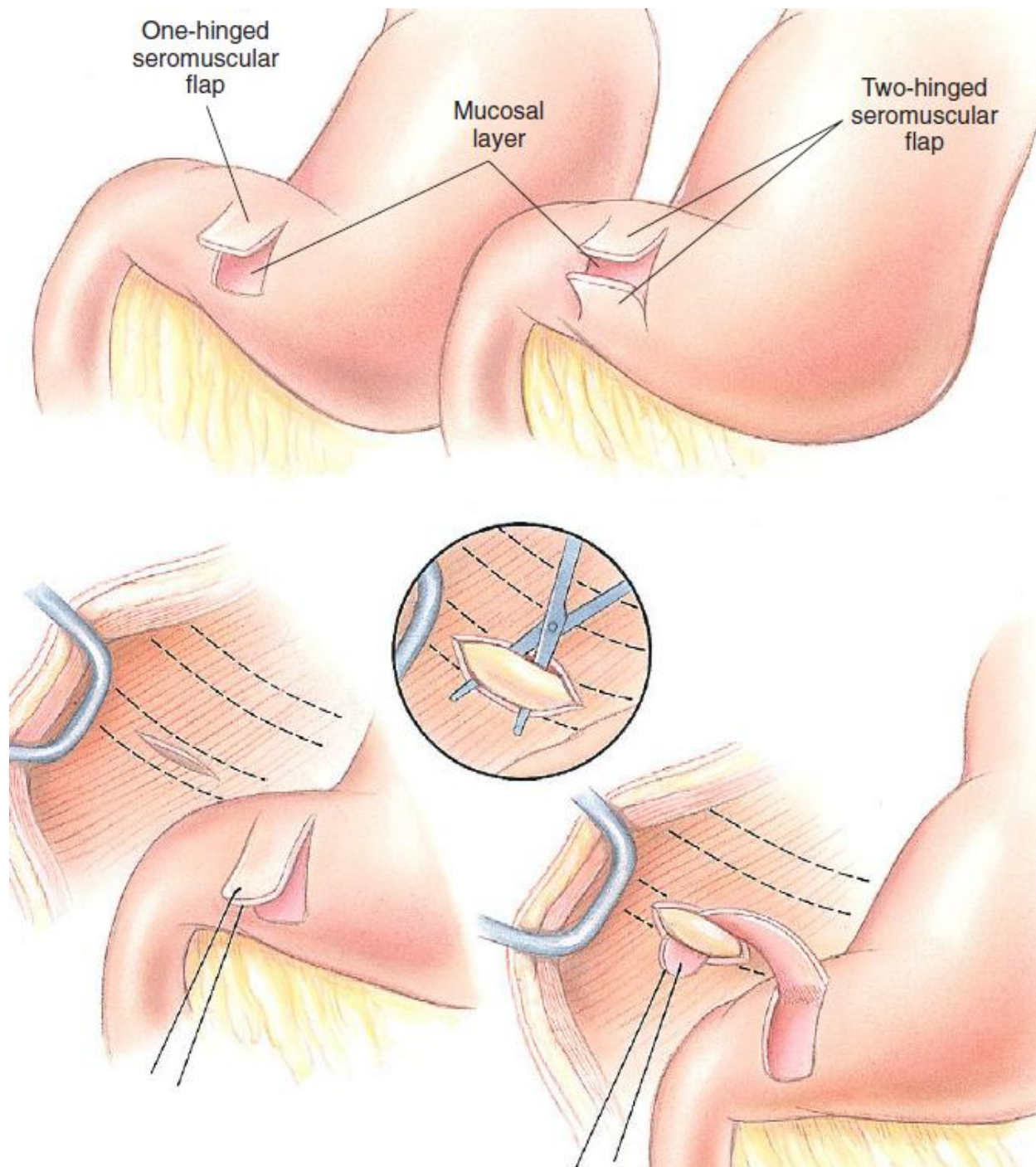
Belt-Loop Gastropexy

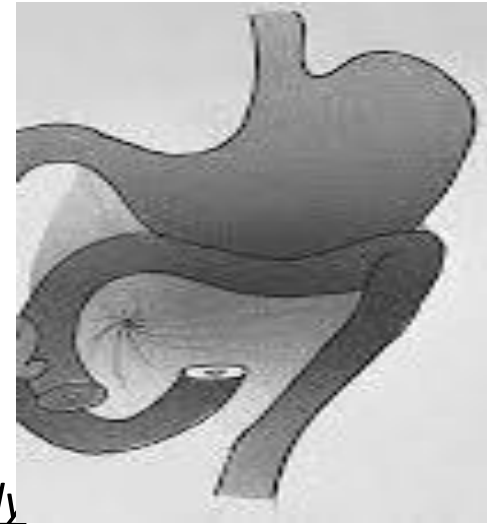

3. Circumcostal Gastropexy

- For treat gastric dilatation and volvulus
it is a Modifications of the original technique.
- A seromuscular flap is raised from the pyloric antrum similar to the belt-loop gastropexy technique.
- The seromuscular flap may be double or single hinged. When a single-hinged flap is used, it is **based from the lesser curvature** of the stomach and undermined below the level of the muscularis layer, taking care not to penetrate the gastric lumen. **A 5- to 6-cm** incision is made directly over **the eleventh or twelfth rib** at the level of the costochondral junction. A plane of blunt dissection is then established circumferentially in close association with the rib.
- The seromuscular gastric flap is then passed cranial to caudal through the tunnel surrounding the rib; stay sutures placed in the leading edge of the flap facilitate passage around the rib. The seromuscular flap is sutured back to its origin using 2-0 or 3-0 absorbable suture material.

Circumcostal Gastropexy





4. Gastrocolopexy

Creation of a suture line between the greater curvature of the stomach and the transverse colon has been described to prevent recurrence of gastric dilatation and volvulus.

5. Incorporating Gastropexy

An incorporating gastropexy is performed by including approximately 5 cm of gastric wall near the pyloric antrum with the cranial portion of the linea alba closure during apposition of a ventral midline abdominal incision.

6. Minimally Invasive Prophylactic Gastropexy Techniques Grid Approach. Prophylactic right-sided gastropexy may be achieved through a *minilaparotomy*.

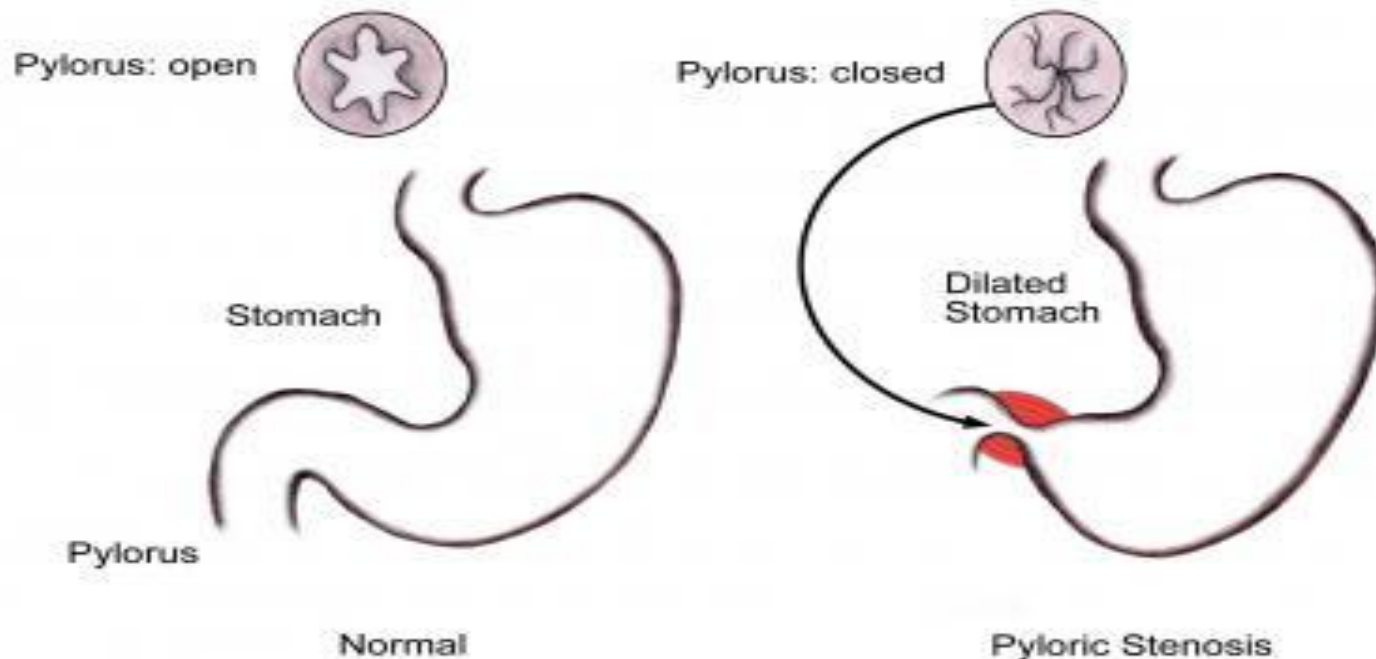
7. Laparoscopic Gastropexy.

Laparoscopic and laparoscopic assisted gastropexy have been reported for prevention of gastric dilatation and volvulus in dogs

Pyloromyotomy and Pyloroplasty

Pyloric surgical techniques are focused on removing outflow obstruction and normalizing gastric outflow (stenosis). Several techniques have been described, including

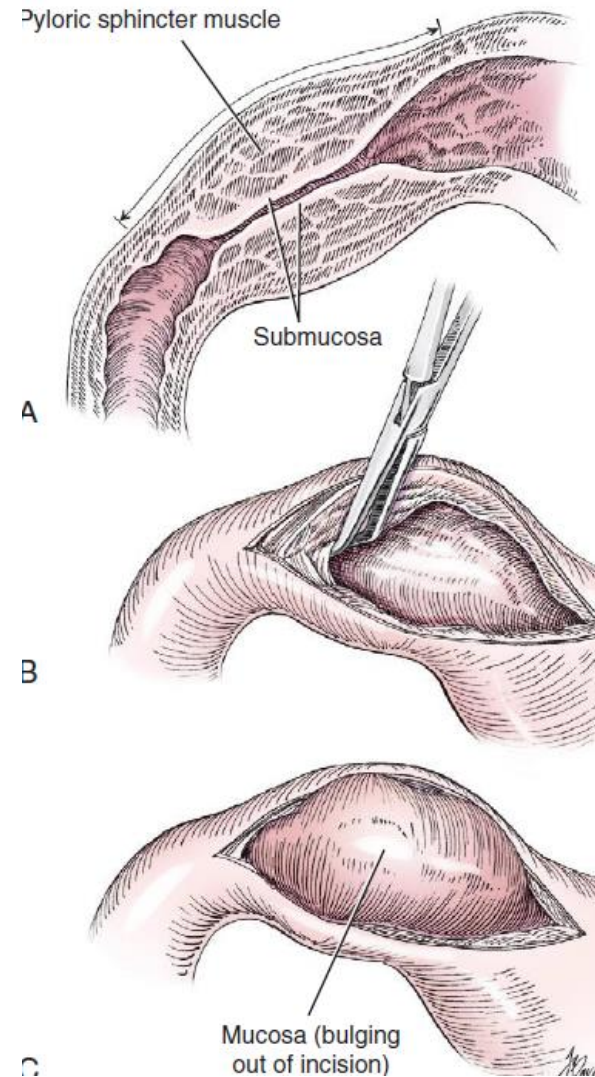
1. the Fredet-Ramstedt pyloromyotomy,
2. Heineke-Mikulicz pyloroplasty,
3. and Y-U pyloroplasty.



Fredet-Ramstedt Pyloromyotomy

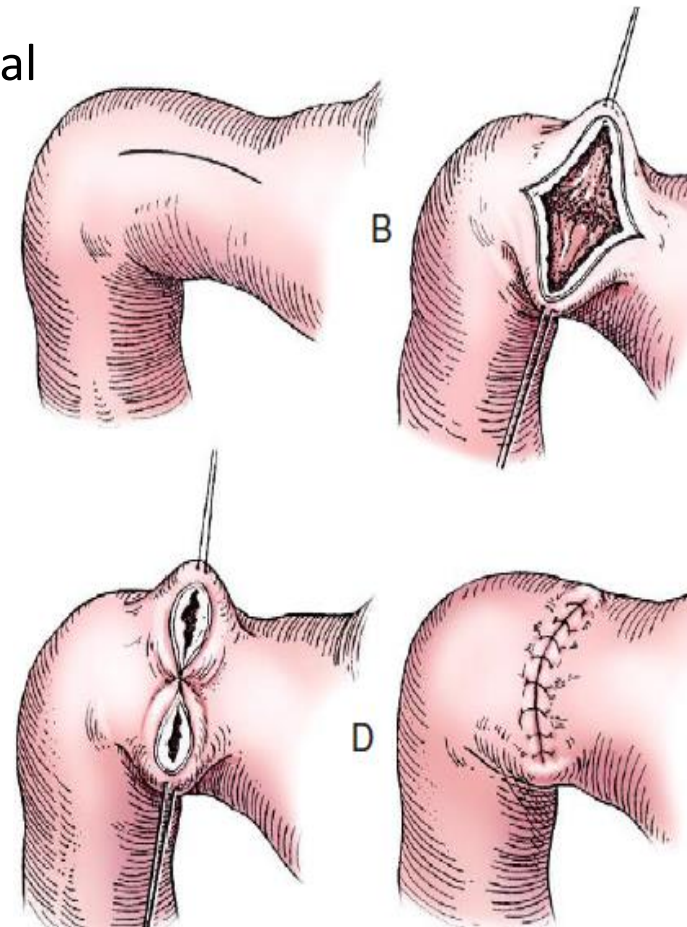
It is performed by making a longitudinal incision through serosa and muscularis of the ventral pylorus.

- The incision should be centered over the pylorus and extend 1 to 2 cm.
- When performed correctly, the gastric mucosa is not penetrated; however, its submucosal surface should protrude through the incision.
- This partial-thickness incision is left open, permitting enlargement of the pylorus



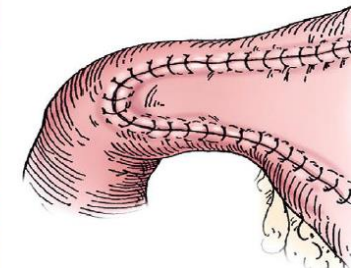
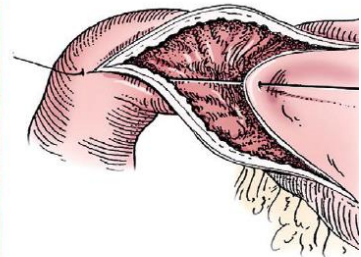
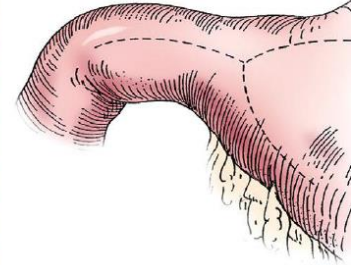
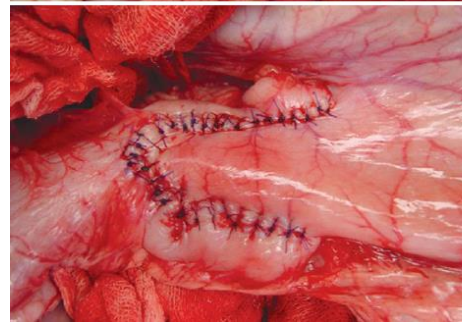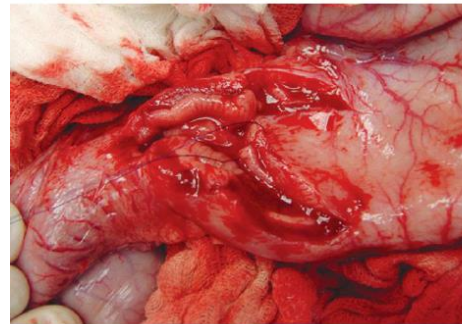
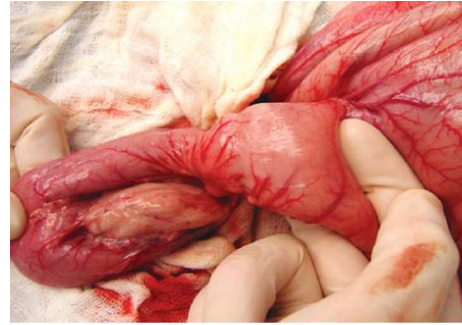
Heineke-Mikulicz Pyloroplasty

- It is similar to pyloromyotomy in that a longitudinal incision is made in the ventral surface of the pylorus; however, **the incision is created full thickness and then closed transversely.**
- *Stay sutures can be placed in the middle of either side of the longitudinal incision and retracted to provide apposition for the transverse closure.*
- stay sutures can be placed at each end of the incision and pulled together to provide the same effect.
- Closure is achieved with 2-0 or 3-0 absorbable monofilament suture material in an appositional pattern.
- Heineke-Mikulicz pyloroplasty permits full-thickness gastric wall biopsy and resection of small masses or thickened tissues along the incision



Y-U Advancement Pyloroplasty

- Y-U advancement pyloroplasty increases pyloric outflow tract diameter by advancing a portion of the pyloric antrum into the region of the pyloric sphincter.
- A Y-shaped ***full-thickness incision*** is centered over the pylorus.
- The incision for the body (or main stem) of the Y is made through the antimesenteric border of the duodenum, and the incisions for the arms of the Y extend into the pyloric antrum.



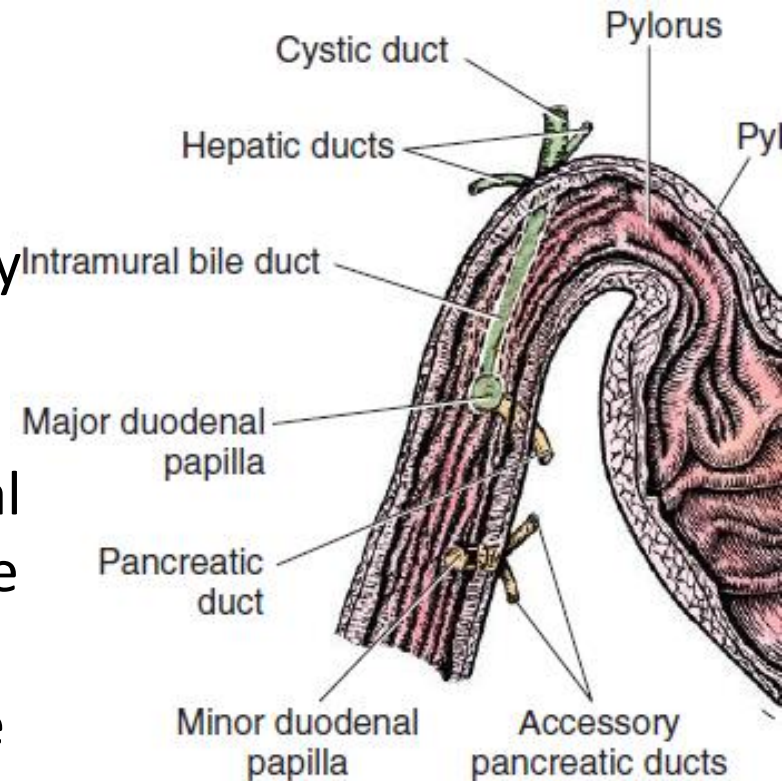
Gastroduodenal Anastomosis

it is performed in animals with pyloric outflow obstruction that cannot be treated with routine pyloroplasty techniques. Indications include neoplasia confined to the pyloric region, ulceration of the outflow tract, and some cases of pyloric hypertrophy.

When neoplasia is suspected, a 1- to 2-cm margin of normal tissue should be removed with the abnormal tissue.

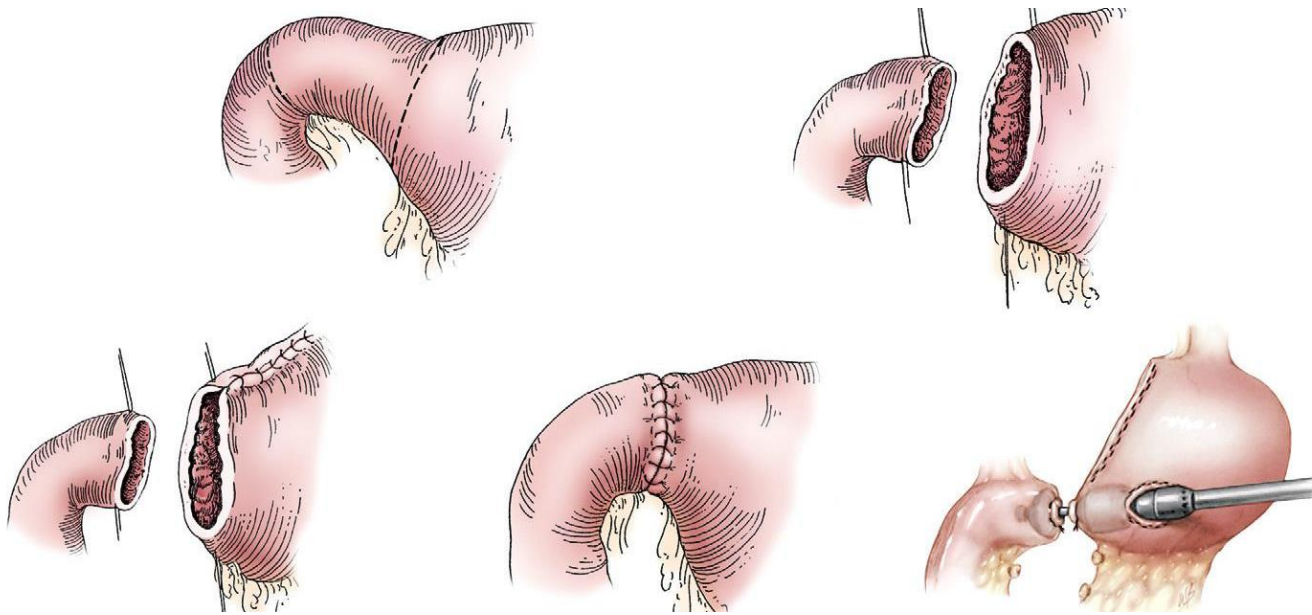
The bile duct, pancreatic ducts, and vascular supply to the stomach and duodenum must be identified before any surgical excision.

The bile duct is best identified by manual expression of the gallbladder: bile can be detected as it descends through and dilates the bile duct as it approaches the duodenum.



End-to-end anastomosis of the stomach and duodenum

- is performed with a one- or two-layer appositional pattern using a simple interrupted or simple continuous pattern of 2-0 or 3-0 absorbable monofilament suture.
- No difference in leakage was reported when one- and two-layer closures were compared
- **gastrojejunal anastomosis** are loop of jejunum is anastomosed to the greater curvature of the stomach **in a side-to-side fashion.**
- Prognosis is very poor after this procedure.



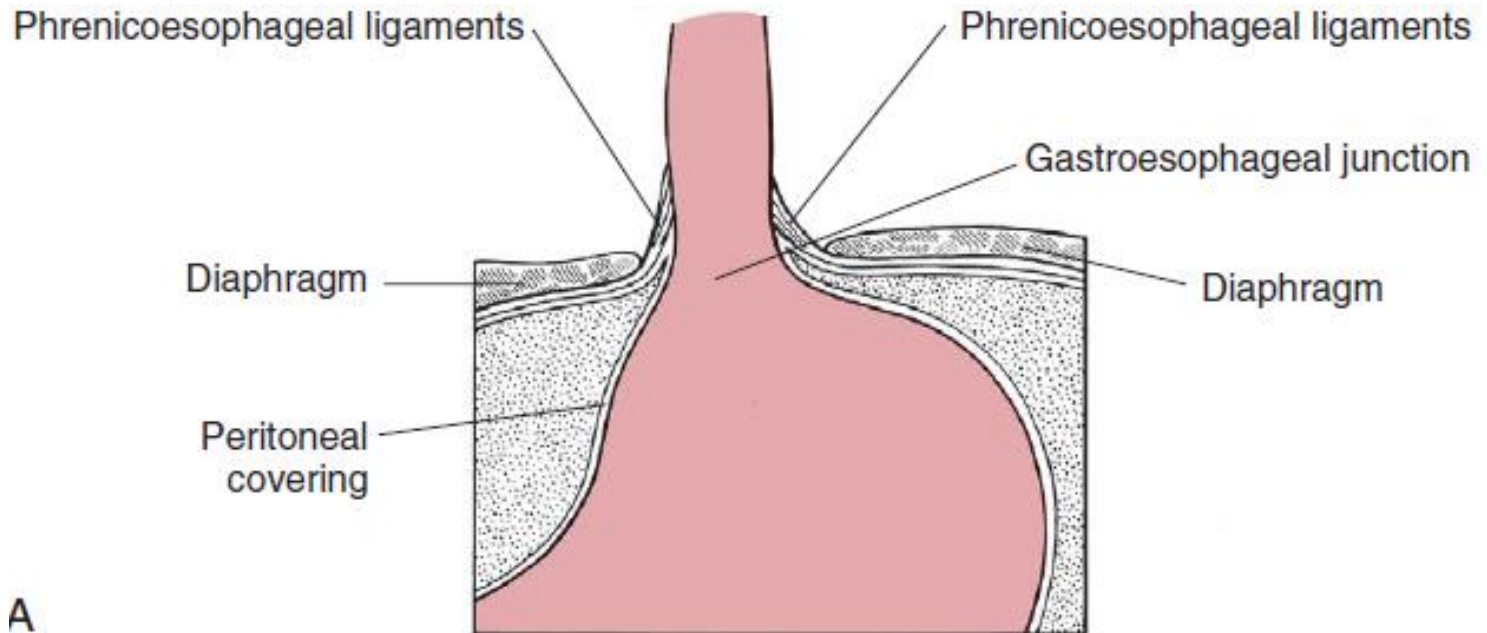
SPECIFIC DISEASES

A. Hiatal Hernia:

The esophageal hiatus is formed by the musculature of the medial portion of the lumbar crus of the diaphragm.

The thick borders of the medial portions are fused dorsally by fibrous tissue but separate to allow transmission of the esophagus, associated blood vessels, and dorsal and ventral vagal trunks before fusing again ventral to the esophagus.

Hiatal hernia refers to conditions in which elements of the abdominal cavity, most commonly the stomach, herniate through the esophageal hiatus into the mediastinum.

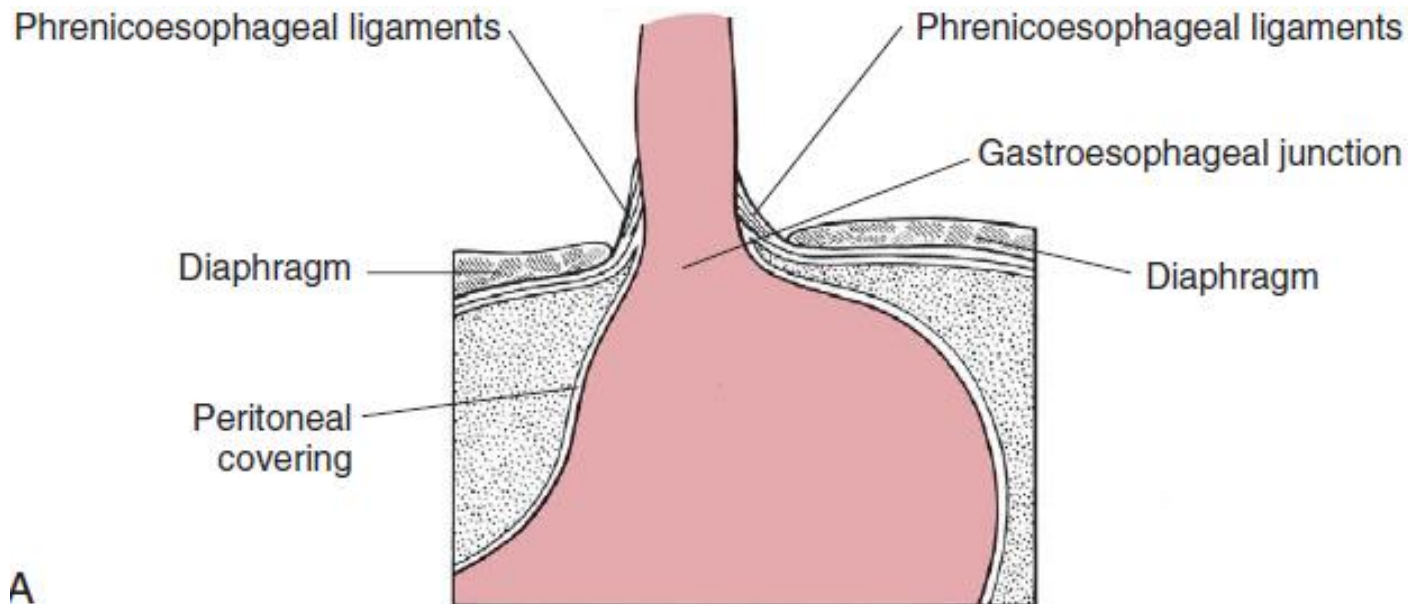


Four types of hiatal hernias are described in the human literature:

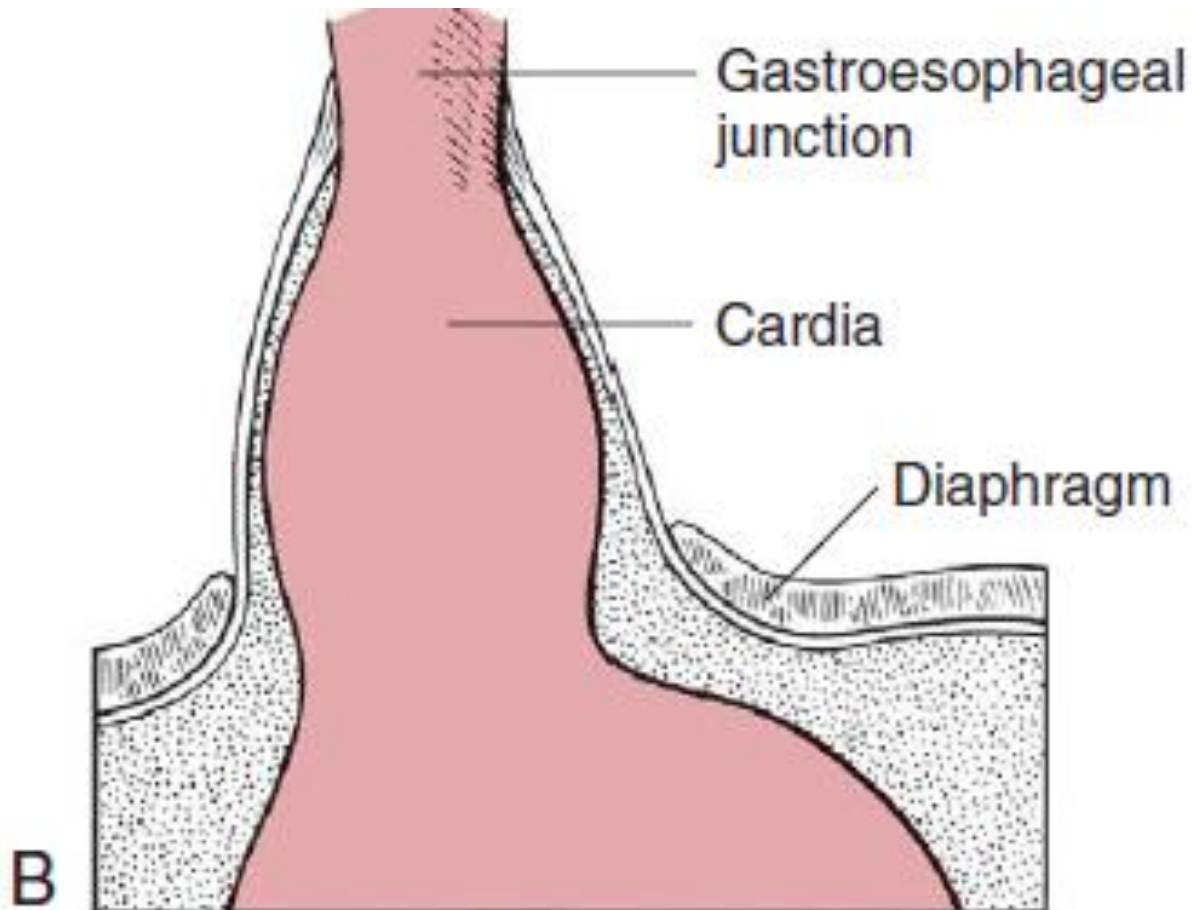
- Type I, or sliding hiatal hernia, is defined as intermittent movement of the gastroesophageal junction into the thoracic cavity.

The majority of hiatal hernias in humans, dogs, and cats have been classified historically as type I, sliding hernias,* but other types have also been reported

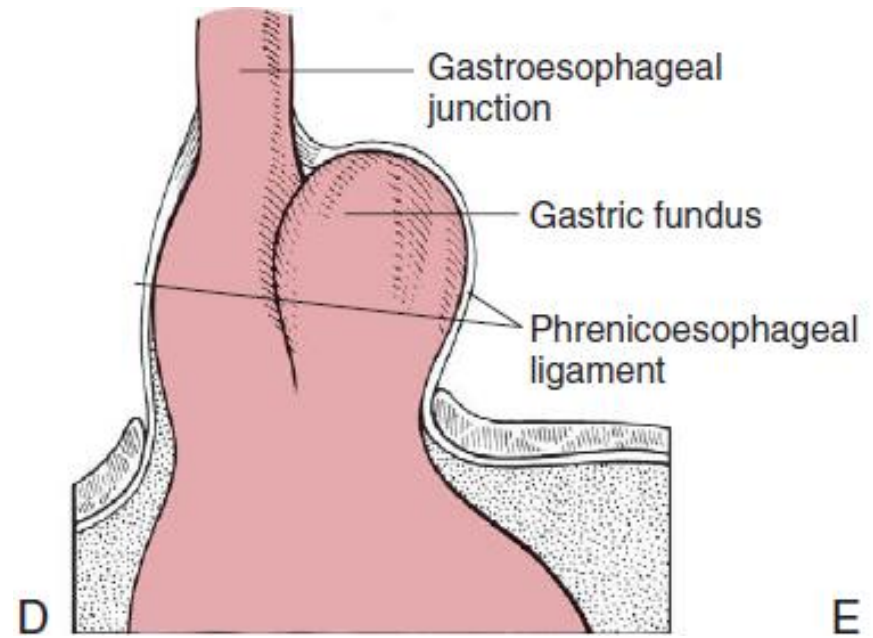
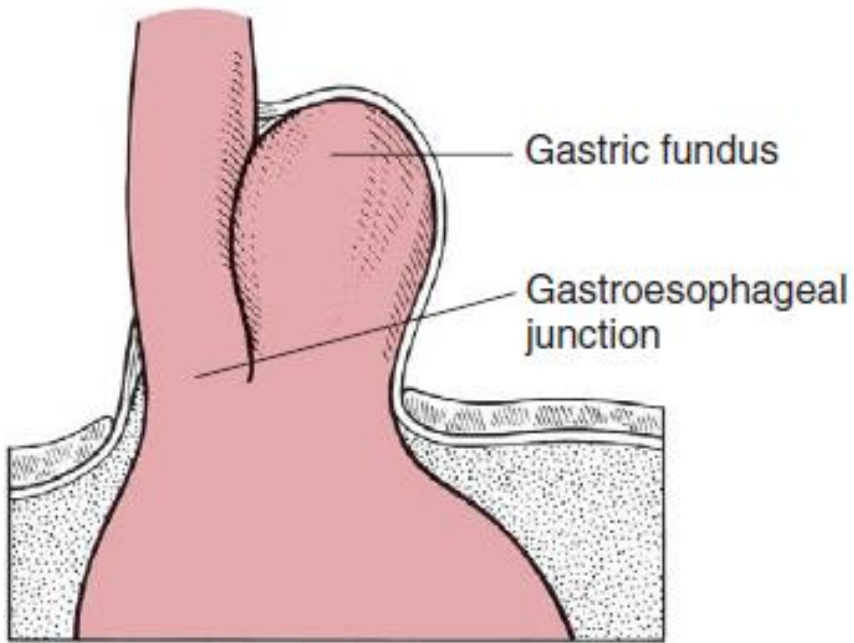
Type I hiatal hernia are usually congenital in origin and thus are observed most commonly in young animals.



type II or paraesophageal hiatal hernia, the gastroesophageal junction stays in the normal position, and a portion of the fundus serves as the leading point of herniation.



- Type III hiatal hernias include the elements of both types I and II hernias, and



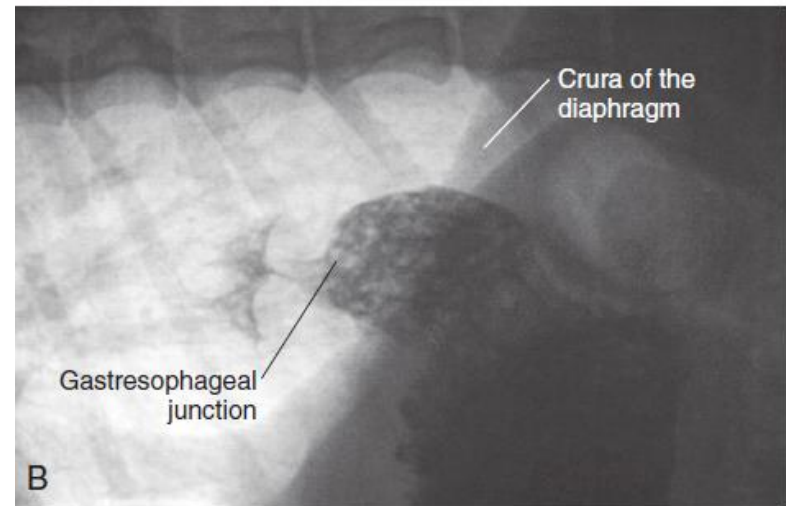
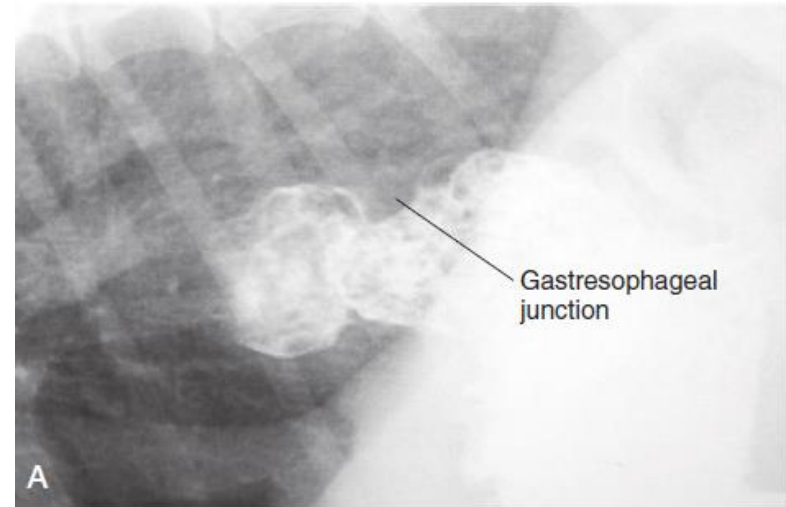
type IV hiatal hernia involves herniation of abdominal organs other than the stomach into the thoracic cavity

Diagnositics

plain radiographs and positive-contrast esophagram results.

Plain thoracic radiographs may show cranial displacement of the stomach, a soft tissue mass in the caudal thorax adjacent to the diaphragm, or gas-filled viscera in the thorax.

Positivecontrast esophagography may be needed to confirm the diagnosis of hiatal hernia and differentiate between type I and type II hernias



Medical management of hiatal hernia

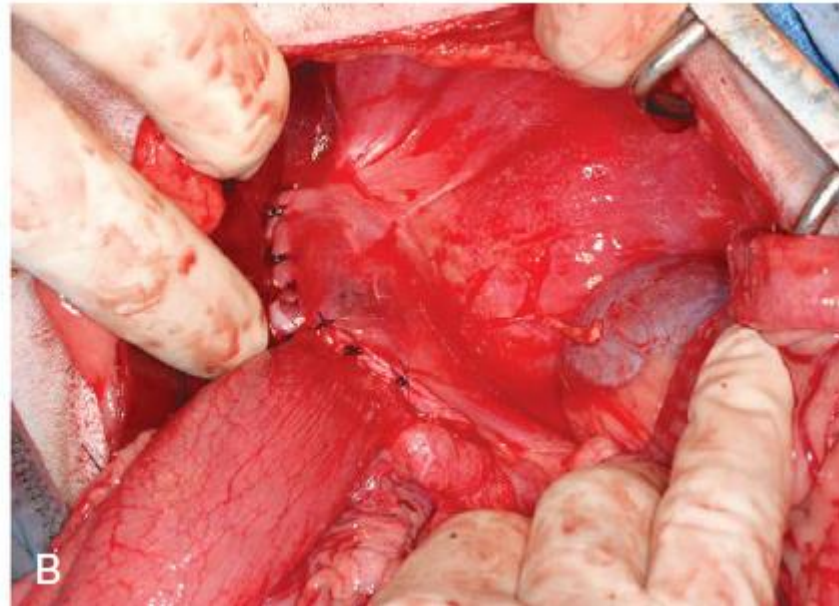
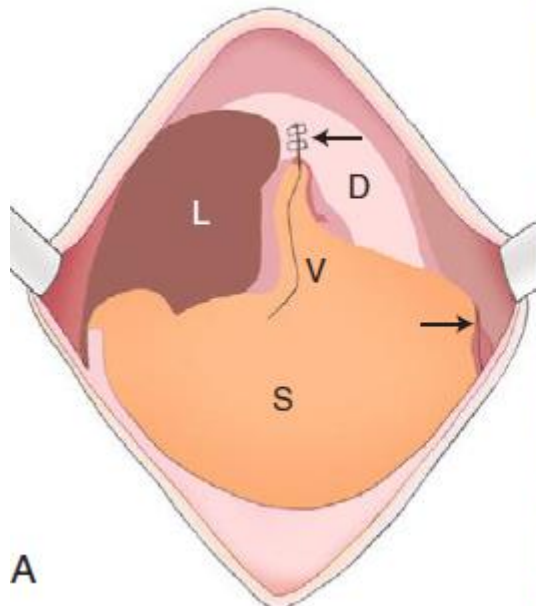
- is focused on reducing gastric acid secretion, providing esophageal mucosal protection, and increasing the rate of gastric emptying while augmenting lower esophageal sphincter tone.
- By decreasing gastric pH, antacids reduce irritation and ulceration that occur secondary to gastroesophageal reflux. Commonly used antacids include famotidine, ranitidine, and cimetidine, all of which function to block histamine (H₂), or omeprazole, which inhibits H⁺/K⁺-ATPase.
- Therapy targeted at decreasing gastroesophageal reflux includes administration of prokinetic agents, such as **metoclopramide**, that increase the rate of gastric emptying and enhance lower esophageal sphincter tone. Metoclopramide has additional benefit because it is a centrally acting **antiemetic**
- Dietary modification

Surgical Correction

(1)hiatal reduction (phrenoplasty), (2)esophagopexy, and (3)left-sided gastropexy are the techniques used most commonly, either alone or in combination.

- An orogastric tube is placed to facilitate identification of the esophagus and hiatus, and the hernia contents are reduced
- requires positive-pressure ventilation and thoracic evacuation.
- the size of the hiatal opening should be decreased for hiatal diameter; clinical judgment is used to determine the appropriate size.
- . The phrenicoesophageal ligament, made up of thickened collagen fibers, surrounds the esophageal hiatus and is incised circumferentially by some surgeons to provide a fresh cut edge to appose when reducing the esophageal hiatus(1).
- avoid accidental transection of the vagal nerve trunks and esophageal vessels that traverse the hiatus.
- Guiot et al.⁷⁵ reported successful phrenoplasty using horizontal mattress sutures of 2-0 monofilament nylon dorsally and ventrally through the crura surrounding the esophageal hiatus without concurrent transection of the phrenicoesophageal ligament.

- (2) *Esophagopexy* is also recommended and is achieved by making a **3-cm** incision to the level of the **muscularis** of the left side of the esophagus and a second incision in the superficial seromuscular layer of the left diaphragm. The incisions are apposed with 2-0 or 3-0 absorbable or nonabsorbable suture material
- (3) a left incisional fundic gastropexy is performed to anchor the stomach to the body wall.

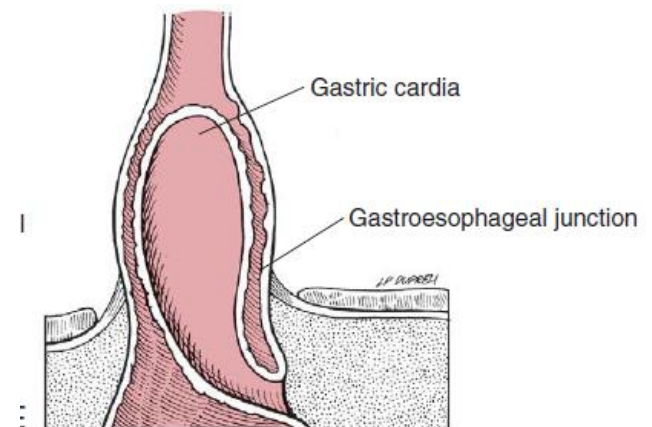


B. Gastroesophageal Intussusception

invagination of the stomach into the esophagus without displacement of the gastroesophageal junction

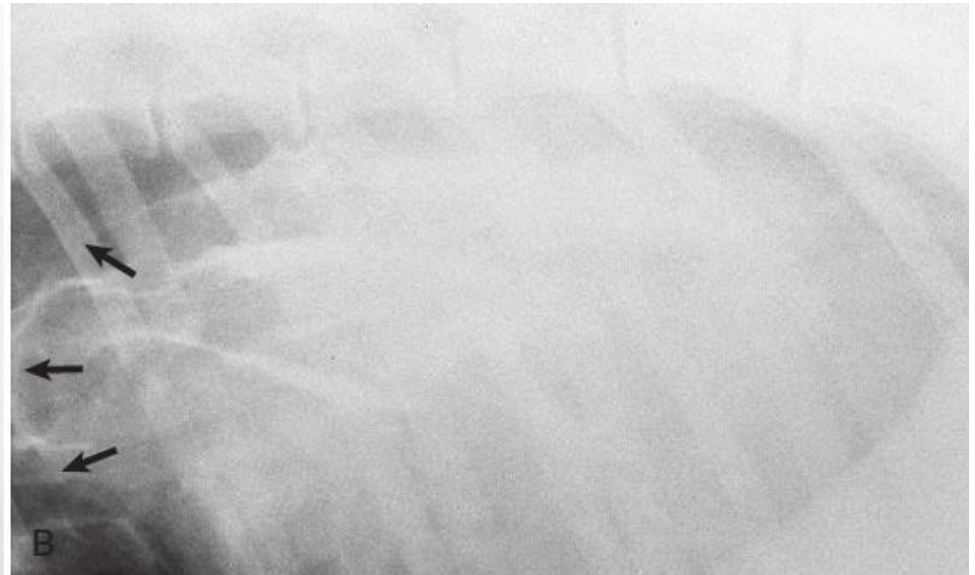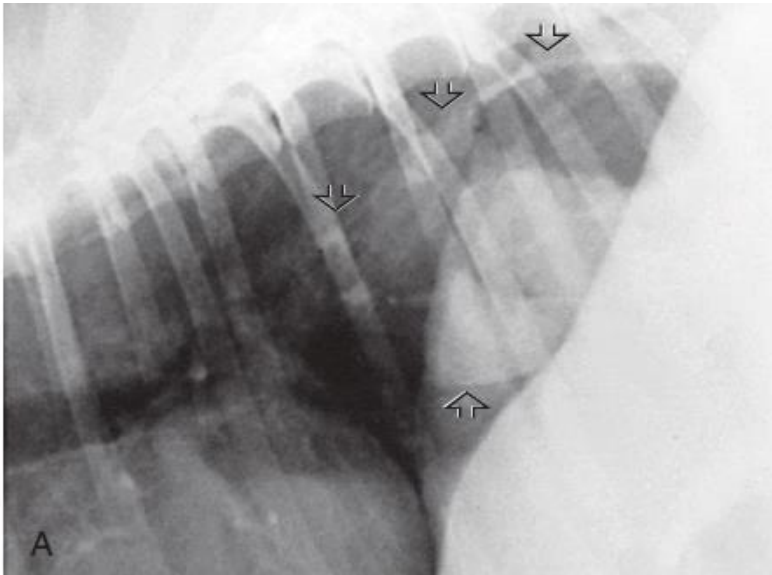
- Causes may be **megaesophagus, abnormal esophageal motility, and laxity of the esophageal hiatus**, may predispose dogs to this condition. Active **retrograde motility** initiated **during vomiting** may also play a role in invagination of the stomach into the esophagus
- ***Clinical Findings***

Severe **respiratory** compromise in acute cases and intermittent regurgitation and **vomiting** in more chronic cases.



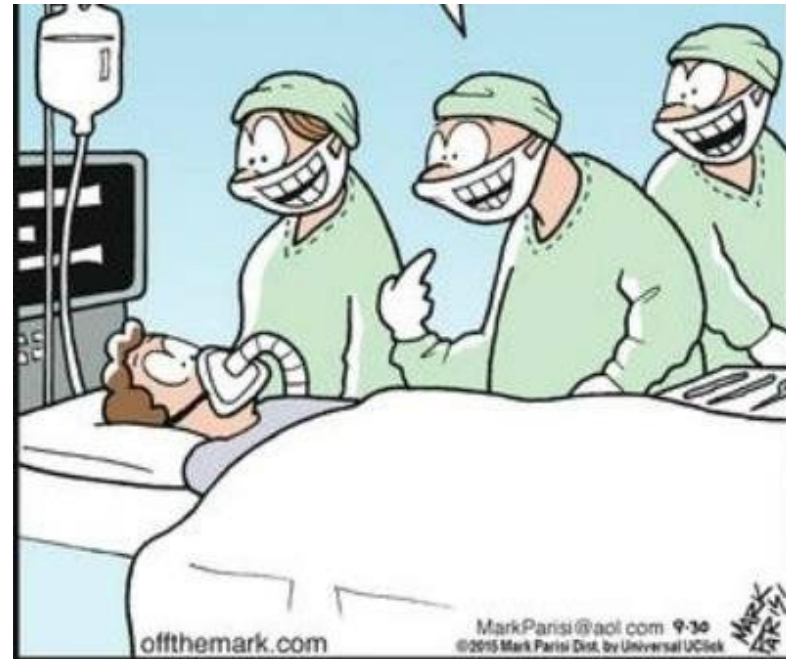Diagnostics

- **Plain thoracic radiographs** may show a soft tissue mass within the caudal esophagus and a lack of a gastric gas bubble or pylorus within the cranial abdomen.
- **A contrast esophagram** may confirm a mass lesion within the caudal esophagus.
- **Esophagoscopy** has been used to confirm the diagnosis of gastroesophageal intussusception and aids in ruling out esophageal foreign body or mass.



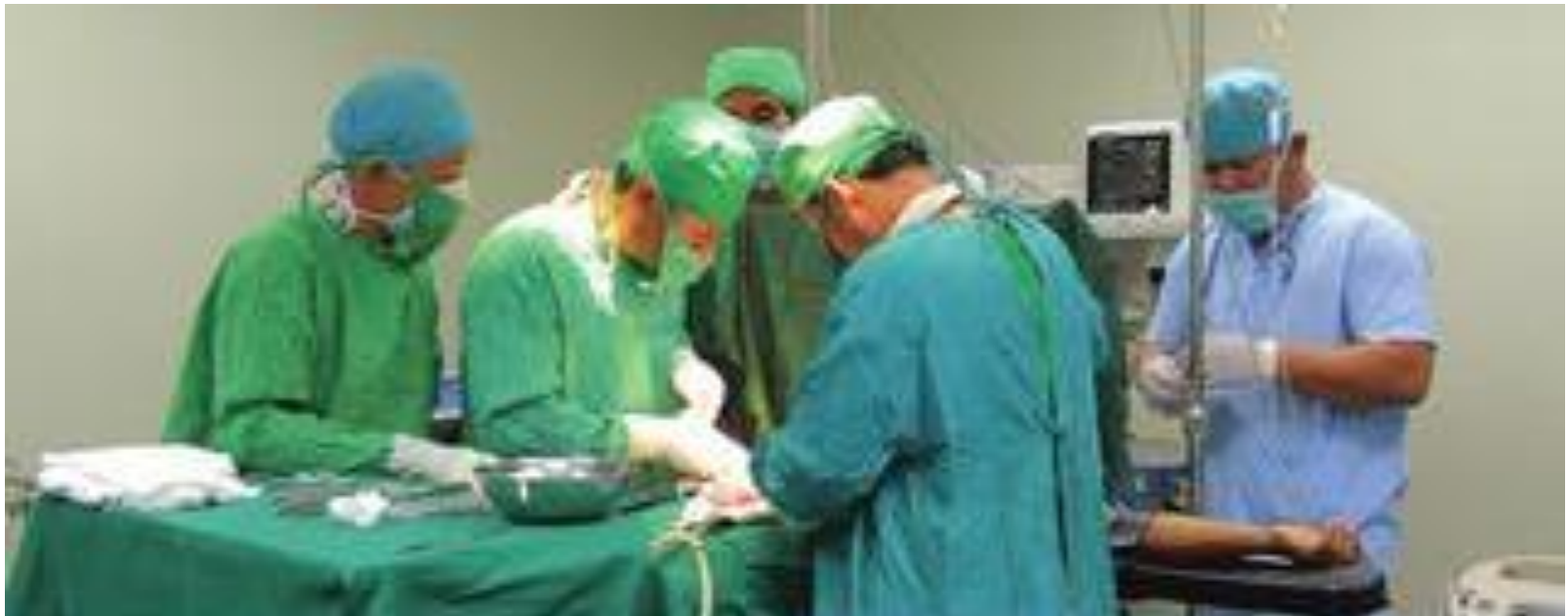Preoperative Management

- Gastroesophageal intussusception is considered **an emergency** in the majority of animals. **In chronic** intermittent cases:
- **medical management of aspiration pneumonia**
- **Fluid therapy** to maintain blood pressure
- **Supplemental oxygen** before induction of anesthesia may aid in improving the patient's clinical condition.



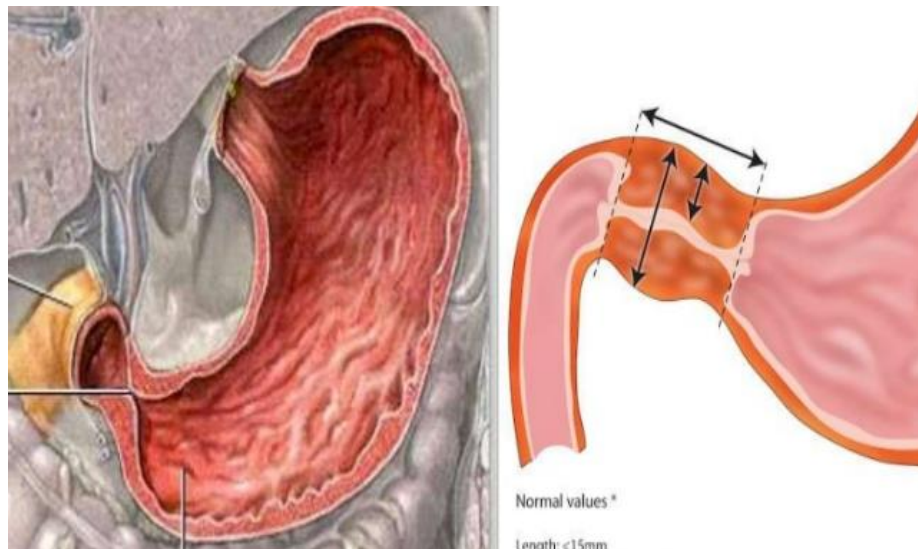
Surgical correction of gastroesophageal intussusception

- a ventral midline abdominal incision.
- The intussusception is reduced by gentle retraction of the stomach and any other herniated organs into the abdominal cavity.
- A left-sided fundic gastropexy or a combination of right- and left sided gastropexies should be performed to prevent recurrence.



Hypertrophic Pylorogastropathy

- **Congenital** obstructions are generally **muscular in origin** and occur most commonly in **brachycephalic breeds younger than 1 year of age**. Congenital muscular outflow obstruction is frequently termed *pyloric stenosis*.
- Acquired obstructions may be mucosal or a combination of mucosal and muscular in origin. Acquired obstructions occur most commonly in small-breed dogs (<10 kg)



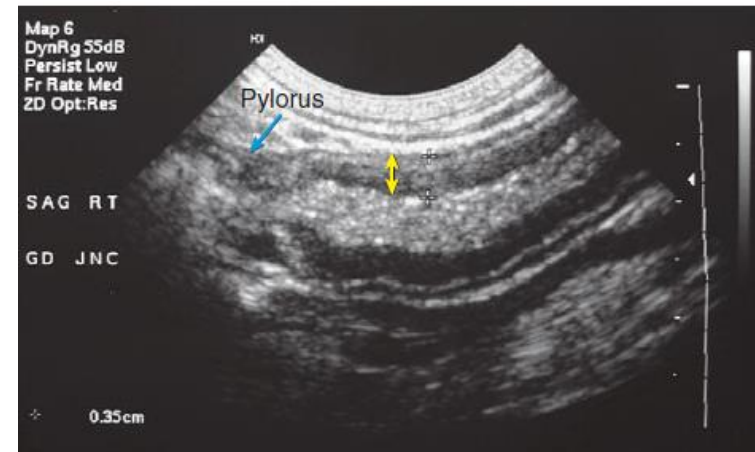
Clinical Findings

- Chronic intermittent **vomiting, Regurgitation and hypersalivation.**

The diagnosis of delayed gastric emptying:

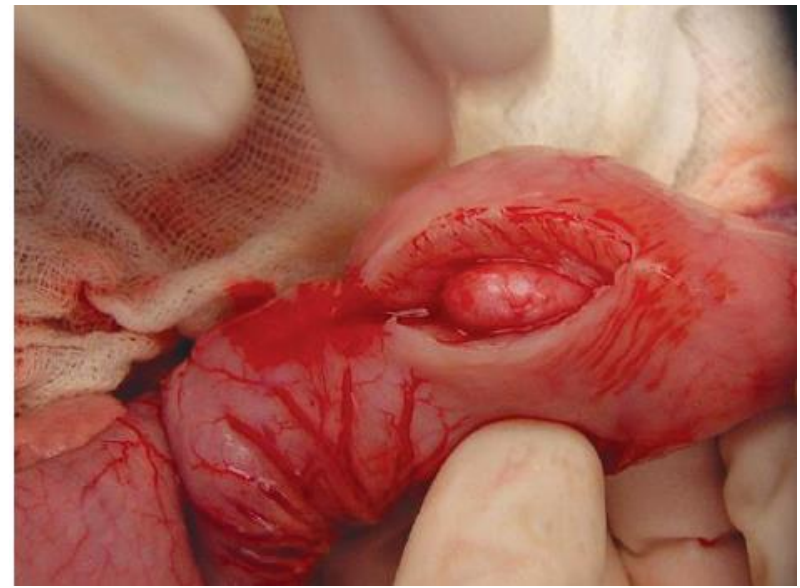
- abdominal radiography confirms retention of gastric contents after a fast of greater than 8 hours.
- Contrast radiography may show gastric distension, delayed gastric emptying, or abrupt narrowing of the pyloric area, known as an “apple core appearance.”
- In cases of **mucosal hypertrophy, endoscopic examination**

ultrasonography is helpful in some cases to **assess thickness of gastric layers** of the pyloric region



Surgical Correction

In cases of muscular hypertrophy alone, pyloromyotomy may be used to increase the pyloric outflow tract diameter (partial thickness incision)

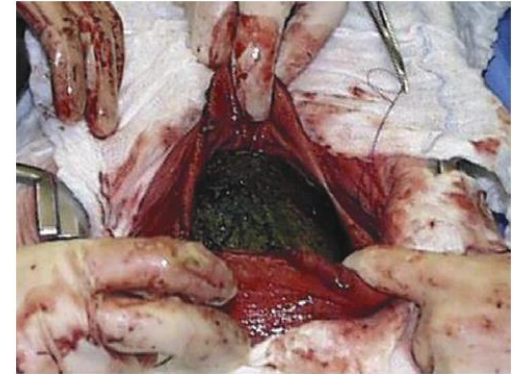

In cases of mucosal or combined mucosal and muscular hypertrophy, transverse (Heineke-Mikulicz) or Y-U advancement pyloroplasty is indicated. (full thickness incision)

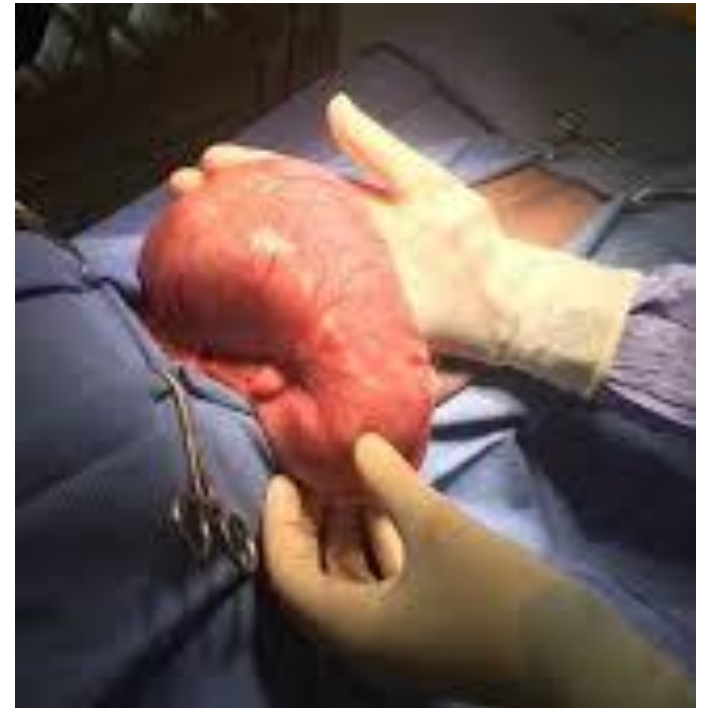Gastric Foreign Body

the most common indication for gastrotomy is removal of a foreign body. it occur more commonly in dogs than cats.

- in dogs it may include plastic, bones, sharp objects (e.g., fishhooks), wood, and organic material.
- Endoscopic removal of gastric foreign bodies has become much more common and has variable success rates



In some instances, the ingested material changes after ingestion, as is the case with some wood glue compounds, and becomes an obstructive foreign body within the stomach



Clinical Findings

- Vomiting
- Abdominal distension (pyloric ob.)
- abdominal pain (ulcer)
- Electrolyte and acid–base abnormalities (Vomiting)

Diagnostics

- 95% of gastric foreign bodies were visualized on plain abdominal radiographs
- When performing positive-contrast gastrography , iodinated water-soluble is used, to avoid barium sulfate.
- Ultrasonography
- If free abdominal fluid is detected, it should be collected under ultrasound (sepsis)

Surgery

Surgical removal of the gastric foreign body is accomplished through a simple gastrotomy in most cases.



Wood glue removed from the stomach.

Gastric Neoplasia and Infiltrative

- Disease The most common gastric neoplasms of dogs and cats are gastric adenocarcinoma and lymphosarcoma,
- In dogs, the majority of gastric neoplasms are malignant and epithelial in origin.
- **Benign Masses.**
- The most common benign tumor reported in dogs is leiomyoma.
- In cats, the most common malignant tumor of the stomach is lymphoma. feline leukemia virus infection

- ***Clinical Findings***

weight loss, vomiting, anorexia, and occasionally diarrhea. Gastric ulceration secondary to the primary disease frequently results in bleeding and anemia.

- **Diagnosics**

- abdominal radiography and
- Ultrasonography
- endoscopic examination and biopsy of gastric lesions.

- ***Treatment***

- The role of surgery in cases of neoplastic or infiltrative disease of the stomach is primarily diagnostic but may be therapeutic in some cases

- lymphoma have a median survival time of 704 days with chemotherapy (e.g., prednisone or chlorambucil)

Gastric Ulceration

- disrupt the سلامة integrity of the gastroduodenal mucosa and overwhelm the gastric mucosal protective mechanisms leads to gastric ulceration.
- The most common causes of gastric ulceration in small animals are hepatic disease, neoplasia, renal disease, and nonsteroidal antiinflammatory drug (NSAID) or corticosteroid administration
- Gastric ulceration is associated with decreased prostaglandin production, decreased blood flow, excess gastric acid secretion, or decreased production of bicarbonate or mucus

- renal failure lead to decreased renal clearance of gastrin lead to hypergastrinemia
- Hepatic disease decreased hepatic degradation of gastrin and histamine, both of which stimulate acid secretion.
- portal hypertension and thrombosis of gastric vessels lead to derangement of mucosal blood flow.
- **Nonsteroidal Antiinflammatory Drugs and Glucocorticoids.** Two mechanisms, including direct topical effect of the weakly acidic and lipid-soluble NSAIDs on gastric mucosa and systemic inhibition of cyclooxygenase (COX), resulting in decreased gastroprotective prostaglandin production leads to decreases in mucosal blood flow, epithelial mucus production, bicarbonate secretion.

- ***Clinical Findings***
-
- **vomiting and anorexia.**
- **In some instances, digested blood, which has a “coffee grounds” appearance, is seen in the vomitus or melena is noted**
- **anemia from chronic blood loss into the gastrointestinal tract.**

- ***Diagnosis***
- gastroduodenoscopy or
- Exploratory laparotomy with gastrotomy is performed

Medical Management

is aimed at decreasing gastric acidity and promoting mucosal protective mechanisms

- **Histamine Receptor Antagonists.**
- Histamine (H₂) receptor Antagonists (cimetidine, ranitidine, and famotidine.)
- **Proton Pump Inhibitors.** (omeprazole and pantoprazole)
- **Sucralfate.** is a sulfated disaccharide–aluminum hydroxide complex.
- **Misoprostol.** is a gastric cytoprotective agent with both acid-inhibitory and mucosal-protective properties.

When medical management is **not an option because of the severity of the ulcer**, surgical exploration and resection are indicated

Surgery

- Gastroduodenoscopy indicated to identification of ulcerated areas of the mucosal surface.
- Surgical resection of gastric ulceration may require partial gastrectomy or, in cases in which the pylorus or antrum is involved
- the animal should be treated with a combination of drugs designed to protect the gastric mucosa

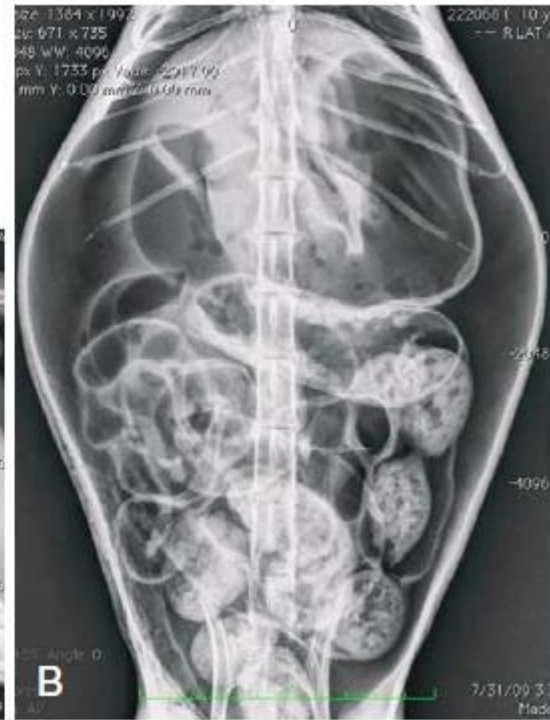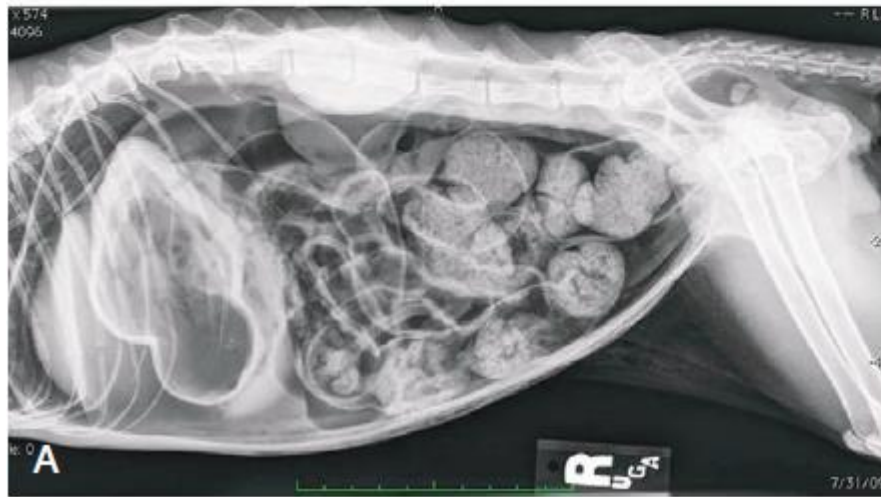Gastric Perforation

- Gastric perforation in dogs and cats is reported most often secondary to NSAID administration or neoplasia.
- Gastrinoma, a non β pancreatic islet cell tumor, is associated with hypersecretion of gastrin from antral G cells, resulting in gastric hyperacidity and subsequent ulceration.

Clinical Signs

- lethargy
- anorexia
- vomiting
- weight loss

- ***Diagnos*****tics**
- **Abdominal radiography** include loss of abdominal detail and free abdominal gas, **pneumoperitoneum** in animals with no history of recent abdominal surgery or penetrating trauma is an indication for exploratory laparotomy.
- **Abdominal ultrasonography** confirm free peritoneal fluid, free air, or regional bright mesenteric fat and in some cases may allow visualization of the perforation.
- **Endoscopic examination** of the stomach may provide additional information or confirm perforation
- **Abdominocentesis** is indicated in animals with free peritoneal fluid and may provide cytologic evidence of **intracellular bacteria** or **biochemical data, such as blood-peritoneal fluid glucose** differential above 20 mg/dL, that is supportive of a septic effusion.
- Either finding warrants exploratory laparotomy



pneumoperitoneum

- ***Surgery***
- In cases of suspected neoplasia, abnormal tissue should be resected with 2-cm margins when possible.
- In some cases, this may require **pylorectomy**.
- In cases of perforation secondary to suspected neoplasia, regional lymph node biopsy and liver biopsy are indicated to stage the extent of the disease process.
- Perforations secondary to NSAID administration are frequently located **near the pyloric antrum**.

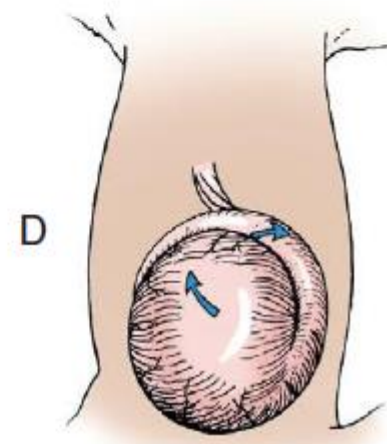
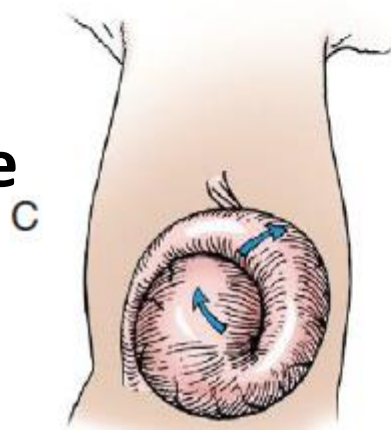
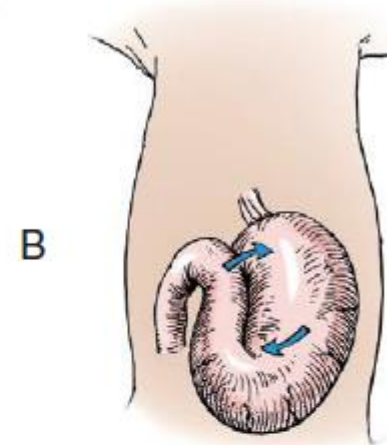
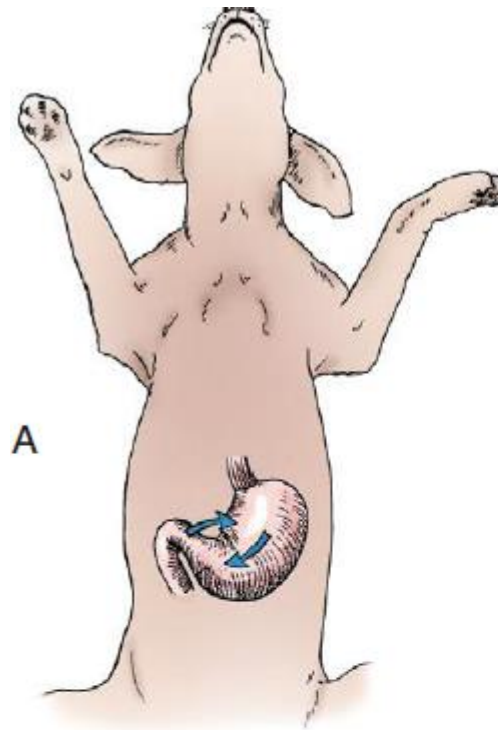
Gastric Dilatation and Volvulus

- Gastric dilatation and volvulus is a life-threatening syndrome reported most commonly in large-breed, deep-chested dogs in which the stomach rotates on its axis, trapping air within its lumen.
- Trapped air increases intra gastric pressure, lead to decreases venous flow through the abdomen by direct compression.
- Portal hypertension, systemic hypotension, and cardiogenic shock result.

Etiology

dogs include giant breed, an increased thoracic depth-to-width in a first-degree relative, feeding fewer meals per day, eating rapidly, aggressive or fearful temperament, decreased food particle size, increased hepatogastric ligament length, and exercise or stress after a meal.

- In gastric dilatation and volvulus, **the pylorus and proximal duodenum move ventrally and then cranially**
- The **hepaticoduodenal ligament is stretched** during this process, allowing **movement of the pylorus that is not normally possible**.
- The pylorus continues to **move, migrating from right to left**, which **creates a fold in the stomach**, and eventually coming to **rest on the left side of the abdomen dorsal to the esophagus**.



Pathophysiology

- **portal hypertension** produces **venous stasis** and subsequent **mucosal death** and **bacterial translocation** throughout the gastrointestinal tract
 - **venous return** from the **caudal vena cava** is **reduced**, resulting in **cardiogenic shock**.
1. **Cardiac Dysfunction.** inadequate coronary vessel flow , results in myocardial ischemia. the specific cause is unknown.
 2. **Gastric Wall Necrosis** capillaries are collapsed secondary to intragastric pressure and subsequent necrosis of the gastric mucosa occurs, systemic hypotension results in full-thickness gastric wall necrosis in some dogs
 3. **Bacterial Translocation.**

- ***Clinical Findings***
- abdominal distension, unproductive vomiting or يحاول يتقيأ retching, restlessness, and hypersalivation the stage of shock at the time of presentation
- ***Diagnostics***
- **Radiographs.** When necessary, radiography is done with the dog in right lateral recumbency to confirm the diagnosis.
- **Laboratory Findings.** Blood analysis
- Plasma lactate concentrations are helpful in evaluating perfusion, resuscitation efforts, and possibly in predicting survival. 6.0-9.0 mmol/L

Preoperative Management

- Fluid therapy is the most critical component of therapy before surgery
- Oxygen supplementation using flow-by methods is recommended to increase the oxygen saturation of hemoglobin.
- Broad-spectrum antibiotic therapy
- Gastric decompression may be achieved via orogastric intubation or percutaneous placement of an over-the-needle catheter or a trocar into the gas-distended stomach.

Surgery

The goals of surgery are to reposition the stomach, remove devitalized or necrotic tissue, and create a permanent adhesion between the pyloric antrum and right body wall.

- Stomach should be decompressed completely
- the surgeon must identify the **pylorus** and retract it toward the **right side** of the abdomen while using the opposite hand to push the **body of the stomach dorsally**. with rotation of 180 to 270 degrees most common.

gastric viability in dogs

- the most commonly used method to assess gastric viability in dogs with gastric dilatation and volvulus is: **visual and tactile** assessment of the gastric:
- , gastric wall thickness (as estimated by palpation),
- serosal surface color,
- presence of peristaltic waves,
- and bleeding after serosal incision
-
- were 85% accurate in determining gastric wall viability.

Devitalized wall, which is thin and gray or green in color, should be resected or **invaginated**. Resection should be performed to the level of bleeding. •

- **Splenectomy** is performed only if there is evidence of vascular **thrombosis or necrosis of the spleen**
- Options to create this type of permanent adhesion include incisional gastropexy, belt-loop gastropexy, circumcostal gastropexy, incorporating gastropexy, and gastrocolopexy