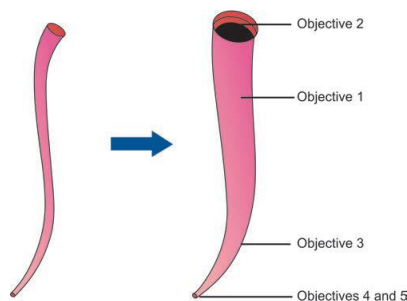


Cleaning and Shaping of Root Canal

The major biologic aim of endodontic therapy is to eliminate apical periodontitis by disinfection and sealing of root canal systems. Although “cleaning and shaping” accurately describes the mechanical procedures, it should be emphasized that enlarging canals directly facilitate the cleaning action of irrigants and the removal of infected dentin. Therefore, the objectives of root canal treatment could be divided into Mechanical and Biological. Schilder described 5 mechanical and 4 biological objectives for successful root canal therapy.

The Mechanical objectives are:

1. The root canal preparation should develop a continuously tapering cone. This shape mimics the natural canal shape.
2. Making the preparation in multiple planes which introduces the concept of “flow”. This objective preserves the natural curve of the canal.
3. Making the canal narrower apically and widest coronally. To create a continuous tapers up to apical third which creates the resistance form to hold gutta-percha in the canal.
4. Avoid transportation of the foramen. There should be gentle enlargement of the foramen while maintaining its position.
5. Keep the apical foramen as small as possible. Since over-enlargement of the apical opening contributes to number of iatrogenic problems. Doubling the file size apically increases the surface area of foramen for four folds (πr^2).



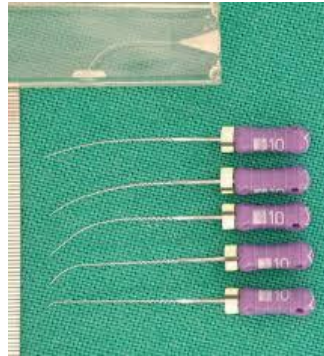
The Biological objectives are:

- 1- Confinement of instrumentation within the root canals only.
- 2- Ensure not to force necrotic or instrumentation debris beyond the apical foramen.
- 3- Optimum debridement of the root canal space.
- 4- Creation of sufficient space for intra-canal medicaments.

Aids in preparation of root canal

1- A Patency File (glide-path file): is a small K-file (usually a size #10 or #15) that is passively extended just through the apical foramen. This ensures opening of the canals and facilitate working length estimation.

2- Precurved instrument: In case of a curved canal, the instrument should be precurved to estimate the curvature of the canal. This is true only in case of stainless steel instrument, but nickel titanium instrument is flexible and cannot be curved.



3- The use of intracanal irrigation solutions that serve many advantages such as dissolving and flushing out of the debris from the root canal, lubricant for the cutting motion of the files within the canal, in addition to its antimicrobial activities. The most popular intra-canal irrigation solution is Sodium hypochlorite (NaOCl) 2.5-5.25%. This can be delivered inside the canal by using hypodermic syringe.

4- Examination of the instruments: Each instrument should be examined each time before insertion inside the root canal to verify the presence of any sign of fatigue, stress or damage, so any instrument showing such a sign should be discarded.

5- Use of instruments in sequential order: Root canal preparation is done gradually by using successively larger files (never skip any size of instrument) e.g. size 20 followed by size 25 then 30 and so on, but not size 20 then size 30.

Manual or Hand instrumentation techniques:

Several methods were developed for manual root canal preparation:

1- Standardized technique:

- This technique is developed by Ingle and it is also called 'single-length technique'.
- Objective of this preparation is to prepare the canal to a uniform size using successively larger instrument to the working length.
- This technique uses reaming action and produces a canal shape or taper that resembles the tapering of the instrument. The instrument should engage on the apical, middle and coronal parts at the same time, but we rare see such a canal because it's elongated buccolingually.

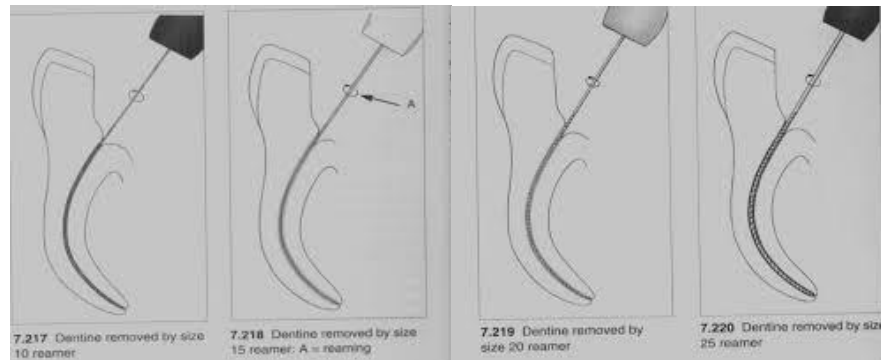
- Creation of a true standardized tapered preparation is difficult in ideal situations and impossible in curved canal.
- This preparation is indicated for silver cone obturation but may be also employed for gutta-percha.

Procedure

Reaming action is used in straight canal. The procedure is as follows:

1. The canal should be flushed with irrigant solution.
2. We start for example with size 10 by reaming action until the instrument is very loose.
3. The canal should be flushed with irrigant solution.
4. We use size 15 instrument until the instrument is loosened, then irrigation.
5. Then we switch to size 20 and do reaming until the instrument is loosened, then irrigation.
6. We switch to size 25 and do reaming until the instrument is loosened.

We do this procedure until white clean dentine shavings are removed from the root canal and now the canal is ready for obturation.



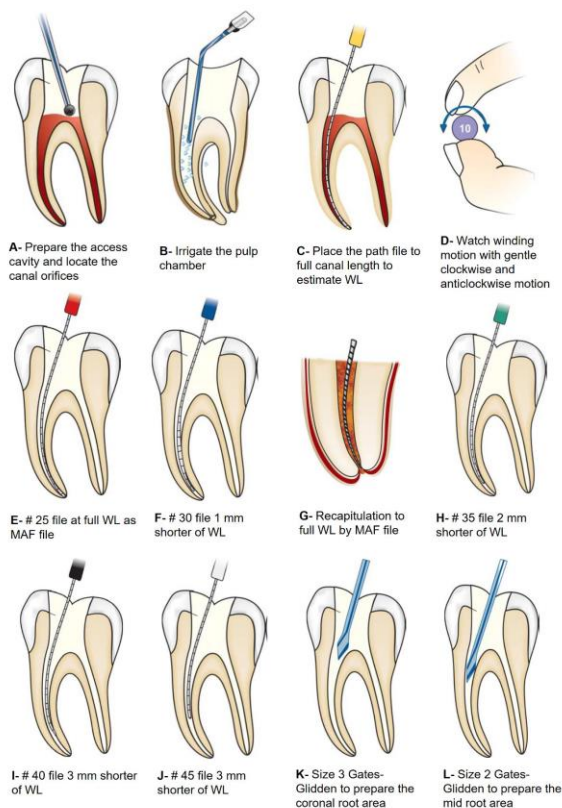
2- Step-back technique:

- The step-back technique was introduced by Clem and Weine in 1960.
- Objective is to keep the preparation as small as practical apically with an increasing taper coronally throughout the canal.
- The final result is a preparation with small apical enlargement and marked taper from apical to coronal. The wide, less flexible instruments are avoided in the preparation of the apical portion of the canal. This will lessen the forces by these instruments on the canal walls, which in turn preserve the original shape of the canal.
- Filling with gutta-percha is made easier because more room space will be available for spreader & plugger to penetrate more apically to get maximum condensation.

The technique is as follow:

- After access of the pulp chamber and opening of the canal orifices, flood the pulp chamber with irrigant (Fig A and B).

- Establish the working length of each canal using path file which could be file # 10 (Fig C).
- Insert the next size file (# 15) into the full WL of the canal with a gentle watch-winding motion (for watch-winding motion see Fig D). Then start acting the file on the canal walls either with filling or quarter-turn-and-pull motion until the file becomes loosely moved within the canal.
- Remove the instrument and irrigate the canal.
- Place the next larger size file to the working length in similar manner and again irrigate the canal, until a clean white dentin will appear on the file tip. This file is called the MAF which is the final instrument that goes to the full working length (Fig E).
- Don't forget to recapitulate the canal with the previous smaller size instrument. This breaks up apical debris to be easily washed away with the irrigant.
- Next use a larger file, i.e. one size larger than MAF into the canal but 1 mm shorter than WL and file (Fig F). Sometimes the dentinal shavings are pushed in the apical 1 mm so we use the MAF to retain the patency of the full working. This is called recapitulation. (Fig G).
- This process can be repeated to 3 or more, larger files until a good flaring and cleaning of the canal is obtained (Fig H, I and J). Furthermore, flaring of the coronal third of the canal can be more enlarged by using Gates Glidden rotary drills to obtain better canal cleaning coronally (Fig K and L).



Differences between flaring and standardized techniques:

1. We can use flaring technique in curved canal and can't use the standardized technique in that canal.
2. Standardized technique is indicated for silver cone obturation and may be employed for gutta-percha, while in the flaring technique, the filling material is gutta-percha.
3. Objective of the standardized technique is to prepare the canal to a uniform size using successively larger instrument to the working length, while the objective of the flaring technique is keeping the apical preparation as small as practical with an increasing taper throughout the canal.
4. We need recapitulation in the flaring technique to check the patency of the canal, while in standardized technique we don't need recapitulation.
5. The final preparation will have the same shape of the tapering instrument we use in standardized technique, while the final shape of the canal will be flared, narrower at the apical part and wider in the coronal part in flaring technique.
6. In flaring technique, in each switching from size to the next (after we reach MAF), we subtract 1mm, while this is absent in standardized technique.

Errors in root canal preparation:

1. Over instrumentation:

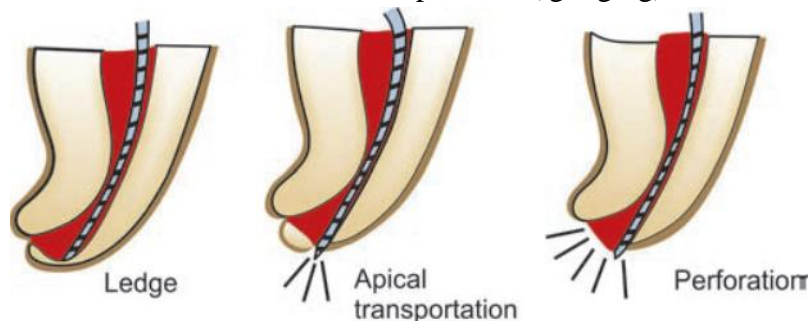
Passage of the file through the apical foramen, the apical constriction here has been violated and injury to the periapical area will occur.

2. Under instrumentation:

File don't reach the correct working length (so you leave 2-3mm). Part of the canal remains unprepared and full of bacteria and debris which leads to infection and inflammation.

3. Ledge formation and perforation:

Ledge defined as artificially created irregularities in the lateral wall of the canal as a result of using uncarved instrument in curved canal with excessive pressure (gouging)



4. Failure to debride all canals:

Sometimes a canal may not be located and therefore; not debrided.

5. Separated instrument:

If a file or reamer is fractured and locked in a canal, we try to remove it or by-pass it.

The causes of fracture of the instrument are:

- ✓ Small access opening.
- ✓ Using non-flexible instrument with extreme pressure.
- ✓ Skipping instrument sizes.
- ✓ Fatigued instruments.

