

Operative dentistry

Lec.14

د. شذی

Clinical technique for direct Class III, Class IV and Class V restorations

Cavity Preparation for Composite Restoration:

Three designs of tooth preparations for composite restorations, and sometimes they are used in combination. The designs include:

- (1) Conventional (2) Beveled conventional (3) Modified

Class III Tooth Preparation:

There is a choice between facial or lingual entry into the tooth.

Indications for Lingual Approach:

1. To conserve facial enamel for enhanced esthetics.
2. Carious lesion is positioned lingually.
3. Lesion is accessible from lingual.
4. Color matching of the composite is not as critical.
5. Discoloration or deterioration of the restoration is less visible.

Indications for Facial Approach:

1. The carious lesion is positioned facially.
2. Teeth are irregularly aligned, making lingual access undesirable.
3. Extensive caries extent into facial surface.
4. Faulty restoration that was originally placed at the facial surface.

Conventional Class III

Indicated for restorations involving the root surface

1. Using a No.1/2, 1, 2 round bur prepare the outline form on the root surface.
2. Extend the preparation into sound walls.
3. Extend pulpally 0.75mm in depth.
4. The gingival /cervical and incisal wall is perpendicular to the root surface (box like design).
5. A continuous groove retention can be prepared 0.25mm(1/2 of diameter of bur) into dentine of the gingival and incisal walls with a ¼ round bur.
6. The groove is placed at the junction of the axial and the external walls.
7. Clean preparation and inspect the final preparation.

Beveled Conventional Class III

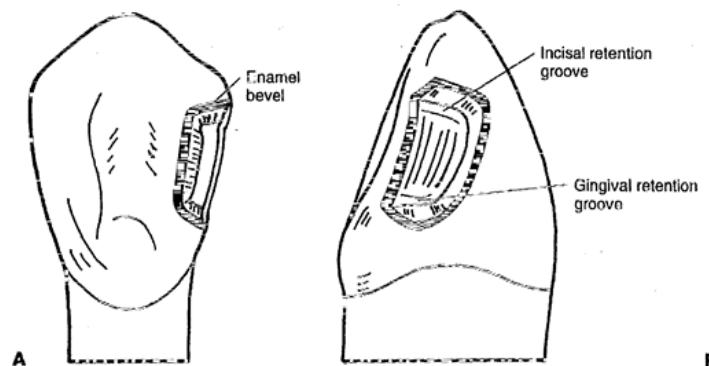
- Indicated for replacing an existing defective restoration in the crown portion of the tooth.
- When restoring a large carious lesion for which the need for increased retention and/ or resistance form is anticipated.

Lingual Access:

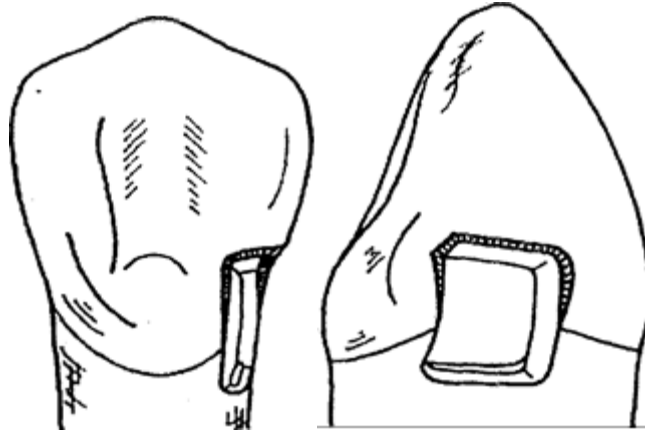
1. Use a round bur No.1/2, 1, 2 depending on the size of caries to enlarge the opening sufficiently to allow for caries removal.
2. Extend external walls to sound tooth structure using a straight bur.
3. Extend the gingival and incisal walls up to extent of caries or location of old restoration.

Unless necessary, DO NOT:

- Include the proximal contact.
 - Extent into facial surface.
 - Extent subgingivally.
4. Create an initial axial wall depth of 0.2 mm into dentin/DEJ (approximately 0.75-1.25mm in depth).
 5. Axial wall is convex, following the external contour of the tooth.
 6. Remove all remaining infected dentin, using a round bur or small spoon excavator.
 7. Remove friable enamel at the margins.
 8. If necessary , prepare retention (groove or coves)
 - Prepare it along the gingivoaxial line angle, and sometimes at the incisioaxial line angle 0.25mm with a ¼ round bur.



9. Place cavosurface bevel or flare at the enamel except at the gingival margin area.
10. Use a flame shape or round bur resulting in a 45 degrees angle to the external tooth surface.
11. Bevel width should be 0.25 to 0.5mm.
12. Clean the preparation of any debris and inspect final preparation.



Combination preparation design for cl III lesions that extend onto the root surface.

Facial Access

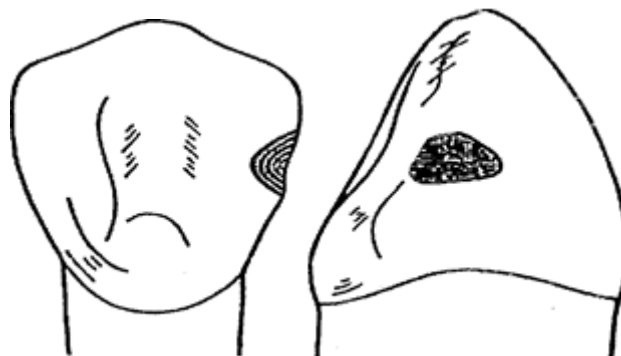
- Same stages and steps are followed.
- procedure is simplified because of easy access

Modified Class III

- Most used type of cavity preparation.
- Indicated for small and moderate lesions or faults.
- Designed to be as conservative as possible.
- Preparation walls have no specific shapes or forms.
- Preparation design appears to be scooped or concave

1. Use a 1/2, 1, 2 round bur, point of entry is within the incisogingival dimension of the lesion, perpendicular to the enamel surface.

2. Remove all remaining caries or defect.

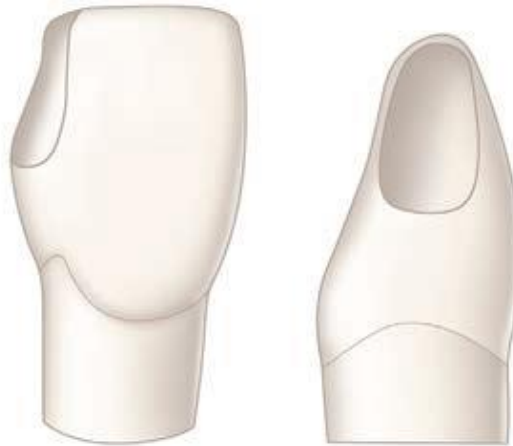

3. No attempt is made to create a uniform axial wall.

4. Place cavosurface bevel or flare at the enamel except at the gingival margin area.

5. Use a flame shape or round bur resulting in a 45 degrees angle to the external tooth surface.
6. Bevel width should be 0.25 to 0.5mm.
7. Clean the preparation of any debris and inspect final preparation.

Class IV Tooth Preparation



Facial view

Proximal view

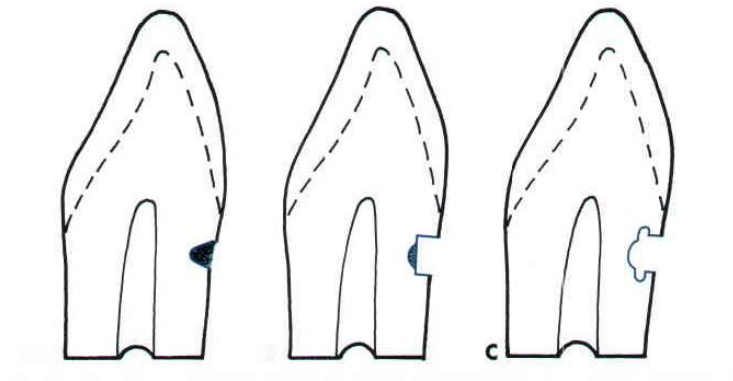
- preoperative assessment of occlusion is very important (placement of margin in noncontact areas)
- shade selection is more difficult
- preparation is similar to Class III except that the preparation for class IV is extended to the incisal angles For fracture: If no caries or pulpal involvement a bevel is the only preparation necessary 0.25- 0.5mm enamel bevel should be placed around the periphery of the cavity
Use of Pins
* Retentive pins are not needed because the adhesive technique provides sufficient retention for the restoration.

Class V Tooth Preparation

Conventional

- the feature of the preparation include a 90 degree cavosurface angle, uniform depth of the axial line angle, and sometimes, groove retention form.
 - conventional design is indicated only for portion of the lesion extended onto the root surface
1. Use a tapered fissure (No. 700, 701, or 271) or No.1 or 2 round bur.
 2. Make entry at 45 degrees angle to tooth surface, this should result to a 90 degree cavosurface.

3. Axial depth is 0.75 mm to strength of preparation wall, strength of composite and placement of retention groove
4. Axial wall should follow contour of the tooth.
5. Extent of outline form is dictated by the carious lesion extent.
6. Remove remaining carious lesion
7. Prepare retention groove (similar to Class III preparation)
8. Clean preparation.

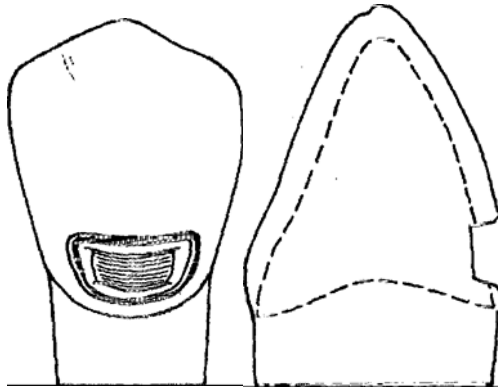


Bevelled Conventional Class V

- Indications

1. replacement of defective class V restorations
2. large carious lesion

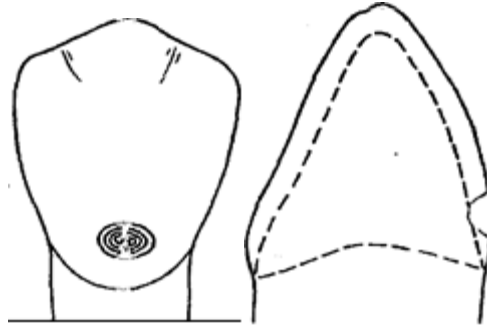
- Initially exhibits 90° cavosurface margins that subsequently beveled.
- axial wall depth is uniform (0.2mm or 0.5 when retention groove is to placed)



- groove is not indicated when periphery of tooth preparation is located in enamel.
- remove all infected dentin.
- clean preparation.

Modified Class V

- indicated for small and moderate lesion and lesion entirely in the enamel
- no effort to prepare a butt-joint
- no retention groove
- lesion is scooped out
- preparation has divergent wall
- axial wall does not have uniform depth
- prepare tooth with round or elliptical instrument
- preparation is extended initially no deeper than 0.2 mm
- no effort is made to prepare a 90 degree cavosurface margins.
- infected enamel is removed with a round bur or excavator.



Restorative Technique

1. Determine shade of tooth using shade guide
2. Clean the tooth preparation using slurry of pumice, polishing cup.
3. Isolate the tooth, preferably with a rubber dam or cotton rolls, to keep the prepared teeth from saliva, blood, debris and other fluids.
4. Protect adjacent unprepared tooth from the acid etchant with a polyester strip apply the wedge.
5. Apply the gel etchant 0.5 beyond the prepared margins onto the adjacent unprepared tooth.
6. Etchant is left for 15 seconds.
7. The area is washed to remove the etchant.
8. Dry the tooth structure
9. Bonding system is applied on all tooth structure that has been etched with a microbrush or other suitable applicators
10. the bonding agent then cured for 20 seconds.
11. Incrementally place composite material and cure. The thickness of each increment must not exceed 2mm.
12. **Curing of the Composite:** The material is cured using the light curing machine for 20 seconds for every increment of composite that was placed.
13. **Finishing and Polishing:** The use of polishers with enhancers and polishing paste were done after the trimming of the excess composites.