

Operative dentistry (Complex Amalgam Restorations)

د. شذی

Lec.11

Complex posterior amalgam restorations should be considered when large amounts of tooth structure are missing and when one or more cusps need capping.

Indications:

Complex amalgams can be used as:

- (1) Definitive final restorations.
- (2) Foundations.
- (3) Control restorations in teeth that have a questionable pulpal or periodontal prognosis.
- (4) Control restorations in teeth with acute or severe caries.

Contraindications:

The complex amalgam restoration might be contraindicated

- 1) If the patient has significant occlusal problems.
- 2) If the tooth cannot be restored properly with direct restoration because of anatomic or functional considerations (or both).
- 3) The complex amalgam restoration also might be contraindicated if the area to be restored has esthetic importance for the patient.

Resistance and Retention Form:

- In a tooth severely involved with caries or, any undermined enamel or weak tooth structure subject to fracture must be removed and restored.
- When conventional retention features are not adequate because of insufficient remaining tooth structure, pins, slots, and amalgam bonding techniques may be used to enhance retention.
- The retention features needed depend on the amount of tooth structure remaining and the tooth being restored. As more tooth structure is lost, more auxiliary retention is required.
- Pins, slots, and bonding also provide additional resistance form to the restoration.
- Capping cusps:
 - a) When caries is extensive, reduction of one or more of the cusps for capping may be indicated (capping cusps).
 - b) When the facial-lingual extension of the occlusal preparation exceeds two third the distance between the facial and lingual cusp tips (inter-cuspal-distance), reduction of the cusp(s) for amalgam is usually required for the development of adequate resistance form.
 - c) The reduction should be 2mm as minimum depth on the occlusal surface of each cusp to be capped using the side of carbide fissure bur, to ensure that the final restoration has restored cusps with a minimal thickness of 2 mm of amalgam
 - d) The occlusal contour of the reduced cusp should be similar to the normal contour of the unreduced cusp. Any sharp internal corners of the tooth preparation formed should be rounded to reduce stress concentration in the amalgam and thus improve its resistance to fracture from occlusal forces.

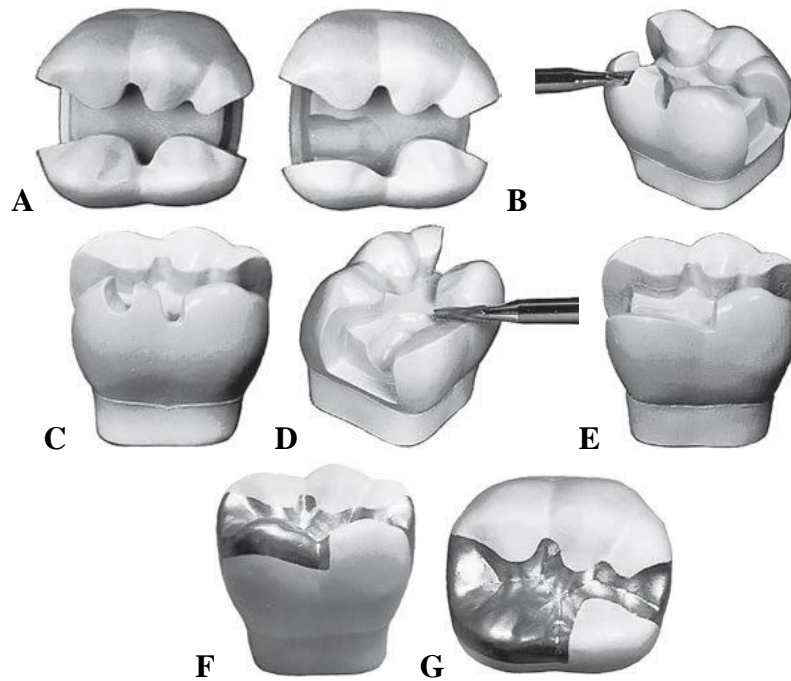


FIG. (1) Capping cusp with amalgam. A, Comparison of mesial aspects of normally extended (left) and extensive (right) mesioocclusodistal tooth preparation. Note that the resistance form of the mesiolingual cusp of extensive preparation is compromised and indicated for capping with malgam. B, Preparing depth cuts. C, Depth cuts prepared. D, Reducing cusp. E, Cusp reduced. F and G, Final restoration.

When possible, opposing vertical walls should be prepared to be converge occlusally, to enhance primary retention form. The pulpal and gingival walls should be relatively flat and perpendicular to the long axis of the tooth.

Secondary retention means:

Cusp reduction significantly diminishes retention form by decreasing the height of the vertical walls, so secondary retention means are required which may include:

1- **Coves and locks:** Coves are prepared in a horizontal plane and locks are prepared in a vertical plane. These locks and coves should be prepared before preparing pinholes and inserting pins. (see fig. 2 A&C)

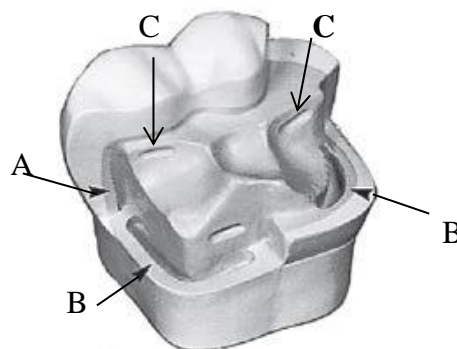


Fig. 2 Locks (A), slots (B), and coves (C).

2- Slots: which may be prepared along the gingival floor, or in addition to, pinholes (as appear in fig. 2 B).
The slot should be prepared 0.5 mm pulpal to the dentino-enamel junction and at least 0.5 mm in depth.

3- Pins: Pins placed into prepared pinholes provide auxiliary resistance and retention forms.

PIN RETAINED AMALGAM RESTORATION:

It's any filling may needs one or more pins to provide adequate resistance and retention forms.

Advantages:

- 1- Conservative; means the pin is more conservative in tooth cutting than slot and crown preparation.
- 2- Time value: Pined amalgam needs only one visit; the cast may needs two visits.
- 3- Resistance and retention are better by using pins.
- 4- More economic than cast.

Disadvantages:

- 1- It's difficult to penetrate when there is little dentin left.
- 2- Stress induced into tooth structure.
- 3- Perforation may occur to the pulp or to the external tooth surface.
- 4- Requires at least 4 mm's of occlusal clearance.

Types of pins:

1. Self threading pins: The pin is retained by threads on pin surface through engaging the dentin when it's inserted. It is the most retentive type of pins and also it is the most widely used than the other types. However, vertical and horizontal stresses can be generated in the dentin when a self-threading pin is inserted causing craze lines in the dentin which are related to the size of the pin. The diameter of pin hole is 0.1 mm smaller than pin diameter. The elasticity of dentin allows the insertion of pin into a hole of smaller diameter. The depth of pin hole is about 1.5-2mm. (Fig 3' C)

2. Cemented pins: Its threaded or serrated stainless steel pins cemented into pin holes 0.05mm larger than the diameter of the pin. The cement used may be any standard dental luting agent such as Zinc phosphate or polycarboxylate cement. The cemented pins produce less stresses in the dentin. The depth of pin hole should be 3 mm. (Fig 3, A)

3. Friction-locked pin: The diameter of the prepared pin hole is 0.025 mm less than diameter of the pin ; the pin is tapped in place retained by resiliency of dentin; Its 2-3 time more retentive than cemented pins; its inserted by specially designed instrument.(Fig 3, B)

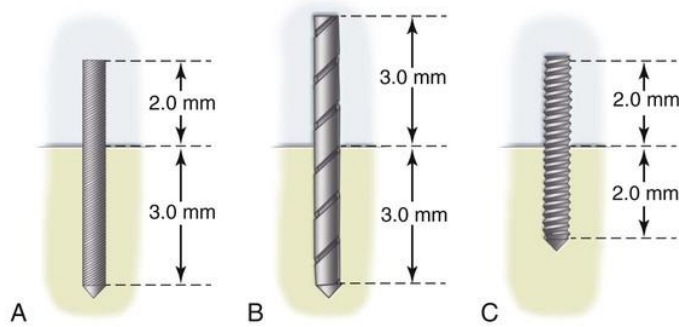


FIG. 3 Three types of pins. A, Cemented. B, Friction-locked. C, Self threading.

Factors Affecting the Retention of the Pin in Dentin and Amalgam:

1- Type of pin: The self-threading pin is the most retentive, the friction locked pin is intermediate, and the cemented pin the least retentive.

2- Surface characteristics: The number and depth of the elevations (serrations or threads) on the pin influence retention of the pin in the amalgam restoration. The shape of the self-threading pin gives it the greatest retention value.

3- Orientation, number, and diameter: Retention provided by placing the pins in a non parallel manner; also excessive bending of pins to improve retention in amalgam is not desirable, because bending interfere with the adequate condensation of amalgam around the pin, also bending may weakens the pins. Pins should be bent only to provide an adequate amount of amalgam (approximately 1 mm,) between the pin and the external surface of the finished restoration.

4-Extension of pin into amalgam and dentin: The extension of pin into dentin and amalgam greater than 2 mm is unnecessary for pin retention and is contraindicated to preserve the strength of the dentin and the amalgam. (Fig.3)

Pin Placement Factors and Techniques:

1- Pin size: Two determining factors for selecting the appropriate pin size are the amount of dentin available to safely receive the pin, and the amount of retention desired. In the Thread Mate System (TMS) four sizes of pins are available (from the largest size to smaller size: Regular, Minim, Minikin and Minuta).The Minikin pins usually the pins of choice for severely involved posterior teeth to reduce the risk of dentin crazing, pulpal penetration, and potential perforation. The Minim pins usually are used as a backup in cases where the pinhole for the Minikin was over prepared. The Regular or largest diameter pin is rarely used because a significant amount of stress in the tooth (dentin and enamel) may be created during its insertion. The Minuta pin is usually too small to provide adequate retention in posterior teeth so this pin can be benefit for providing retention for anterior teeth restorations.

2- Number of pins:

- a- As a rule one pin per cusp or marginal ridge.
- b- The fewest pins possible should be used to achieve the desired retention for a given restoration.
- c- If more than one pin is used, 3-5 mm space between pins is required.
- d- As the number of pins increases the retention of the restoration increases, while an excessive number of pins can fracture the tooth and significantly weaken the amalgam restoration.

3- Location:

- a- Occlusal clearance should be sufficient to provide 2 mm of amalgam over the pin.
- b- Pinholes should be located halfway between the pulp and the DEJ or external surface of the tooth root. The pinhole should be positioned no closer than 0.5 to 1 mm to the DEJ or no closer than 1 to 1.5 mm to the external surface of the tooth. (See Fig. 4)
- c- The pinhole should be parallel to the adjacent external surface of the tooth.
- d- A minimum space of 0.5 mm is required around the circumference of the pin for adequate condensation of amalgam.
- e- Pinholes should be prepared on a flat surface that is perpendicular to the proposed direction of the pinhole.

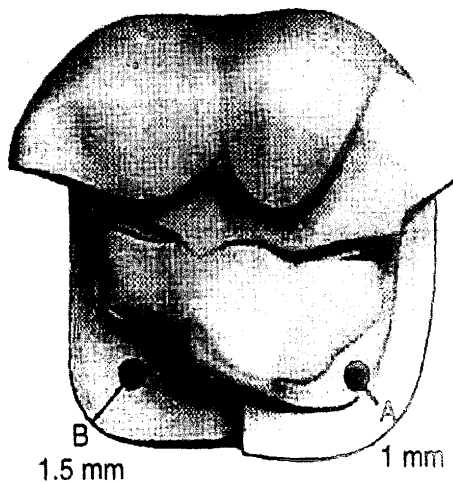


Fig. 4 Pinhole position. A, Position relative to DEJ.

B, Position relative to external tooth surface.

f- Several posterior teeth have anatomic features that may preclude safe pinhole placement. External perforation may result from pinhole placement on these areas:

- i- Over the prominent mesial concavity of the maxillary first premolar.

- ii- Over bifurcation areas of the lower molars and trifurcation areas of the upper molars.
- iii- The distal aspect of mandibular molars and the lingual aspect of maxillary molars because of root angulations of these teeth just apical to CEJ.
- iv- Teeth that are rotated in the arch.
- v- Abnormal tilted teeth. (See Fig 6)

Pinhole preparation:

- 1- The drill is a twist drill made of aluminum shank, which acts as a heat absorber, and is color coded so that it can be easily matched with the appropriate pin size. A drill with limited depth of 2mm should be used to prepare the hole.
- 2- When the pinhole locations have been determined, a No. 1/4 round bur is first used to prepare a hole. The purpose of this hole is to permit more accurate placement of the twist drill and to prevent the drill from "crawling" once it has begun to rotate.
- 3- Put the handpiece on clockwise rotation at very low speed 1300 to 500 rpm).
- 4- Prepare the hole parallel to nearest external tooth surface. Align twist drill with external tooth surface. Drill the hole in one continuous motion until the depth is reached then pulls the drill without stopping the rotation to prevent breaking of the drill while it's in the hole. (See fig. 5)

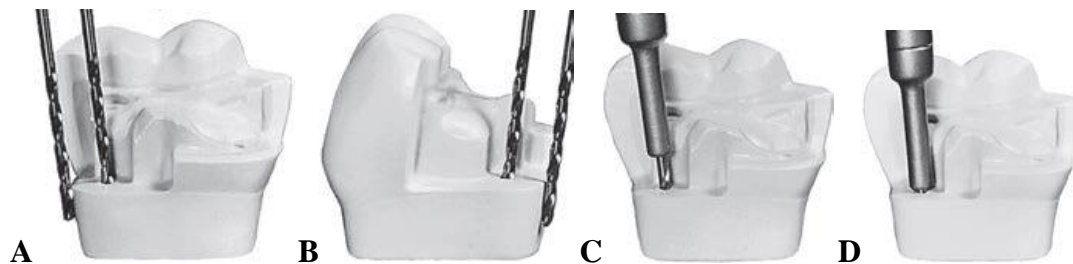


Fig 5: Determining the angulation for the twist drill. A, Drill placed in the gingival crevice, positioned flat against the tooth, and moved occlusally into position without changing the angulation obtained. B, A repeated while viewing the drill from position 90 degrees left or right of that viewed in A. C and D, With twist drill at correct angulation, the pinhole is prepared in one or two thrusts until the depth-limiting portion of drill is reached.

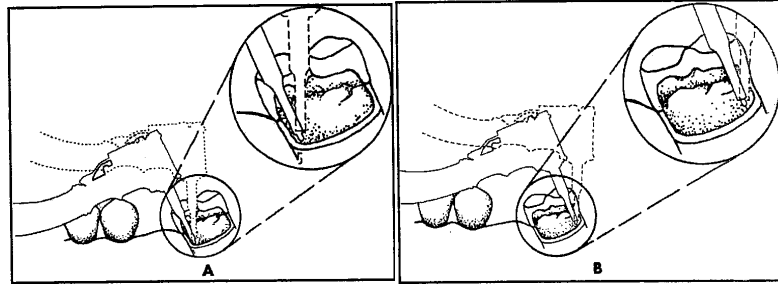


Fig. (6) Care must be exercised when preparing pinholes in mesially tilted annoiars prevent external perforation on mesial surface (A) and pulpal penetration on the distal surface (B). Broken line is incorrect angulation of twist drill.

Pin design:

For each of the four sizes of pins, several designs are available: standard, self-shearing, two-in one, Link Series, and Link Plus (Fig. 7). The Link Series and Link Plus pins are recommended. TMS pins are available in titanium or stainless steel plated with gold.

When the pin reaches the bottom of the hole, the top portion of the pin shears off, leaving a length of pin extending from the dentin.

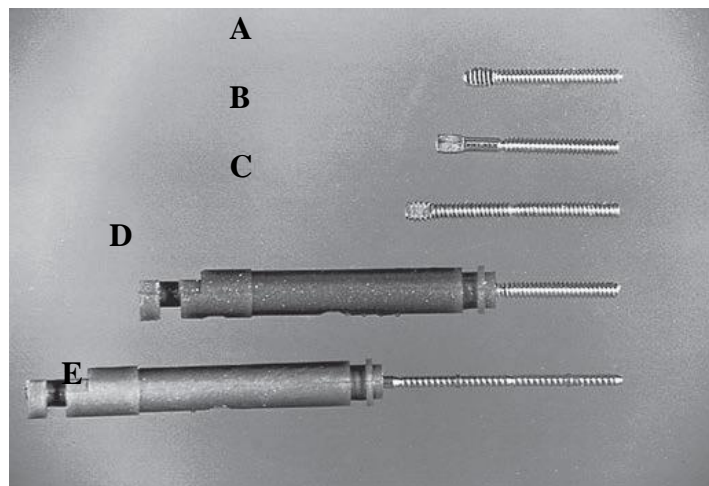


Fig7: Five designs of the Thread Mate System (TMS) pins. A, Standard. B, Self-shearing. C, Two-in-one. D, Link Series. E, Link Plus.




Fig 8: Hand wrenches for the Thread Mate System (TMS) pins. A, Regular and Minikin. B, Minim. C, Minuta. D, Link Series and Link Plus




Fig9: Handpiece chucks for

(A) TMS regular self-shearing and Minikin pins, and (B) TMS Minuta pins

Notes:

When pin is placed in the pin hole, the pin should not exceed 2 mm in length in the amalgam, if the length is more than that, the excess should be cut. It is desired to have at least 2 mm of thickness of the amalgam occlusal to the end of the pin to prevent weakening of the restoration.

Possible Problems with Pins:

1-Failure of pin-retained restorations: The failure of pin retained restorations might occur at any of five different locations (Fig. 10). Failure can occur:

- a- Within the restoration (restoration fracture).
- b- At the interface between the pin and the restorative material (pin-restoration separation).
- c- Within the pin (pin fracture).
- d- At the interface between the pin and the dentin (pin-dentin separation).
- e- Within the dentin (dentin fracture).

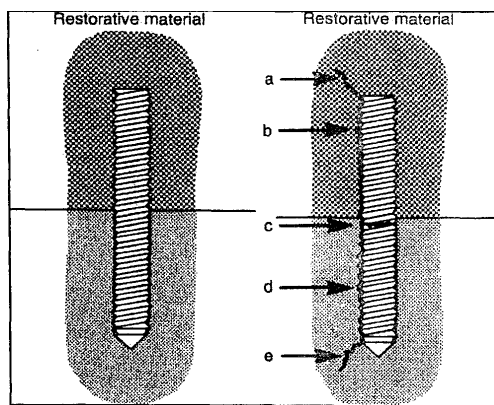


Fig (10) Five possible locations of failure of pin-retained restorations. a, Fracture of restorative material;b, Separation of pin from restorative material; c, Fracture of pin;d, Separation of pin from dentin; e, Fracture of dentin.

2-Broken drills and broken pins: A twist drill will break if it is stressed laterally or allowed to stop rotating before being removed from the pinhole. Pins also may break during bending, if care is not exercised. The treatment for both broken drills and broken pins is to choose an alternate location, at least 1.5 mm away from the broken item, and prepare another pinhole.

3-Loose pins: The pin should be removed from the tooth and the pinhole re-prepared with the next largest size drill, and the appropriate pin inserted. Preparing another pinhole of the same size 1.5 mm from the original pinhole also is acceptable.

4- Penetration into the pulp and perforation of the external tooth surface:

It is obvious if there is hemorrhage in the pinhole following removal of the drill, also the operator can feel when a penetration or perforation has occurred by an abrupt loss of resistance of the drill to hand pressure. In an asymptomatic tooth, a pulpal penetration is treated as any other small mechanical exposure by control the hemorrhage, then place a calcium hydroxide liner over the opening of the pinhole, and prepare another hole 1.5 to 2 mm away. Perforation of the external surface of the tooth can occur occlusal or apical to the gingival attachment. When the perforations occur occlusal to the gingival attachment, the pin can be cut off flush with the tooth surface and no further treatment. Or the pin can be removed, if still present, and the external aspect of the pinhole enlarged slightly and restored with amalgam. If the perforations occur apical to the attachment, reflect the tissue surgically, remove the necessary bone, enlarge the pinhole slightly, and restore with amalgam.

FAILURE OF AMALGAM RESTORATION:

The failure of amalgam restoration may include:

1- Secondary caries: Class I and Class I I amalgam restorations, caries around margins was the predominant cause of restoration failure. Also amalgam restoration in high caries incidence individuals may fail as a result of secondary caries.

2- Isthmus fractures or marginal ridge fracture of restoration: the marginal ridge fracture in CI II restoration may be caused by:

- a- Axio-pulpal line angle not rounded in class II cavity.
- b- Marginal ridge left too high.
- c- Improper removal of the matrix.

3- Tooth fractures: Excessive tooth cutting or excessive caries, may resulted in large cavity with thin walls that cannot withstand occlusal forces, and will cause tooth fracture. Also sharp internal line angles may cause stress concentration of the restoration on the tooth walls and lead to fracture.

4- Improper marginal adaptation and marginal fractures: Marginal deterioration of amalgam restorations are mainly caused by the following factors:

- a- Improper marginal preparation.
- b- Improper carving and finishing. `
- c- Excess mercury.
- d- Use of low copper amalgam.
- e- Amalgam expansion.

5- Other reasons: these includes faults in the clinical procedures during amalgam placement such as: gingival overhang of the restoration (due to not or improper using of the wedge), improper contact area with the adjacent tooth which will lead to periodontal problems.