Non odontogenic cyst (fissural)

These types of cysts named as fissural cysts because they arise from

epithelium entrapped along embryonic lines of fusion.

Also called (Inclusion cysts)

1-Naso-palatin duct cyst (= incisive canal cyst):

Most common non-odontogenic cyst of oral cavity involve 1% of population.

Arise from remnant of *nasopalatine duct (emberionic structure which connecting the oral & nasal cavities in area of incisive canal),* spontaneous cystic degeneration of this remnant lead to cyst formation.

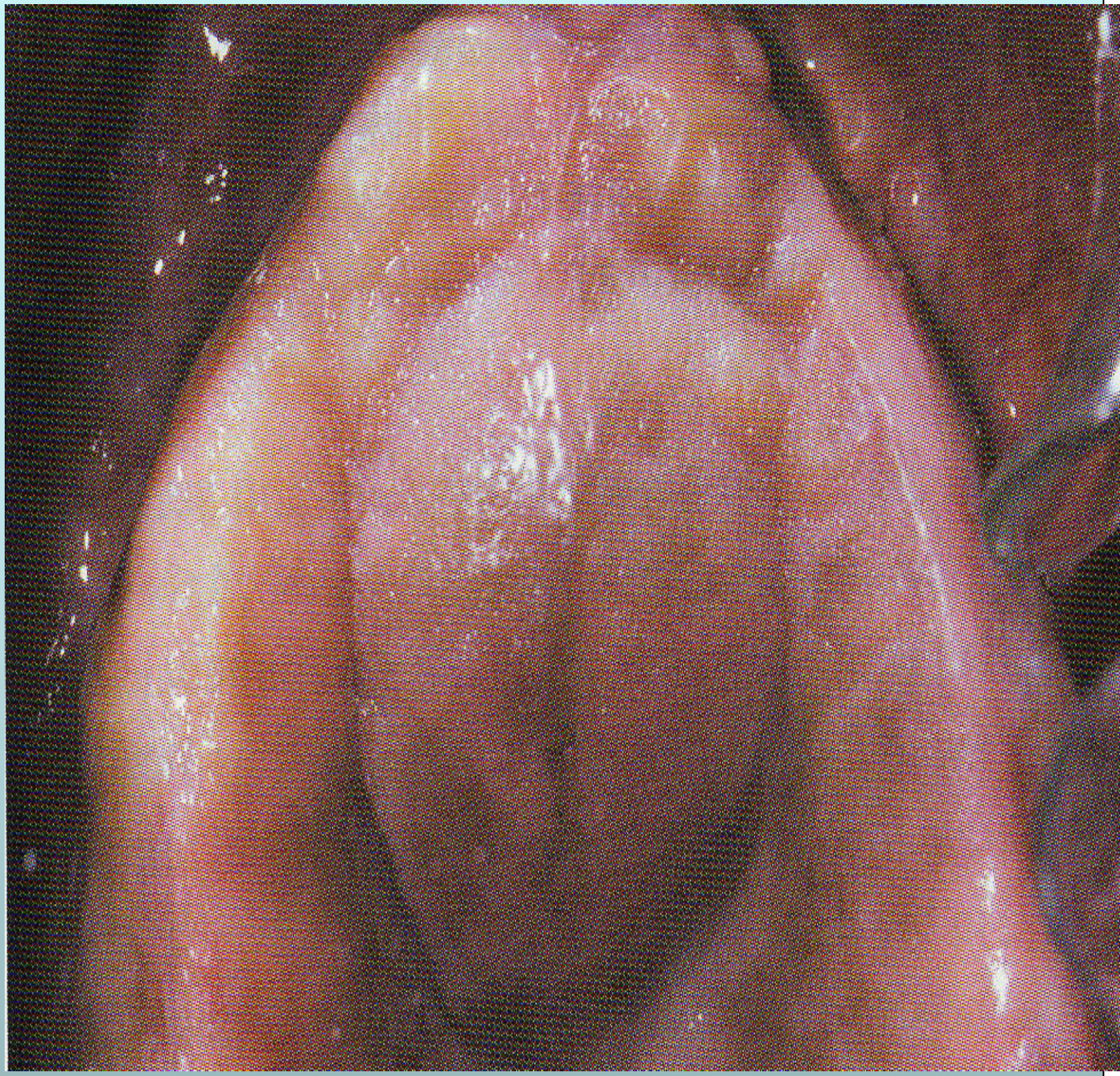

Clinically:-

-Asymptomatic swelling in the midline of anterior palate (discovered by a routine radiograph), salty taste which discharged in the mouth.

-Pain occur due to secondary inflammation of the cyst.

-Occur at age 5th and 6th decade of life, more in males.

Radio graphically :-

-Well circumscribed radiolucency (round, oval, heart- shape) with a sclerotic border, near the midline of anterior maxilla, between & apical to the central incisors.

- Distinction between small nasopalatine duct cyst and a large incisive foramina is difficult ,(6mm wide is the upper limit of normal size of incisive foramen).

Histopathology :-

- Cyst lined by different type of epithelium ;stratified squamous epithelium, pseudostratified ciliated columnar (respiratory epith.) often containing mucous cells, cuboidal epi. or columnar ,,may be seen alone or in any combination.
- Cyst capsule,is a fibrous C.T exhibiting component of blood vessels and nerves (terminal branches of long sphenopalatin nerve &vessel) .This help in the diagnosis.
- Occasionally ,small mucous gland (salivary type) may be seen in the cyst wall.

Treatment :-

Surgical enucleation,

no recurrence.


14

2- Naso- labial cyst (naso– alveolar cyst) :

** Clinically :-*

-Rare, present as slowly enlarging soft tissue swelling of upper lip, just below ala of the nose, lateral to the midline, resulting in elevation of the ala of the nose and sometime obliterating nasolabial fold leading to nasal obstruction.

- It may be bilaterally
- Age occurrence usually at 4th decade & over 75% occur in female.

* *Radiographically :-*

None (because its origin in soft tissue).

* *Histopathology :-*

-Cyst lined by pseudostratified columnar ciliated epith. with goblet cells (=mucus production),or by a ductal type cuboidal epith.

- Fibrous C.T wall.

•Etiology :-

Unknown may be arise from remnant of lower part of embryonic nasolacrimal duct (because has some location & histology)

* *Treatment :-*

Enucleation , no recurrence.

3- Median cyst

- -**Median cyst of the palate:**
  May represents a displaced nasopalatine duct cyst.It derived from epithelia entrapped along the emberyonic line of fusion of the lateral palatine shelves of the maxilla. It appear as a well circumscribed R.L in the midline of the hard palate.

-Median cyst of the mandible:

Most likely to be odontogenic in origin. Occur in the midline of the mandible,between & apical to the mandibular central incisors with cortical expansion. It is developed from epithelia entrapped during fusion of the two halves of the mandible during emberyonic life.

4- Globulomaxillary cyst

- **Rare, asymptomatic, appear as a well-defined R.L often producing divergence of the roots of the maxillary lateral incisor & canine teeth**

5- Palatal cyst of newborn (Epestein's pearls)

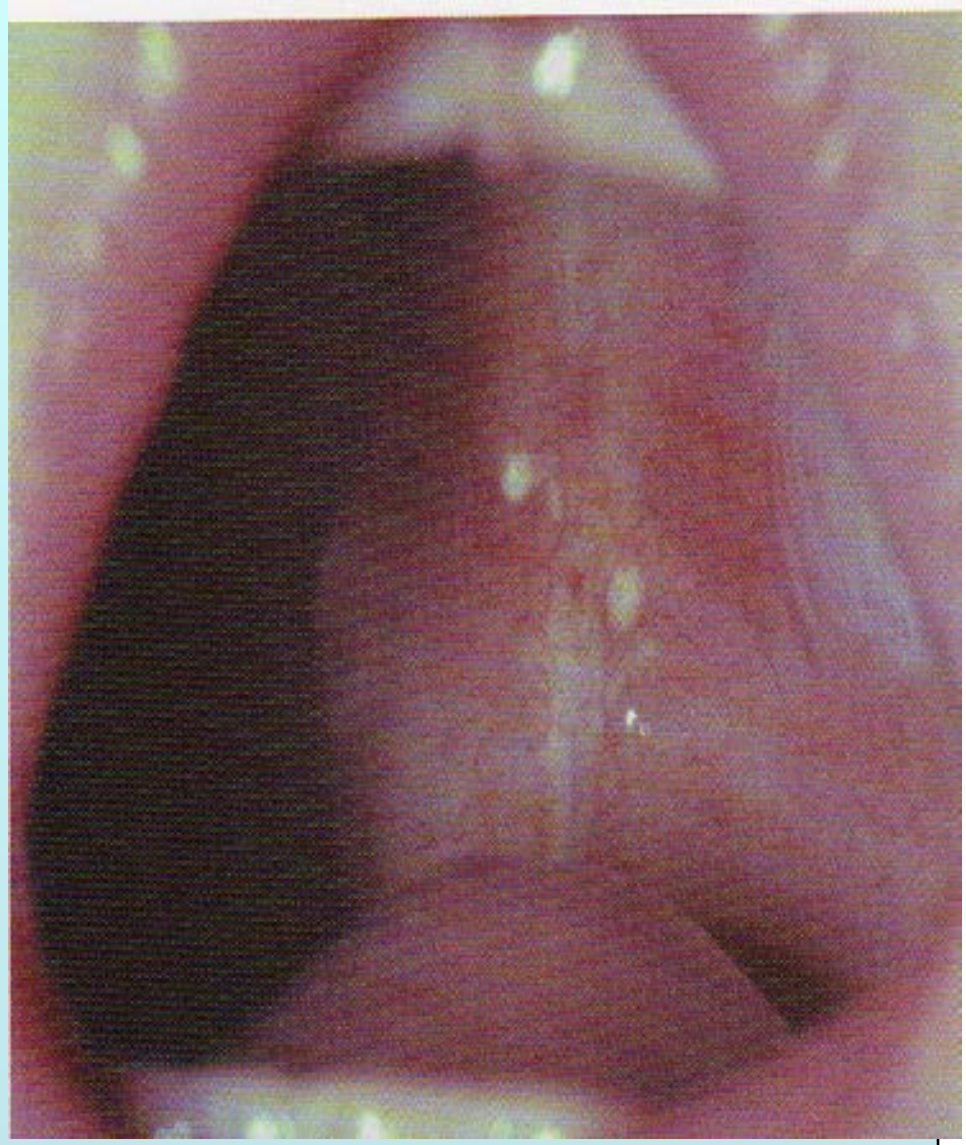

Epstein pearls are cystic keratin-filled nodules found along the midpalatine raphe and are thought to be derived from entrapped epithelial remnants along the line of fusion of the palatine shelves.

Bohn's nodules:- Cystic keratin filled nodules scattered near the junction of hard & soft palate,in infant, resolved without treatment

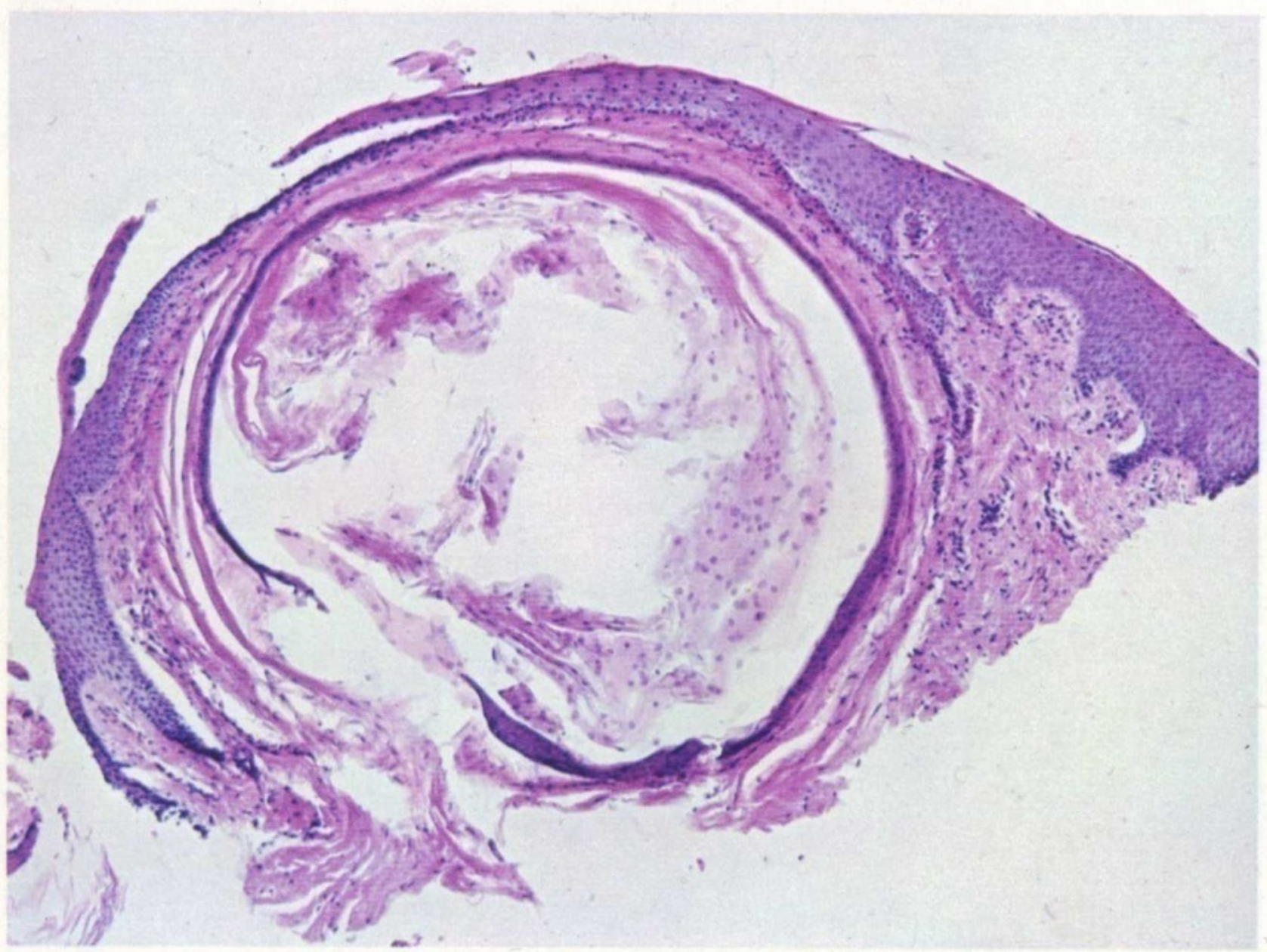

Fig. 114. Gingival cyst ("Epstein's pearls") in gingival mucosa of new-born x 50

II-Non epith. primary bone cyst :-

Mostly occur in long bone, occasionally seen in the jaws, mainly in the mandible.

1-Solitary bone cyst :

-Variety of terms; simple bone cyst, hemorrhagic or traumatic bone cyst.

-Mainly in children and young adult ,peak incidence 2nd decade. -

-Male predominance, asymptomatic (chance radiographical finding)

-In premolar and molar region of mandible (rare in maxilla).

Radio graphically :-

-Radiolucent area of variable size , irregular outline (scalloped) specially around and between the roots of standing teeth.

-Well- defined margin.

Histopathology :-

-No epi. lining (pseudo cyst)

-Fibrous C.T with chronic inflammatory cells lining the bone cavity.

-Empty or fluid filled cavity (clear or blood stained).

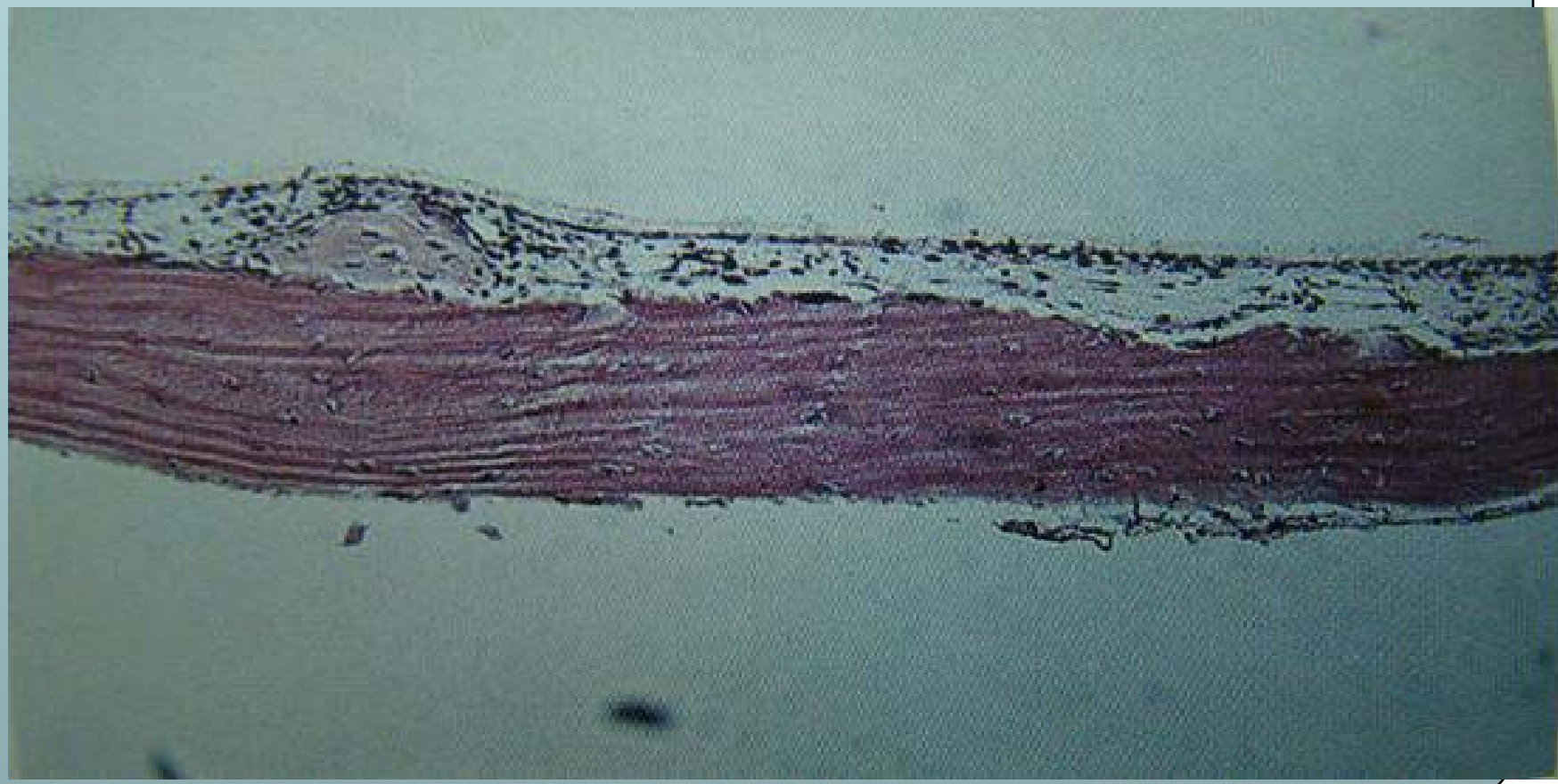

pathogenesis :-

- Uncertain, 50% due to trauma.

- **Trauma lead to intramedullary hemorrhage, which for unknown reason fails to organized,& so that cavitations occur by subsequent hemolysis & resorption of the clot**
-

Treatment :-

-Surgical opening and curettage.

- Good prognosis .

- No recurrence.

2- Aneurysmal bone cyst :-

** Clinically :-*

-Rare in jaws .

- Arise in posterior part of the body or at angle of the mandible.

-Mostly affect children and young adult (10- 20 years).

- Appear as a firm swelling causing facial deformity and may be associated with pain.

Radio graphically :-

Multilocular radiolucency with a characteristics ballooned- out appearance due to gross cortical expansion [=expansile soap –bubble radiolucency].

* *Histopathology :-*

-Lesion composed of numerous, non – endothelial lined blood filled spaces of varying size separated by cellular fibrous tissue.

- Multinucleated giant cells, & evidence of old and recent hemorrhage in fibrous septa.

* *pathogenesis :-*

Unknown . It is thought that the primary lesion initiate a vascular malformation , leading to hemodynamic disturbance in the medullary bone ,resulting in the development of this cyst. There may be a history of trauma.

Recently the most commonly accepted idea was that aneurysmal bone cyst was the consequence of an increased venous pressure and resultant dilation and rupture of the local vascular network. Primary etiology has been regarded arteriovenous fistula within bone.[2]

**Treatment:-*

-Curettage, sometimes with cryosurgery.

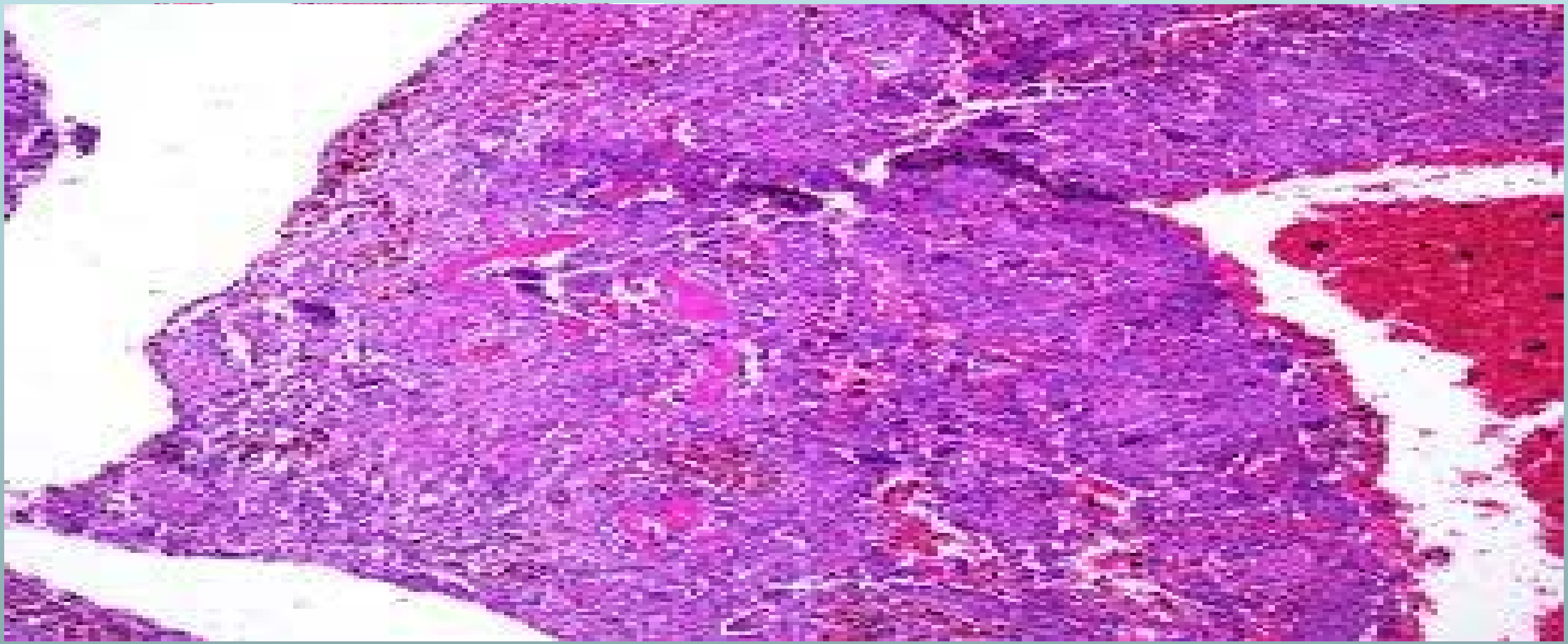

3-Stafne's idiopathic bone cavity :-

- ***Stafne's defect, stafne's bone cyst, lingual mandibular salivary gland depression, static bone cyst***

- **Uncommon developmental anomaly of mandible mistaken as a cyst on radiograph.**

- **Symptomless, chance radiographic finding, round or oval, well- demarcated radiolucency between the premolar region and angle of jaw on lingual aspect of mandible, below the inferior dental canal.**

- **Occasionally bilateral**

- **It contains ectopic salivary tissue in continuity with submandibular salivary gland.**

- **Sialograph (radio-opaque material injection) useful in identifying such salivary tissue inclusion (=to confirm the salivary gland nature of this entity)**

-No treatment.

Cysts of Soft tissue :-

- Cysts of oral soft tissue are uncommon.
- Mainly non- odontogenic in origin.
- Gingival cyst and nasolabial cyst **(soft tissue)** but traditionally grouped with cyst of the jaw.

- **Main type oral soft tissue cysts (including cyst of neck) :-**

1- Salivary mucocele

a- **Extravasations mucocele**

(mucous extravasations cyst)

- arise in lower lip, bluish, translucent sub mucosal swelling, due to extravasations of mucous from a ruptured duct.

b- **Retention mucocele** (mucous retention cyst)

90% of the cases are of mucous extravasation type.

2- Dermiod and epidermiod cyst :-

- Developmental lesions, occur at a variety of sites in head and neck including the floor of the mouth. May present as intraoral or sub mental swellings.
- Cyst lined by orthokeratinized stratified squamorus epi (as epidermis). Lumen filled with keratin. The wall is composed of fibrous C.T that contain skin appendages (hair follicles, sebaceous glands, sweat gland).
- In the absence of skin appendages, the cyst is termed as Epidermoid cyst

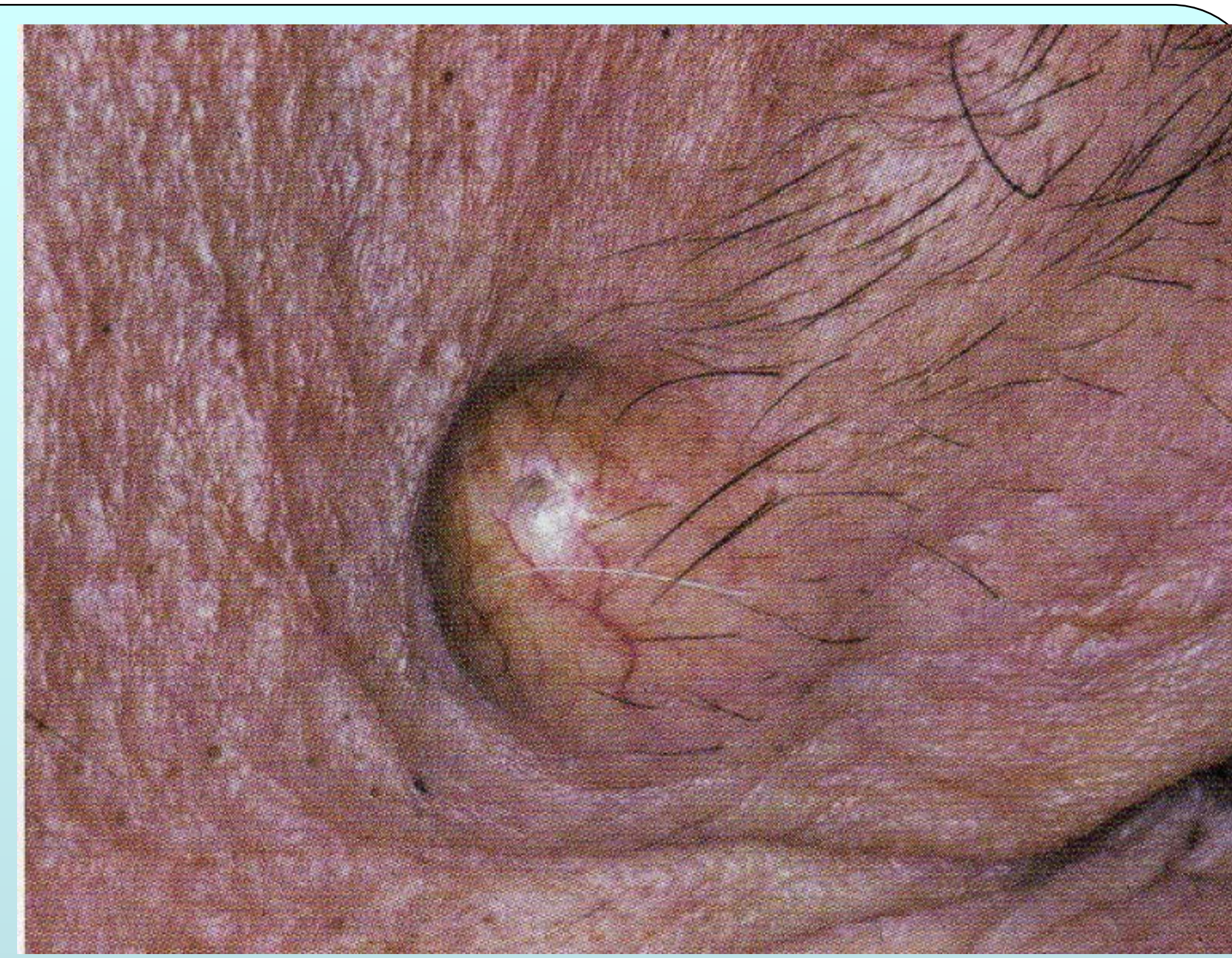

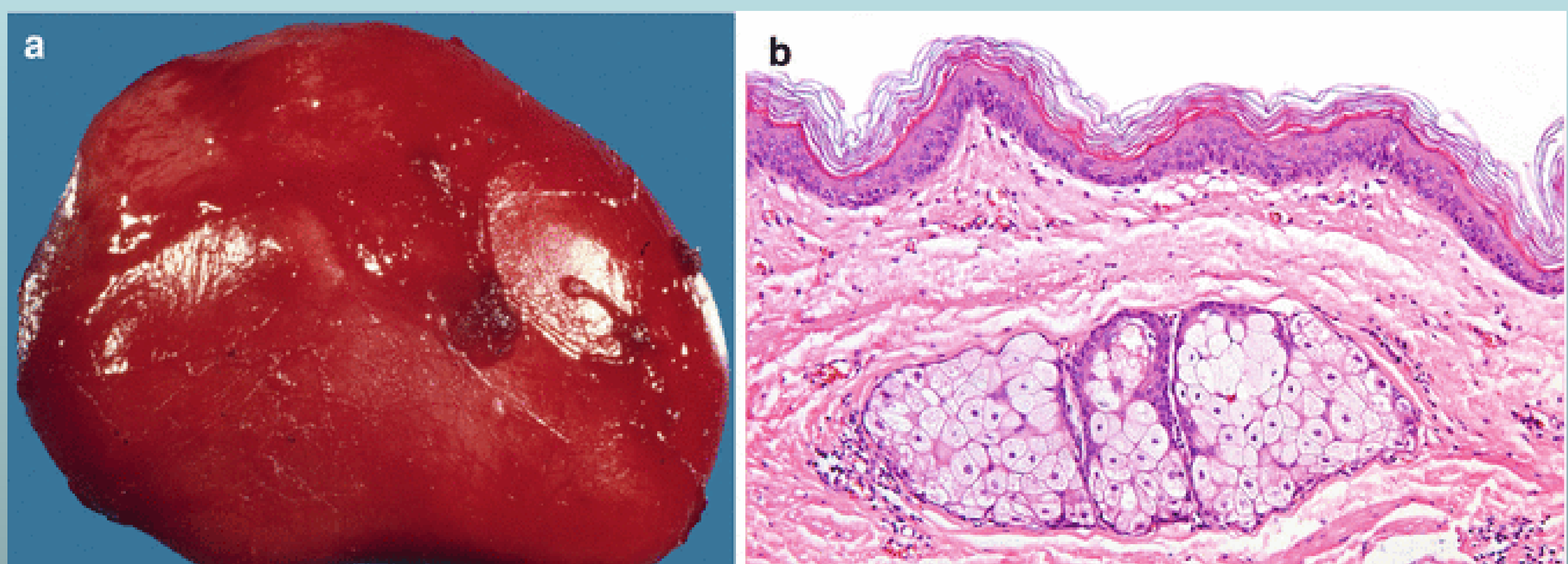
a
b

2) Dermoid cyst

- Above the Geniohyoid Muscle

↓

Tongue displaced toward the roof of the mouth (difficulty swollowing)

3- lymphoepithelial cyst (=branchial cyst):-

- Occur deep to the sternomastoid muscle or along its anterior border, at level of the angle of the mandible.
- Uncomon in oral cavity.
-Cyst lined by stratified squamous epith, wall contains well- organized lymphoid tissue.
- Derived from the remnant of branchial arches or pharyngeal pouches, or may arise from
- salivary gland epith that
- become entrapped by
- lymphoid tissue.

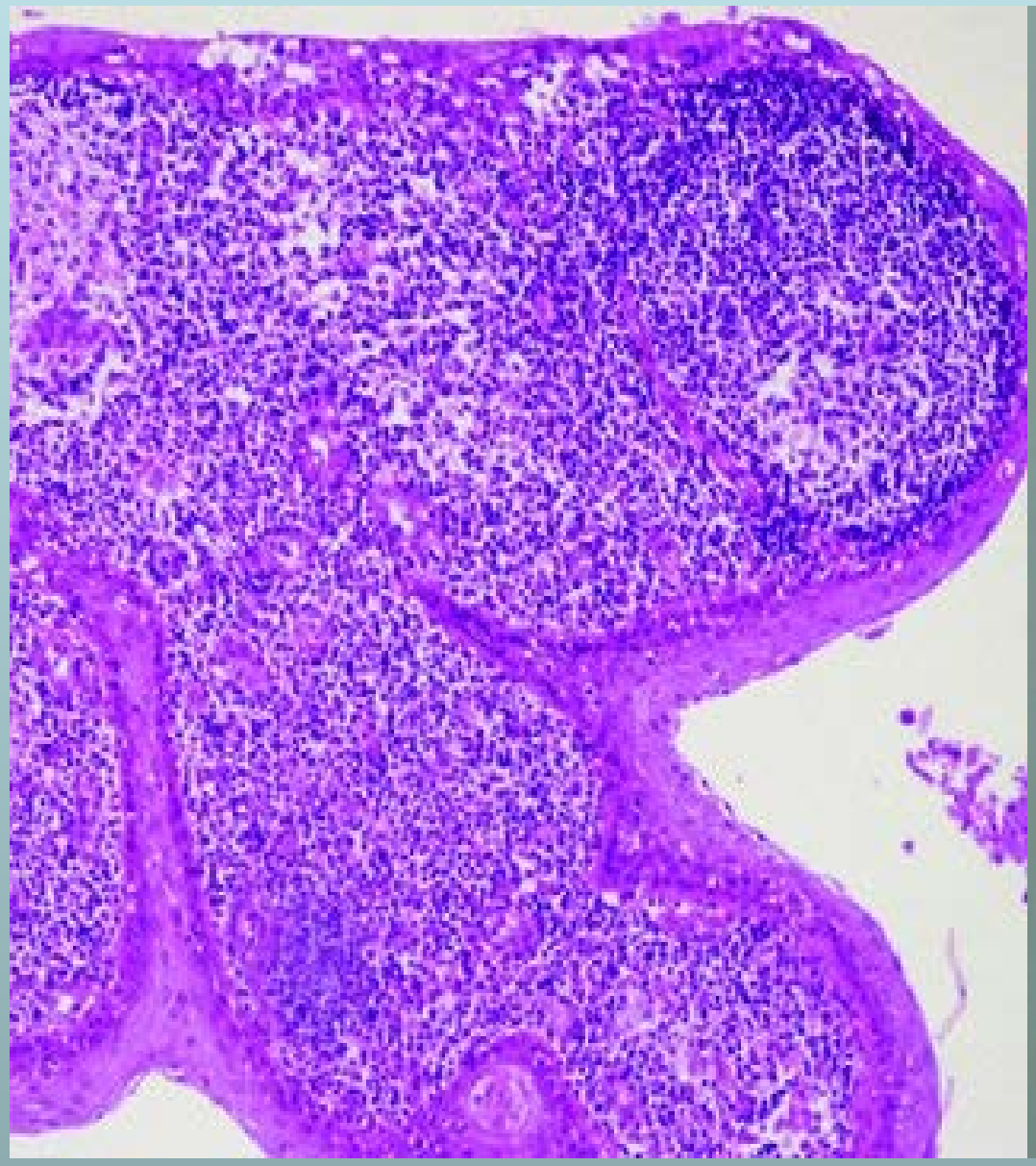

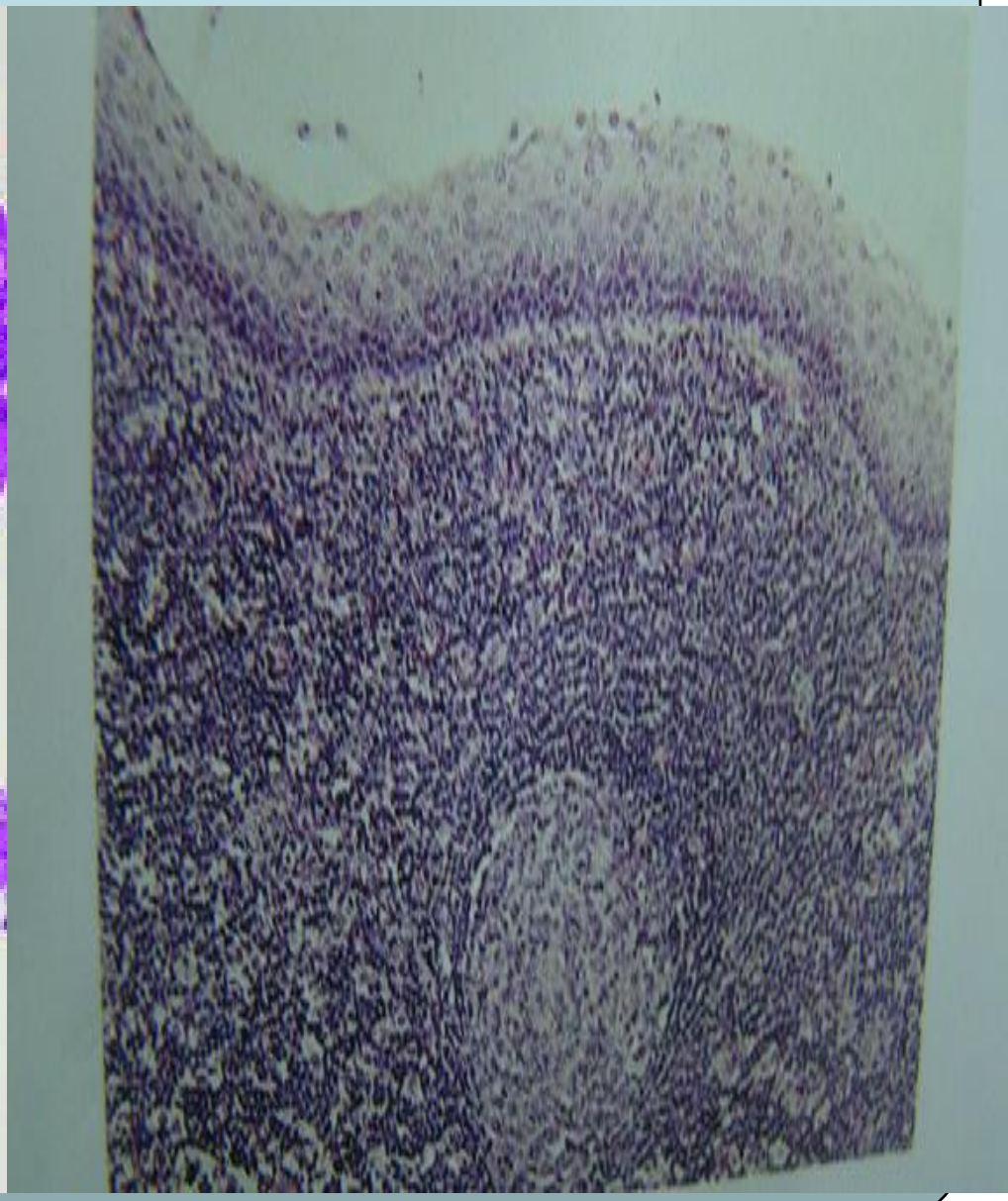


Differential Dx: Lymphoepithelial Cyst
Caution! This cyst looks similar but remains small; usually on lateral tongue
Cyst on right lateral tongue.
© Photo: Dr. Jerry Bouquot, The Maxillofacial Center, Morgantown, West Virginia

4- Thyroglossal cyst :-

- Developmental lesion derived from residue of the embryonic thyroglossal duct.
- May occur anywhere-in the mid line- from foramen ceacum area of the tongue to the substernal notch.
- Mostly arise in the region of hyoid bone ,rare intraorally.
- Lesions develop at the base of the tongue may cause larangeal obstruction.
- Cyst lined by stratified squamous epith. capsule contain thyroid tissue (thyroid follicle and thyroglobulin).
- It moves vertically during the protrusion of the tongue.
- Fistulous tract to the skin may occur.

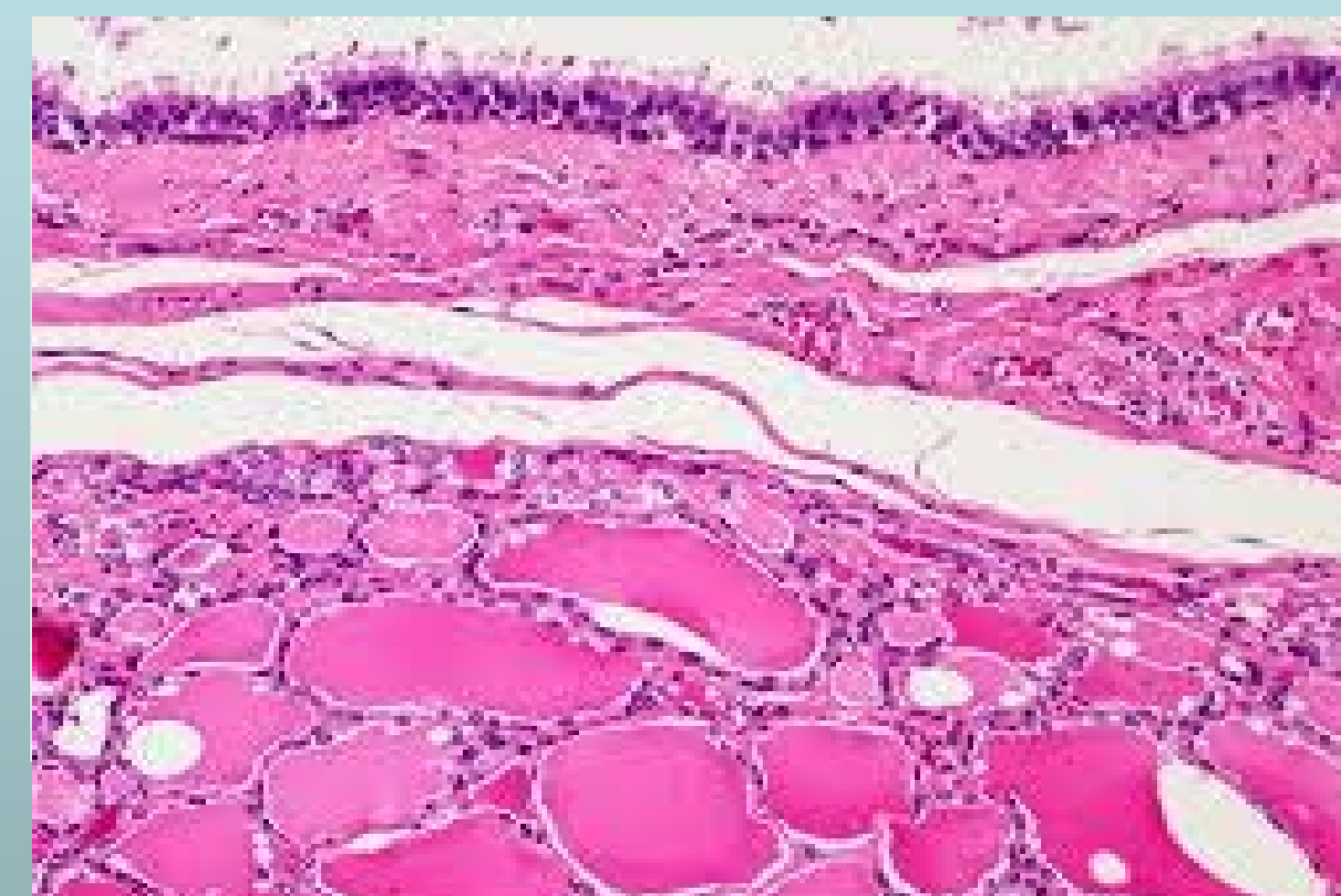

Thyroglossal duct cyst
thyroid follicles under ciliated epithelium (H&E, high power)

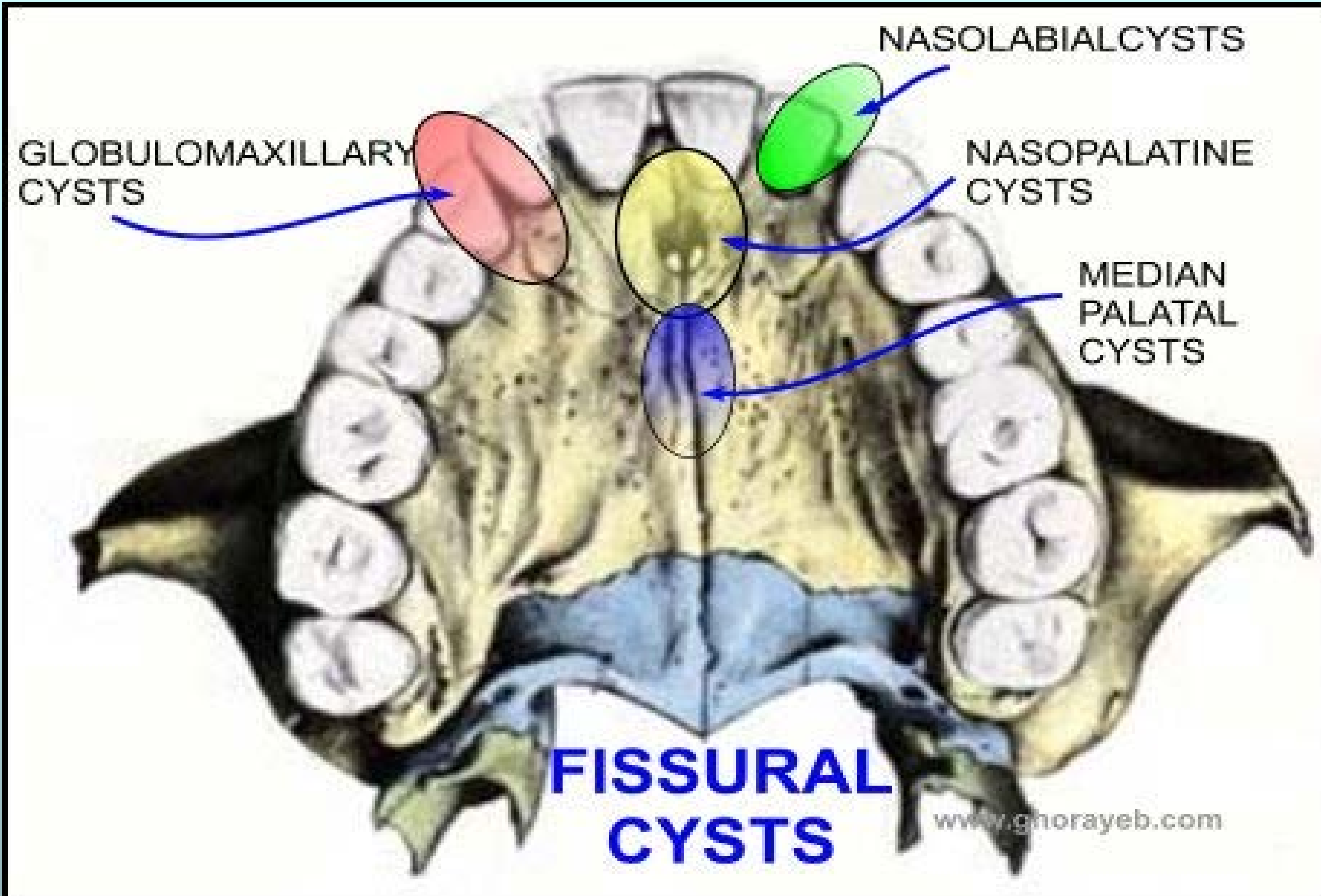
NASOLABIALCYSTS
GLOBULOMAXILLARY
CYSTS
NASOPALATINE
CYSTS
MEDIAN
PALATAL
CYSTS
FISSURAL
CYSTS
www.ghorayeb.com