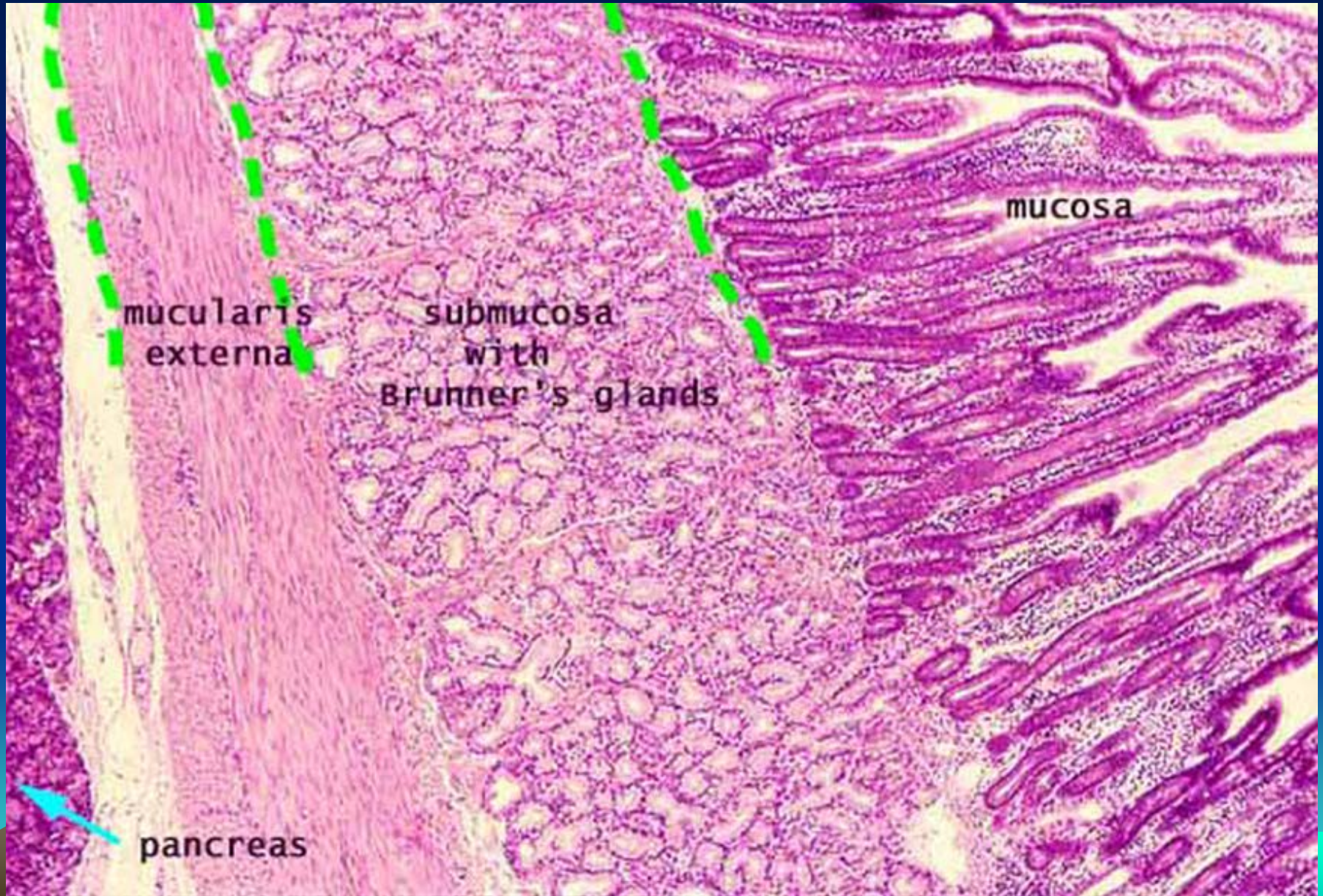
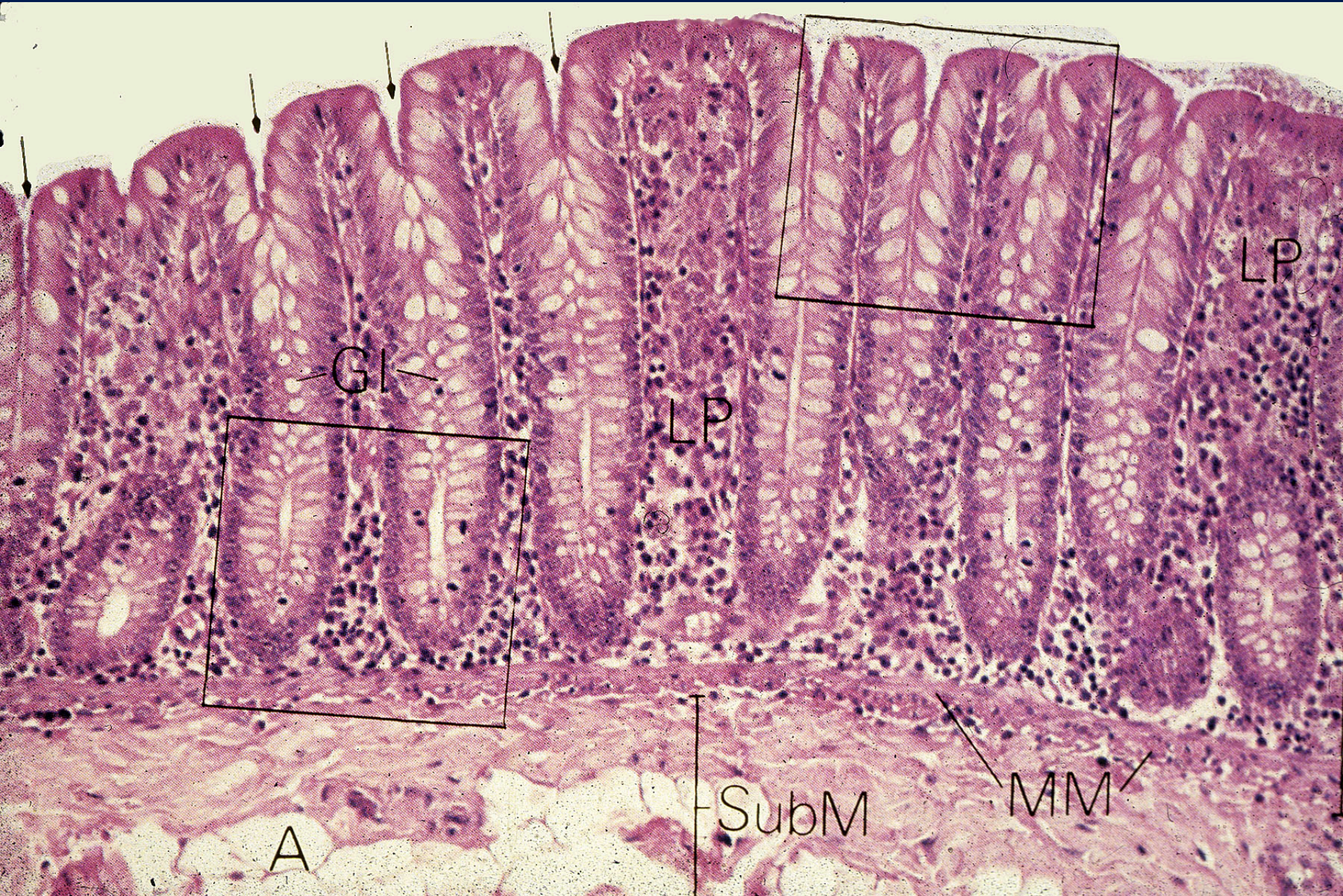
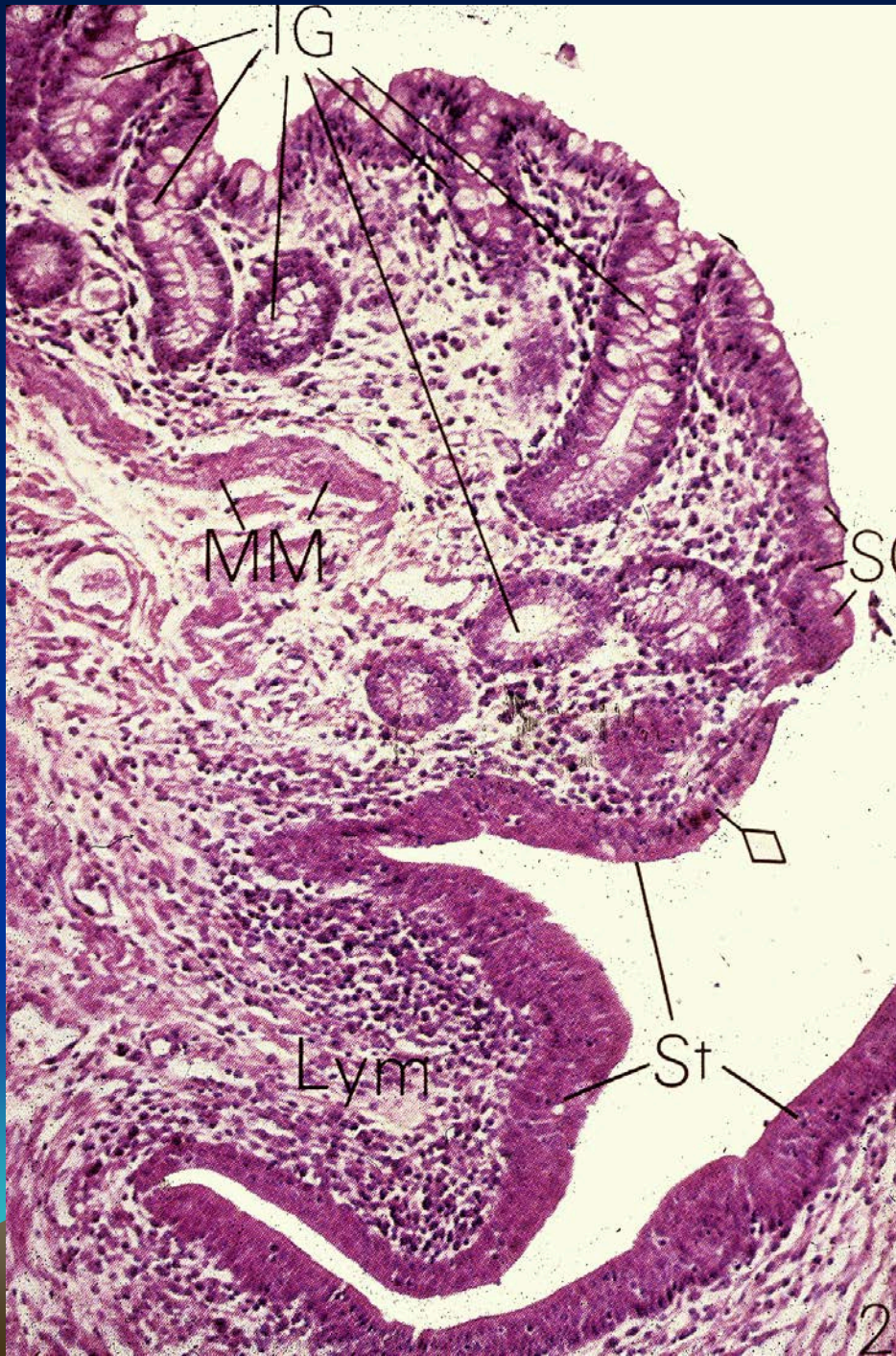

# Duodenum



# Colon Mucus Membrane by LM





## Rectum

w/ Crypts (TG) and the  
end of the muscularis  
mucosa (MM)

## Anal Canal

w/ St. Sq Non-K  
Epithelium