

**ELECTRON MICROSCOPIC STUDY OF ACUTE NEUROTOXICITY OF TOCP (TRI
ORTHO CRESYL PHOSPHATE) OF SCIATIC NERVE IN ADULT HEN**

MAJEED SALEH. K*
AL-SEREAH BAHAA. A**
AL-MOSAWI OMET. F***

*55 Desborough Road, Hartford- Huntingdon, Cambridgeshire, PE 29 1 SN, England

&*Dept. of Pathology & Poultry Diseases, College of Veterinary Medicine, Univ. of Basrah, Iraq

ABSTRACT

In acute neurotoxicity of TOCP of sciatic nerve there was more neurotic changes as degenerate myelin fibers in comparsm with few changes in the spinal cord. The study was done on 2 groups of adult hen, each group consist of 20 adult hen, 20 untreated control as single dosed orally with corn oil. Treated group of 20 adult hen dosed orally with 500mg/kg TOCP in corn oil as single dose. The experiment was 21 days as acute delayed neurotoxicity of TOCP. The result electron microscopy of sciatic nerve showed degeneration of myelin in myelinated nerve fibers characterized by vacillation of myelin, clumping of myelin, spheroid body formation of myelin, lamellated body of degenerate myelin, exoplasm showed increased of neurofilament also present of dark stained lamellated degenerate mitochondria. In addition there was also evidence of degeneration of unmyelinated nerve fiber evidence by presence of dark staind bodies, finally degenerate myelin was also seen as in engulfed degenerate myelin.

KEYWORDS: Sciatic Nerve, Acute, Electron Microscope and Hen.

INTRODUCTION

[1] Did ultrastructural study of TOCP in adult hen. [2] did acute neurotoxicity study on TOCP using dosage 300-700 mg/kg as acute neurotoxicity and reported changes in the peripheral nerves. [3] studied delayed neurotoxicity of organophosphorus (TOCP) of 400 mg/kg and observed changes after 7 days in the sciatic nerve electron microscopy revealed slide axonal degeneration but myelin sheath was intact while animal examined after 35 days showed marked axonal and myelin degeneration. [4] did CNS and PNS neurotoxicity of Diisopropyl phosphorofluoridate as acute neurotoxicity for 7-14 day and produced delayed neurotoxicity in adult hen associated with sever ataxia or paralysis. [5] studied the delayed neurotoxicity of phenylphosphonothioate esters in adult hen as acute neurotoxicity doing histopathological study on the axoplasm and myelin of adult hen. [6] in his study on expression of neurofilaments in CNS of hens treated with TOCP, they reported the possibility

of induced of degeneration of long large diameter axons of the peripheral nervous system in adult hen by neurotoxicity with TOCP. [7] study the neurologic manifestations of TOCP delayed neurotoxicity in cat, they found clinical and histopathological changes in the sciatic nerve. [8] in there study on mechanism of organophosphorus esters induced delayed neurotoxicity type I and type II on acute neurotoxicity on sciatic nerve.[9] studied A rodent model of organophosphate-induced delayed neuropathy: Distribution of central (spinal cord) and peripheral nerve damage.[10] studied the relationship between neurological damage and neurotoxic esterase inhibition in rats acutely exposed to tri-ortho-cresyl phosphate.[11]did histopathological assessment of triphenyl phosphite neurotoxicity in the hen.[12]did a teased-fiber study of the spatiotemporal spread of axonal degeneration.[13] studied the ultrastructure of tri-ortho-cresyl phosphate in poisoning. I. Studies on myelin and axonal alterations in the sciatic nerve.[14]did toxic polyneuritis in Bombay due to ortho-cresyl-phosphate poisoning.

MATERIALS AND METHODS

The study was done of 40 adult hen brought by especial supplier, divided into 2 groups: first group as untreated control of 20 adult hen dosed as single dose of corn oil, the second group of 20 adult hen which are the treated group dosed in single dose of 500mg/kg orally of TOCP in corn oil, both groups left for 21 days for observation of delayed neurotoxicity of TOCP. Hens died during the experiment and the rest of the hens from both groups were sacrificed after 21 days, sciatic nerve was taken and fixed in special fixation (glutaraldehyde) for electron microscope, sample were taken and were made cut and resin blocks by ultra microtome. Thin section of 1 μ g for histological orientation and stained with toluidine blue to select areas for electron microscope, then Copper grids were made and stained with uranyl acetate and lead citrate for electron microscope.

RESULTS

In the acute neurotoxicity of TOCP clinical signs of delayed neurotoxicity only start after 9 days and contineo to develop to the end of 21 days. Electron microscope study of sciatic nerve from hens treated with TOCP showed schwann cell nucleus and ovoid body formation(fig.1) ,degenerate myelin ,note dark- stained degenerate axoplasm contains excess neurofilaments and dark-stained bodies.possibly of mitochondrial origin(fig.2),an affected myelinated nerve fiber, note axoplasm dark- stained bodies probably drgenerate mitochondria(fig.3),non myelinated nerve fibers with dark stained lamellated body(fig.4),

swollen degenerate neuro processes with various stages of lamellated inclusions, note proliferation of neurofilaments(fig.5),degenerate non myelinated fibers with dark stained bodies(fig.6), collapsed nerve fibers, compressed axoplasm, note, vesiculation, lamellation and vacuolation of degenerate myelin(fig7),disorganised degenerate myelin, with clumps of degenerate dark stained myelin, note, displaced axoplasm, with dark stained bodies of degenerate mitochondria(fig.8), schwann cell with auto-phagocytosis, cholestrol clefts of degenerate myelin(fig.9) andsyncytium of schwann cells with degenerate myelin,notice naked axon enclosed by the syncytium of schwann cells(fig.10).

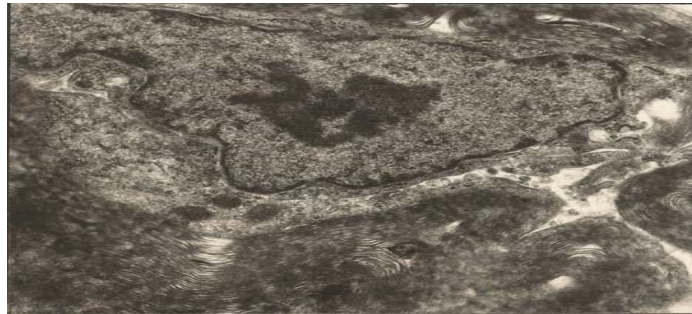


Fig. 1: Sciatic nerve with schwann cell nucleus and ovoid body formation. (EM. 20000 X)

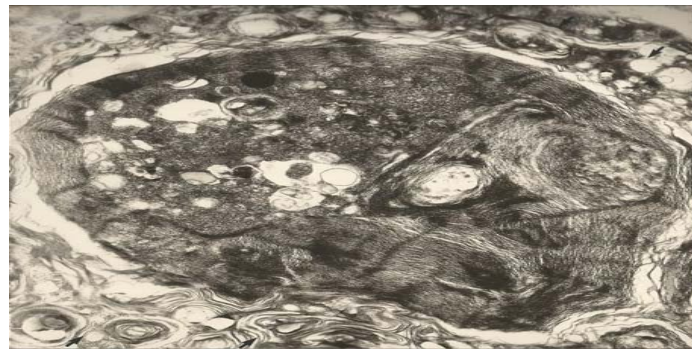

Fig. 2: Sciatic nerve with degenerate myelin (arrow), note dark- stained degenerate axoplasm contains excess neurofilaments and dark-stained bodies. possibly of mitochondrial origin (EM. 15000 X)

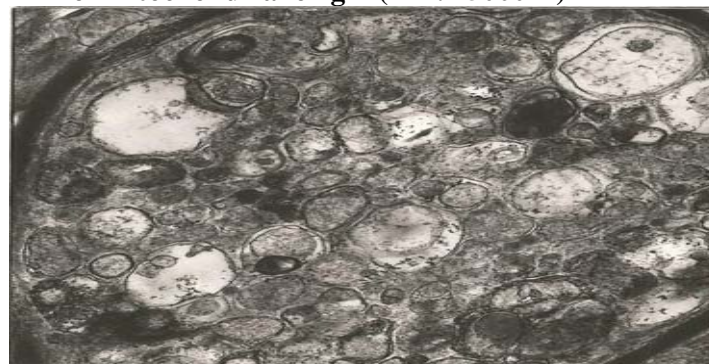

Fig. 3: Sciatic nerve with an affected myelinated nerve fiber, note axoplasm dark-stained bodies probably drgenerate mitochondria (EM. 15000 X)

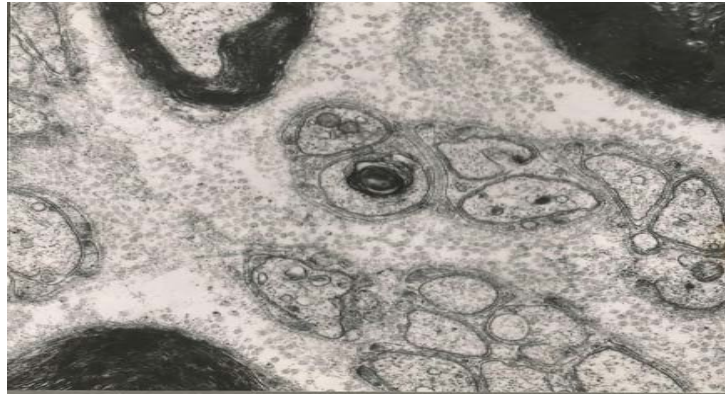

Fig. 4: Sciatic nerve with non myelinated nerve fibers with dark stained lamellated body. (EM. 20000 X)

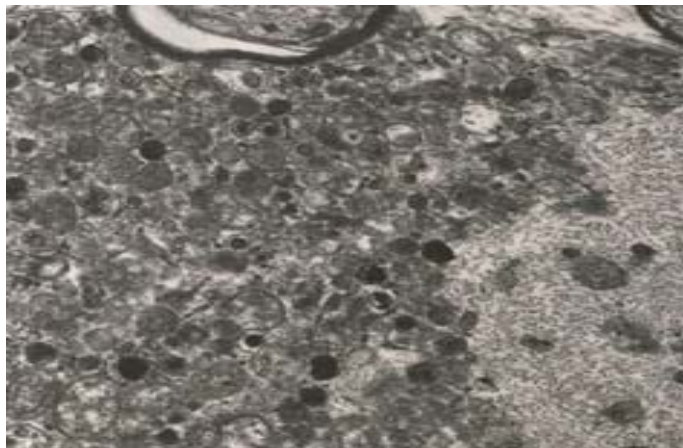


Fig. 5: Sciatic nerve with swollen degenerate neuro processes with various stages of lamellated inclusions, note proliferation of neurofilaments. (EM. 12000 X)

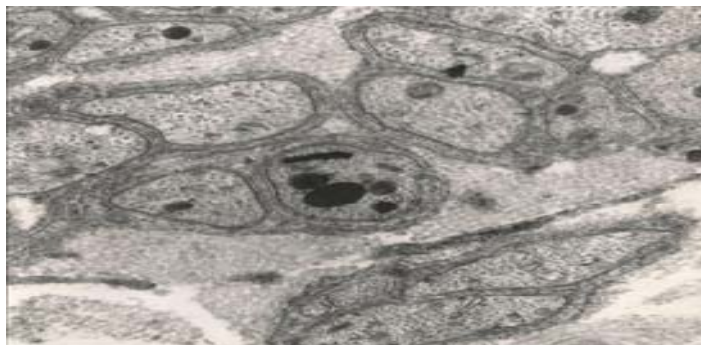


Fig. 6: Sciatic nerve with degenerate non myelinated fibers with dark stained bodies. (EM. 15000 X)

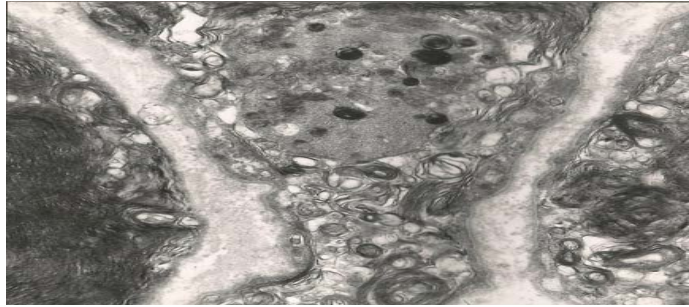

Fig. 7: Sciatic nerve with collapsed nerve fibers, compressed axoplasm, note, vesiculation, lamellation and vacuolation of degenerate myelin . (EM. 15000 X)

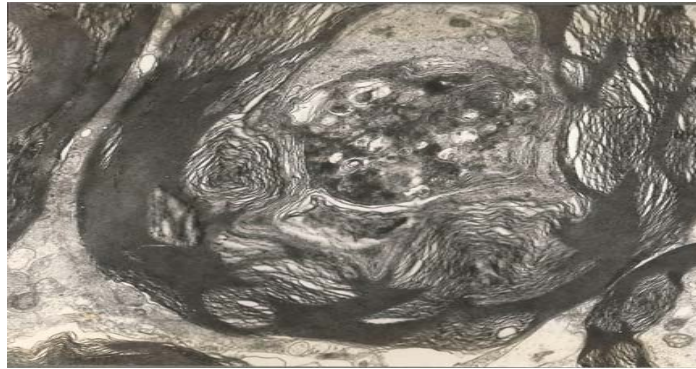

Fig. 8: Sciatic nerve with disorganised degenerate myelin, with clumps of degenerate dark stained myelin, note, displaced axoplasm, with dark stained bodies of degenerate mitochondria. (EM. 15000 X)



Fig. 9: Sciatic nerve with schwann cell with auto-phagocytosis, cholesterol clefts of degenerate myelin. (EM. 15000 X)

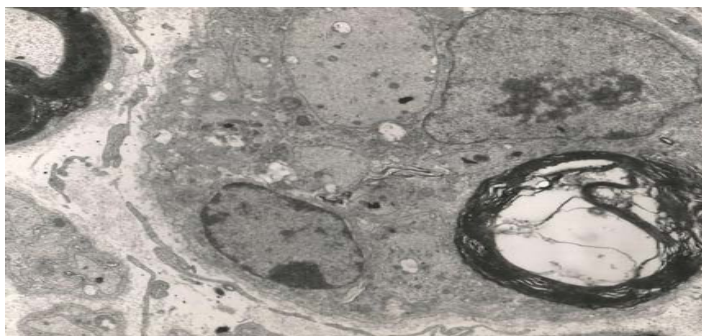


Fig. 10: Sciatic nerve with syncytium of schwann cells with degenerate myelin, notice naked axon enclosed by the syncytium of schwann cells. (EM. 20000 X)

DISCUSSION

[1] reported change in the white matter associated with proliferation of endoplasmic reticulum and dis integration of the neurofilament. the present research ultrastructural changes were seen as degenerate vacuolated lamellated myelin also presence of dark stained degenerate mitochondria in axoplasm of myelinated nerve fiber of neurofilament. In addition there was also electron microscopic changes as dark stained degenerate lamellated mitochondria in unmyelinated nerve fibers. Also presence of degenerate myelin in schwann cells as a form of autodigestion of myelin. [2] did acute neurotoxicity with TOCP using 300-700 mg/kg and reported peripheral nerve fiber regeneration. The present study used only 500mg/kg of TOCP in acute neurotoxicity in adult hen and observed changes it after 7-9 days up to 21 days.[3] did neurotoxicity on TOCP and found slide axoplasmic changes after 7days but myelin sheath was intact, only birds examined 35 days after dosing showed degeneration of axoplasm and myelin sheath. The present study we found axoplasmic and degeneration of myelin sheath in bird killed of poor condition after 7days and other sacrificed after 21 days showed axoplasmic and myelin degeneration.[4] did acute neurotoxicity Diisopropyl phosphorofluoridate for 7-14 days as acute neurotoxicity of sciatic nerve reported ataxia and or paralysis. The present study did acute neurotoxicity on TOCP with single dose 500mg/kg for 21days also reported ataxia and or paralysis stented at 7-21 days.[5] in his work on neurotoxicity of phenylphosphonothioate esters reported acute neurotoxicity changes in sciatic nerve characterized by axoplasmic and myelin degeneration. The above agreed with our finding in acute neurotoxiety of TOCP in adult hen as we found axoplasmic and myelin degeneration on base of microscopic study. [6] suggested that TOCP can induce degenerative changes in long large diameter axons of sciatic nerve. This agreed with our research topic with the presence of ultrastructural changes in sciatic nerve induced by TOCP. [7] reported

clinical and histopathological delayed neurotoxicity in cats. Our present study agreed with above that TOCP can induce histopathological changes in adult hen as those in cat. [8] reported light and electron microscopic changes in sciatic nerve by acute neurotoxicity in adult hen, they noticed proliferation of neurofilaments and smooth endoplasmic reticulum in axoplasm of nerve fibers. Our study agreed with above due to the presence of the electron microscopic changes our findings were proliferation of neurofilament in axoplasm associated with degenerate mitochondria.[9] using rat as a model for neurotoxicity in found changes in the sciatic nerve which agreed with our findings in the sciatic nerve but we constrained mostly on ultrastructural changes in the sciatic nerve.[10] studied relationship between neuropathological damage and neurotoxic estrase inhibition in rats. Our study concentrated on electron microscopic changes in the myelinated nerve fibers of sciatic nerve and found proliferation of neurofilaments and changes of mitochondria.[11] did histopathological assessment of tri phenyl phosphate neurotoxicity in hen and reported changes in the sciatic nerve characterized by myelin degeneration and axoplasmic change. Our finding which was of TOCP in hens and we found evidence of degeneration of myelin proliferation neurofilament of axoplasm with degenerate mitochondria.[12] the reported proliferation of smooth endoplasmic reticulum of axoplasm in their neurotoxicity studies in rats. In our study we found proliferation of neurofilament and degenerate mitochondria in combination with myelin degeneration.[13] did ultrastructural study on neurotoxicity of TOCP in hens, he reported proliferation of vesicular endoplasmic reticulum in axoplasm.our study was mainly on electron microscopic study of TOCP on sciatic nerve and we found proliferation of neurofilament and degenerate mitochondria.[14] they did study on toxic poly neuritis in human exposed to tri-ortho cresyl phosphate poisoning .our study was mainly on acute neurotoxicity of TOCP in hens associated with proliferation of neurofilament and degenerate mitochondria.

Research highlights

The present topic was electron microscopic study of sciatic nerve of neurotoxicity of triorthocresyl phosphate in adult hen in acute study.

Finding and policy aspects

The findings of the present paper showed the electron microscopic changes in sciatic nerve of acute neurotoxicity of TOCP in adult hen.

Justification of research

Because of the important of neurotoxicity of TOCP in adult hen electron microscopic changes were suggested to give fine details of the changes in the sciatic nerve.

Conclusion

The result showed that electron microscope can give detail changes in the myelinated and unmyelinated nerve fiber of sciatic nerve which cannot be seen by light microscope.

Recommendation

It is recommended that electron microscopic study must be done to find the detail changes in sciatic nerve induced by neurotoxicity of TOCP in adult hen.

REFERENCES

1. Bischoff, A.(1970).Ultrastructure of Tri-Ortho-Cresyl Phosphate poisoning in the chicken. *Acta Neuropathologica*. 15 (2):142-155
2. Nanda, S. and Tapaswi, P.K.(1995). Biochemical, neuropathological and behavioral studies in hens induced by acute exposure of tri-ortho-cresyl phosphate. *Int. J. Neurosci*. 82(3-4):243-54.
3. Itoh, H.; Kishida, H.; Tadokoro, M. and Oikawa, K.(1984).Studies on the delayed neurotoxicity of organophosphorus compounds--(II). *J. Toxicol Sci*. 9(1):37-50.
4. Gupta, R. P.; Damodaran T. V. and Abou-Donia, M. B.(2000).C-fos mRNA Induction in the Central and Peripheral Nervous Systems of Diisopropyl Phosphorofluoridate (DFP)-Treated Hens. *Neurochemical. Res*. 25.3 : 327–334.
5. Abou-Donia , M.B.(1979).Delayed neurotoxicity of phenylphosphonothioate esters. *Sci*. 205 . 4407 : 713-715 .
6. Zhaoa, X.l.; Zhangb ,T.l.; Zhanga, C.l.; Hanc, X.y.; Yua, S.f.; Lid, S.x.; Cuie, N. and Xiea, K.q. (2006). Expression changes of neurofilament subunits in the central nervous system of hens treated with tri-ortho-cresyl phosphate (TOCP). *Toxicol*. 223. 1–2: 127–135.
7. Abou-Donia, M.B.; Jensen, D.N. and Lapadula, D.M.(1983).Neurologic manifestations of tri-O-cresyl phosphate delayed neurotoxicity in cats. *Neurobehavio. Toxicol. and Teratol*. 5(4):431-442.
8. Abou-Donia, M. B. And Lapadula, D.M. (1990).Mechanism of organophosphorus esters-induced delayed neurotoxicity: type I and type II *Annu . Rev. Pharmacol. Tox-icol*. 30:405-40.
9. Veronesi, B. (1984). A rodent model of organophosphate-induced delayed neuropathy: Distribution of central (spinalcord) and peripheral nerve damage. *Neuropathol. Appl. Neurobiol*. 20:357-68.
10. Padilla, S., Veronesi, B. (1985). The relationship between neurological damage and neurotoxic esterase inhibition in rats acutely exposed to tri-ortho-cresyl phosphatc. *Toxicol. Appl. Pharmacol*. 78:78-87.
11. Carrington, C. D; Brown, H. R . and Abou-Donia, M . B .(1988).Histopathological assessment of triphenyl phosphite neurotoxicity in the hen. *Neurotoxicol*. 9:223-34.
12. Bouldin, T. W. and Cavanagh, J. B.(1979).A teased-fiber study of the spatiotemporal spread of axonal degeneration. *Am.J. Pathol*. 94:241-52.
13. Bischoff, A.(1967). The ultrastructure of tri-ortho-cresyl phosphate in poisoning. I . Studies on myelin and axonal alterations in the sciatic nerve. *Acta Neuropathol*. 9: 1 58-74.
14. Vora, D. D . , Dasutr, D. K . ; Braganca, B . M . ; Parihar, L. M . and Iyer, C. G. S . (1962) . Toxic polyneuritis in Bombay due to ortho-cresyl-phosphate poisoning. *J. Neural. Neurosurg. Psychiatr*. 25:234-42.