

DIAMOND FLAP ANOPLASTY FOR SEVERE ANAL STENOSIS

Muayad J Lefta* & Qais K Baqir@

*MBChB, FICMS, CABS, General Surgeon, Department of Surgery, Al-Sadr Teaching Hospital, Basrah, Iraq, @MBChB, FICMS, CABS, General Surgeon, Department of Surgery, Al-Sadr Teaching Hospital, Basrah, Iraq. Lecturer, Dept. of Surgery, Basrah College of Medicine.

Abstract

Anal stenosis is an uncommon condition usually resulted from hemorrhoid surgery. It is one of the common disabling anal conditions and a lot of surgical techniques have been described to treat this condition.

Sixteen cases of severe anal stenosis were included in a prospective study from July 2002 to January 2012 in Al-Sadr Teaching and private Hospitals; there were 14 males and 2 females. All patients received preoperative antibiotics and single enema for bowel preparation. Internal anal sphincterotomy done for all patients, four patients required bilateral flap anoplasty and twelve required only unilateral diamond flap anoplasty.

This study included a total of 16 patients, 14 males and 2 females. Mean age was 35.3 years. Main etiology was hemorrhoidectomy (15 cases), most patients suffer from obstructed defecation, painful evacuation and episodes of minor rectal bleeding. Most patients express improvement in postoperative pain and good functional satisfaction (using visual analogue scale VAS). Complications were minor and treated successfully.

Anal stenosis although uncommon, is a feared disabling anal condition mostly resulted from hemorrhoid surgery, a lot of surgical techniques have been described to treat severe anal stenosis, no one regarded as superior but all share the property of achieving patient's satisfaction.

In conclusion, diamond flap anoplasty is easy procedure with low complication rate and gives good results for treatment of severe anal stenosis.

Introduction

Anal stenosis is an uncommon but is a serious condition usually results from anorectal surgery mostly hemorrhoidectomy (over 90%)¹⁻⁴, rarely anal stenosis can result from inflammatory bowel diseases, tuberculosis, radiation therapy, direct trauma, venereal diseases or congenital stenosis (microanus)^{2,5,6}, it can lead to morphological changes of anal canal leading to painful or difficult defecation⁷⁻⁸.

Variable classifications have been described and it is useful to determine the severity of stenosis and distinguish whether it is "true" stenosis or "functional" stenosis due to spasm of internal anal sphincter as in acute fissure in ano. Milsom & Mazier classify it to

"mild" in which tight anus can be examined with well lubricated index figure or admits medium size Hill-Ferguson (HF) retractor, "moderate" in which forceful dilatation is required to insert index figure or medium size HF retractor, and "severe" type in which neither little figure nor small size HF retractor can be inserted without forceful dilatation of anal canal⁹. Diagnosis is usually straight forward after careful history and local inspection with digital rectal examination, history of anal procedure especially hemorrhoidectomy is a strong evidence of anal stenosis¹⁰. Patients usually report painful or difficult defecation other symptoms include narrow stool, rectal bleeding and constipation.

Anal manometry may be used to document sphincter function before doing sphincteroplasty which may affects continence¹⁰. Mild to moderate forms may be treated conservatively or with lateral internal sphincterotomy, while severe forms may needs a form of anoplasty technique .Various surgical plastic techniques has been described to treat severe anal stenosis including mucosal advancement flap, Y-V flap, V-Y flap, C flap, house flap, Diamond flap, rotational flap and etc. Despite no anaplastic technique is regarded optimum; all of them can relieve patient's symptoms and get patient's satisfaction¹⁰⁻¹¹.

Patients and methods

A prospective study was conducted at AL-Sadr (Basrah) Teaching & private hospitals from July 2002 to Jan. 2011 involving 16 patients with severe anal stenosis. Age and sex of patients were recorded; careful history was taken including previous anal or rectal procedure, history of trauma or other possible etiology. All patients were examined carefully with digital rectal examination to ascertain the severity of stenosis. Only cases of severe anal stenosis were included in the study (Milsom & Mazier), informed consent was taken and all operations conducted under general anesthesia in the lithotomy position. Mechanical bowel preparation done for patients with single enema. All patients received preoperative ceftriaxone 1 gm. and metronidazole infusion 500mg few hours before the procedure. All cases were subjected to proctological examination before conducting surgery. The procedure includes making incision across the fibrotic stricture to dilate the anus and make a diamond flap defect (figure 1 A) then equivalent diamond flap was made adjacent and lateral to the defect (figure 1 B) with good mobilization of skin and subcutaneous fat to ensure suturing to the defect without tension then the resultant defect lateral to the flap was

sutured with interrupted 4-0 vicryl suture (figure 1 C). Lateral internal sphincterotomy done for all patients. Patient was discharged at the day after surgery, all patients examined at 1, 2 and 7 days postoperative for any early complications and assessment of pain using Visual Analogue Scale VAS (from 0-10), and then after 3 and 6 months to evaluate the result of procedure and patients satisfaction also using visual analogue scale (VAS). Stool softeners were used for first few postoperative days to aid evacuation.

Results

Total of 16 patients with severe anal stenosis, 2 females and 14 males, Age ranged from 25 to 52 years (table I). Etiology: 15 post hemorrhoidectomy stenosis, and 1 traumatic fibrosis (shell injury) (table II). Symptoms include obstructive defecation (16), painful evacuation (14) and minor bleeding during defecation (14) (table III). In 4 patients bilateral diamond flap anoplasty were performed, while 12 patients required only unilateral diamond flap anoplasty. Lateral internal sphincterotomy done for all 16 patients. Results of visual analogue scale used to assess postoperative pain shown in (figure 2). Wound breakdown occur in all patients within seven days postoperatively. No flap loss or displacement occurs. Two patients develop transient gas incontinence resolved within 6 months of physiotherapy treatment. One patient developed moderate wound infection, two developed mild wound infection and all treated adequately with antibiotics (table IV). All patients show early [within 1 month] improvement and all followed between 3-6 months with good satisfaction (figure 3).

Discussion

Anal stenosis, although rare, is one of the most feared and disabling complication of anorectal surgery. Several causes can lead

to anal stenosis most frequently hemorrhoidectomy^{1,10,11}. A lot of surgical techniques have been described for the management of moderate to severe anal stenosis¹². The best management of anal stenosis is prevention and ideal technique should be easily conducted with satisfactory results and low complication rate with short hospitalization. In this study we use diamond flap anoplasty to deliver more anoderm (skin) into the anal canal to fill the defect that results after cutting of fibrous scarring. Internal anal sphincterotomy was required to ease anal dilatation¹³. Flap preparation is important for success of procedure, it is necessary to preserve much subcutaneous fat and wide mobilization to maintain flap viability and avoid suture line tension; also it is important to handle the tissue delicately to avoid damage to its blood supply¹⁴.

The use of bilateral flaps depends on the degree of anal dilatation after the completion of a unilateral flap. The use of lateral sphincterotomy gives more room for dilatation, decrease postoperative discomfort and reduce failure rate¹⁵. The

low complication rate and high patient's satisfaction were comparable to other studies and reflects the easiness and effectiveness of the technique, moreover diamond-shaped flap is designed so that it will cover the intra-anal portion of the defect. The flap is mobilized with minimal undermining to preserve the integrity of the subcutaneous vascular pedicle whereas in V-Y anoplasty the tip of the V is subject to ischemic necrosis, and in Y-V flap the proximal part of the flap is very narrow and will not allow for a significant widening of the stricture above the dentate line, also the tip of the V within the anal canal is subject to ischemic necrosis from lack of mobilization, tension of the flap or loss of vascularization. In C and in U flaps the donor site left open^{9,10,16-18}.

Conclusion

Diamond flap anoplasty is easy procedure with low complication rate and can be used for severe anal stenosis. General surgeon should be prepared to apply a form of anoplasty technique to be capable to manage cases of severe anal stenosis.

Figure 1: Steps of anoplasty

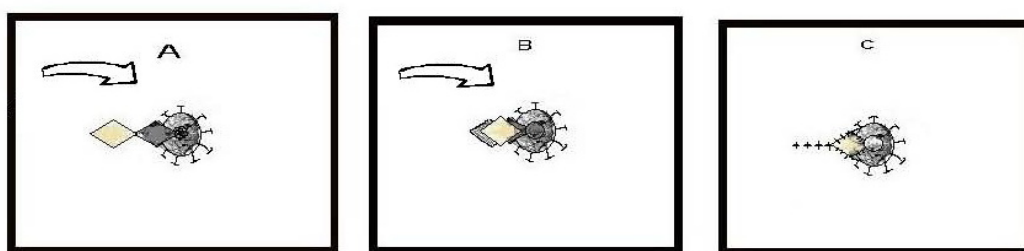


Table I: Gender and age characteristics

| Sex distribution | | Mean Age (range) | % |
|------------------|----|------------------|------|
| Male | 14 | 34.4 (25-52) | 87.5 |
| Female | 2 | 42 (34-50) | 12.5 |
| Total | 16 | 35.3(25-52) | 100 |

Table II: Etiology

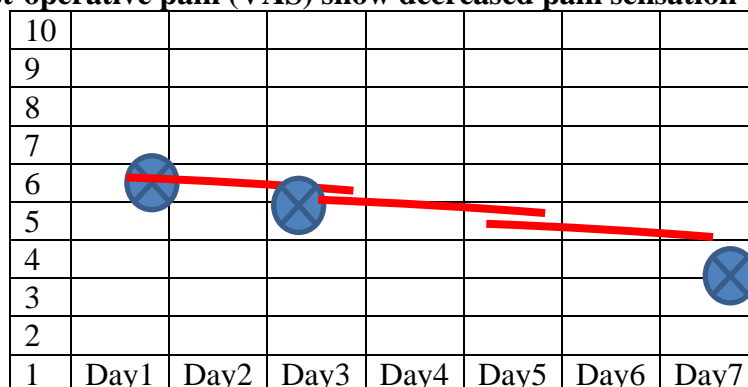
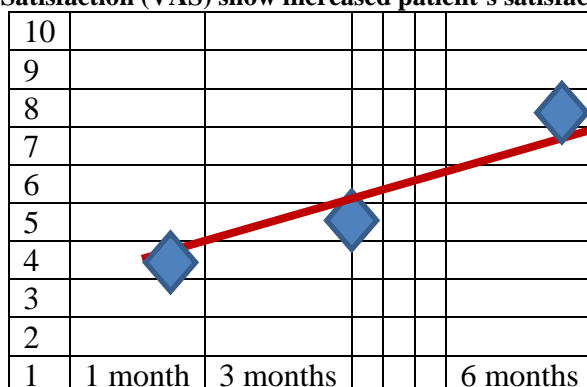
| Etiology | Number | % |
|-----------------------------------|--------|-------|
| Post hemorrhoidectomy fibrosis | 15 | 93.75 |
| Traumatic fibrosis (shell injury) | 1 | 6.25 |
| Total | 16 | 100 |

Table III: Clinical presentation

| Symptom | Number | % of occurrence |
|---------------------------|--------|-----------------|
| Obstructive defecation | 16 | 100 |
| painful evacuation | 14 | 87.5 |
| Bleeding after defecation | 14 | 87.5 |

Table IV: Postoperative complications

| complication | No. of patients | % |
|--------------------------|-----------------|----|
| Mild wound infection | 2 | 12 |
| Moderate wound infection | 1 | 6 |
| Gas incontinence | 2 | 12 |
| Flap loss | 0 | 0 |

Figure 2: Post-operative pain (VAS) show decreased pain sensation with time scale**Figure 3: Patient's Satisfaction (VAS) show increased patient's satisfaction in 3 and 6 months**

References

- Habr-Gama A, Sobrado CW, Araujo SE, Nahas SC, Birojm I, Nahas CS, Kiss DR. Surgical treatment of anal stenosis: assessment of 77 anoplasties. *Clinics* 2005; 60: 17-20.
- Casadesus D, Villasana LE, Diaz H, Chavez M, Sanchez IM, Martinez PP, Diaz A. Treatment of anal stenosis: a 5-year review. *ANZ J Surg* 2007; 77: 557-559
- Khubchandani IT. Anal stenosis. *Surg Clin North Am* 1994; 74: 1353-1360
- Liberman H, Thorson AG. How I do it. Anal stenosis. *Am J Surg* 2000; 179: 325-329
- Maria G, Brisinda G, Civello IM. Anoplasty for the treatment of anal stenosis. *Am J Surg* 1998; 175:158-160
- Christensen MA, Pitsch RM Jr, Calli RL, Blatchford GJ, Thorson AG. "House" advancement pedicle flap for anal stenosis. *Dis Colon Rectum* 1992; 35: 201-203
- Owen HA, Edwards DP, Khosravi K, Phillips RK. The house advancement anoplasty for treatment of anal disorders. *J R Army Med Corps* 2006; 152: 87-88
- Parnaud E. Leiomyotomy with anoplasty in the treatment of anal canal fissures and benign stenosis. *Am J Proctol* 1971; 22: 326-330
- Milsom JW, Mazier WP. Classification and management of postsurgical anal stenosis. *Surg Gynecol Obstet* 1986; 163: 60-64
- Giuseppe Brisinda, Serafino Vanella, Federica Cadeddu, Gaia Marniga, Pasquale Mazzeo, Francesco Brandara, Giorgio Maria. Surgical Treatment of Anal Stenosis. *World J Gastroenterol* 2009; 28: 15(16): 1921-28.
- Filingeri V, Gravante G, Cassisa D. Radiofrequency Y-V anoplasty in the treatment of anal stenosis. *Eur Rev Med Pharmacol Sci* 2006; 10: 263-267.
- Alver O, Ersoy YE, Aydemir I, Erguney S, Teksoz S, Apaydin B, Ertem M., Use of "house" advancement flap in anorectal diseases. *World J Surg* 2008 Oct;32(10):2281-6.
- Filingeri V, Gravante G, Cassisa D. Radiofrequency Y-V anoplasty in the treatment of anal stenosis. *Eur Rev Med Pharmacol Sci* 2006; 10: 263-267.
- Aitola PT, Hiltunen KM, Matikainen MJ. Y-V anoplasty combined with internal sphincterotomy for stenosis of the anal canal. *Eur J Surg*. 1997 Nov;163(11):839-42.
- Carditello A, Milone A, Stilo F, Mollo F, Basile M. Surgical treatment of anal stenosis following hemorrhoid surgery. Results of 150 combined mucosal advancement and internal sphincterotomy. *Chir Ital*. 2002 Nov-Dec;54(6):841-4.
- Stratmann H, Kaminski M, Lauschke H, Hirner A. Zentralbl Chir. Plastic surgery of the anorectal area. Indications, technique and outcome]. 2000;125(2):161-5.
- Gingold BS, Arvanitis M. Y-V anoplasty for treatment of anal stricture. *Surg Gynecol Obstet* 1986; 162: 241-242.
- Oh C, Zinberg J. Anoplasty for anal stricture. *Dis Colon Rectum* 1982; 25: 809-810.