



Journal of Applied Sciences

ISSN 1812-5654

science
alert

ANSI*net*
an open access publisher
<http://ansinet.com>



Research Article

Isolation, Purification and Identification of Blue-green Alga *Hapalosiphon aureus* and Evaluation of its Histopathological Effects on Fresh Water Snail *Lymnaea auricularia*

Emad Yousif Awad AL-Sultan

Department of Biology, College of Education for Pure Sciences, Basra University, Iraq

Abstract

Background and Objective: Blue-green algae often blooming in fresh water worldwide after organic pollution (Nutrient enrichment). The high proliferation of blue-green algae during blooms may cause changes in ecosystem due to toxicity of several species. The toxins which can be produced by these algae draw the scientific society attention to highlight their biological effect in ecosystem. **Methodology:** The current study included isolation and purification of cyanobacterial alga *Hapalosiphon aureus* West and West 1897 from Al-Ashar-river in Basra Governorate Southern of Iraq and cultivation of an axenic culture by using BG-11 liquid medium. The ability of this alga to produce hepatotoxin, in particular, microcystins was measured by using the enzyme linked immunosorbent assay technique. **Results:** Findings showed that *H. aureus* produced microcystin approximately $53.32 \mu\text{g g}^{-1}$ of lyophilized cells. Fresh water snail *Lymnaea auricularia* was used to assess the biological toxicity of this algal species. Some histopathological changes such as degeneration and aggregation of some non-living components in the cytoplasm of hepatocytes were detected after acute exposure (48 h). While after 2 week of exposure hyperchromic, necrosis, aggregation of some non-living components in epithelial tissues of hepatopencreas and degeneration were detected. The intestine after the acute exposure showed disappearance of brush border epithelial tissue and necrosis, while after the chronic exposure, degeneration, necrosis, loss and hypertrophy of epithelial tissue and hypertrophy were observed. Prostate gland did not show any histopathological symptoms through the acute exposure, whereas, chronic exposure for algal extraction caused alveolar dilation and metaplasia of epithelial tissue of alveolar in comparing with control group. **Conclusion:** In the current study a new species of filamentous blue-green algae was diagnosed in Iraq and their adaptability to produce hepatic toxin (microcystins) in high concentration. Also, many histopathological effects were showed on fresh water snail under low concentration of microcystin extract and this points to the possibility of transmission of the poison to the food chain and may be using this alga as biological control on snail.

Key words: Blue-green alga, *Haplosiphon aureus*, microcystins, *Lymnaea auricularia*, histopathological effects

Received: September 06, 2016

Accepted: November 12, 2016

Published: January 15, 2017

Citation: Emad Yousif Awad AL-Sultan, 2017. Isolation, purification and identification of blue-green alga *Hapalosiphon aureus* and evaluation of its histopathological effects on fresh water snail *Lymnaea auricularia*. J. Applied Sci., 17: 61-71.

Corresponding Author: Emad Yousif Awad AL-Sultan, Department of Biology, College of Education for Pure Sciences, Basra University, Iraq

Copyright: © 2017 Emad Yousif Awad AL-Sultan. This is an open access article distributed under the terms of the creative commons attribution License, which permits unrestricted use, distribution and reproduction in any medium, provided the original author and source are credited.

Competing Interest: The author has declared that no competing interest exists.

Data Availability: All relevant data are within the paper and its supporting information files.

INTRODUCTION

Cyanobacteria are a phylum of blue-green algae that get their energy from sun light by photosynthesis and known as blue-green algae. These algae are considered the most abundant in the world with a big role to primary productivity¹. Previous studies showed many blooming phenomenon of blue-green algal species and detected their ability to produce toxins^{2,3}. Blue green algae produce several toxins which causes a hazard for drinking and raw water safety such as hepatotoxins, neurotoxins and cylindrospermopsins. These toxins are different in their structures and toxicity^{4,5}.

Blue-green algae often blooming in fresh water worldwide after organic pollution (Nutrient enrichment)⁶. The high proliferation of blue-green algae during blooms may cause changes in ecosystem due to toxicity of several species^{7,8}. Microcystins and nodularins are considered the most important hepatotoxins which can be found in different habitat from fresh water to oceans and produce from several genus *Microcystis*, *Nostoc*, *Plantothrix*, *Nostoc*, *Anabaena*, *Calothrix* and *Hapalosiphon*⁹⁻¹³. Hepatotoxins are considered the most common of cyanotoxins especially microcystins (MCs) which have been 80 variants identified^{6,14}. Microcystins are intracellular toxins but may rapidly release by cell lysis as a result of senescence, pesticides or environmental stress¹⁵.

Blue-green algae may causes some lethal effects on highly range of aquatic and terrestrial organisms but other are less. Mollusks and crustacean may fed on toxic cyanobacteria so they consider as vectors at least when their guts load of toxins¹⁶. Microcystins cause acute and chronic effects in different terrestrial or aquatic organisms and entering the food web by accumulation primarily in liver or gastrointestinal tract or in digestive gland in vertebrate and invertebrate, respectively¹⁷⁻²⁰.

Gastropods can be exposed to cyanotoxins following ingestion of toxic blue-green algae or exposure to dissolved extracellular toxins after algal cell lysis. Several observation showed that gastropods may be accumulate free microcystins by grazing toxic blue-green algae less than uptake dissolved toxins in water²¹⁻²⁶. Moreover, several studies showed the ability of microcystins to accumulate in tissues and causes impair digestive gland homeostasis in gastropod of *Lymnaea stagnalis* as a result of consumption of toxic cyanobacteria or exposed to dissolved microcystins²⁷⁻³⁰.

In the field gastropods are exposed to chronic effects during blooming period after ingestion of toxic algae producing microcystins and acute exposure at the end of this

period²⁴. The snail *Lymnaea auricularia* is one of the important invertebrates, which taxonomically belonging to the phylum: Mollusca, class Gastropoda, subclass: Pulmonata, Order: Basommatophora and to the family: Lymnaceae. It is medium-sized snail and characterize by thin shell with short-rolls³¹. Several studies was recorded awidely distribute of this snail in many freshwater sites southern of Iraq^{32,33}. The previous studies were referred to the infections of snail *L. auricularia* with many species of trematod larvae^{33,34} and considered as intermediate host of parasites of *Fasciola* and *Schistosoma* species which are the causes of many risks to human and other animals³⁵. The present study was aimed to isolation, purification of filamentous blue-green alga *Hapalosiphon aureus* from of Al-Ashar-river Southern of Iraq with evaluate its ability to produce hepatotoxin (Microcystins) and showed histopathological effects on some tissues of the fresh water snail *L. auricularia* in the laboratory after exposure on microcystin extract.

MATERIALS AND METHODS

Water sample collection: Water samples were collected from Al-Ashar river, Basra governorate, Southern of Iraq by using phytoplankton net with mesh size 20 μ then water samples were put in clean plastic bottles and brought to the laboratory for isolation and purification of the blue-green alga.

Isolation, identification and purification of blue-green alga

***H. aureus*:** The blue-green alga *H. aureus* was isolated from water samples using liquid media (BG-11) and solid media (Spreading method) on agar 2% agar/liquid media in order to exclude a unialgal culture of cyanobacterial alga then get a pure culture as axenic culture^{36,37}. The purified alga was classified^{38,39}. All laboratory works were performed in Biological Science Department/College of Education For Pure Science/Basra University.

Cultivation and harvesting of alga *H. aureus*:

Axenic culture of *H. aureus* was cultivated as a batch culture in conical flasks 3 L in volume filled with 2 L of sterilized medium (BG-11). The flasks were put in growth chamber with light and dark illumination period 12:12 h under a light intensity of (130-150 $\mu\text{E}^2 \text{ sec}^{-2}$) and temperature of $25 \pm 2^\circ\text{C}$. The growth period of cyanobacterial alga extended for 3 weeks (21 days). Then the harvesting was accomplished by filtering the growth of alga on GF/C filter paper. The filtrated cells were lyophilized to get the dry weight by using freezing drier apparatus type (Top 10 D freeze dryer)³⁶.

Extraction and purification of microcystin: Microcystin was extracted and purified according to methods of Harada *et al.*⁴⁰ and Park *et al.*⁴¹. One gram of lyophilized cells was extracted three times with 10 mL of 0.05 M acetic acid for 30 min with stirring. After that the extraction was centrifuged at 4000 rpm. The supernatant was adjusted to pH = 10 by using ammonium hydroxide 7%. The adjusted extract was directly applied to a reverse phase ODS-disposable extraction column[®] 18). The column was preconditioned by washing with 10 mL of methanol and then 10 mL of water. The column containing toxins was washed with 10 mL distal water, followed by distal water-methanol (9:1 mL v/v). Elution from the column with methanol (20 mL) gave the toxins-containing fraction and the toxin MCs were detected as type and concentration by using ELISA method according to Weller *et al.*⁴², by using apparatus reader ELISA type (Biotek). This analysis was performed by the immune-assay method with an ELISA microcystin plate kit of Abraxis company (USA)⁴³.

Collection and acclimation of fresh water snail *Lymnaea auricularia*: Fresh water snail *L. auricularia* was collected from AL-Ghibaesh marshes Northern of Basra governorate southern of Iraq. The identification of the snail was performed in according to Ahmed⁴⁴ and confirmed by Murtada Yousif AL-Abad (Personal communication) in College of Education for pure sciences/Basra University. The snails were cultured in the laboratory in class aquarium with dimensions of (30×20×20 cm) which was filled with filtered tap water and provided with oxygen by aerator and fed on commercial fish food. The laboratory generations were used in experiments of toxicity.

Preparation of extract of microcystin from alga *H. aureus* and toxicity experiment against fresh water snail *Lymnaea auricularia*: Microcystin was extracted from lyophilized cells (1 g) of cyanobacterial alga *H. aureus* in according to the method⁴⁰ which is mentioned in this study. The extraction was filtered by GF/C filter paper, supernatant concentrated and dried and then dissolve in 100 mL of distal water. Four aquaria had used in each experiment (Three replicate). Each aquarium filled with 6 L of tap-water with 8 snails and fed on fish food (artificial food) during the experiment. About 10 mL of toxin extraction (Microcystin) was added to each aquarium and the concentration of toxin was measured and fixed (7.5 µg L⁻¹) ppb, which was determined and measured by using the ELISA technique focus processed Abbraxis company/United Status. Snails were exposed to microcystin extract for two periods of exposure, (1) Acute

exposure for 2 days and (2) Chronic exposure period for 2 weeks in addition to control group. Four snails were randomly selected to study the histopathological effects of toxins on their hepatopencreas, intestine and prostate gland.

Histological sectioning: Paraffin wax method was followed for histological sectioning of the snail organs. After exposure to the microcystin extract from alga *H. aureus*, four snails were removed from each exposure period for histological investigation. Shells were removed and then the bodies were fixed in bouins fluid for 48 h. Tissues were processed as described by Humason⁴⁵. About 7 µm thick longitudinal sections were performed and stained with hematoxylin and eosin.

RESULTS

Isolation, identification and purification of blue-green alga and detection its toxicity: Results showed isolation and purification of blue-green alga *H. aureus* by using special liquid medium (BG-11) from contaminated water of Al-Ashar river/Basra Governorate Southern of Iraq. This alga which characterized by filamentous alga, branched (True branch) arising from one side (rarely from both sides) of the main filaments. Cells ellipsoid, quadrate or cylindrical especially in the apices of branches and heterotrichous thallus. The lateral branch is less than the prostrate filaments in diameter. The thallus contain heterocyst 12.5 µm in length and 10 µm in width and vegetative cells 12.5 µm in length and 8.75-10 µm in width (Fig. 1). This alga belonging to following taxa:

Division : Cyanobacteria (Blue-green algae)
Order : Stigonematales
Family : Stigonemataceae
Genus : *Hapalosiphon*
Species : *Hapalosiphon aureus* (West and West 1897)

This alga *H. aureus* was showed their ability to produce hepatotoxin exactly microcystin with high concentration reach approximately to 50.32 µg L⁻¹ to each 1 g of lyophilized dry weight of alga.

Histopathological effects

Hepatopencreas gland: Figure 2 showed the normal tissue of hepatopencreas (Control group), while histological experiment showed that the hepatopancreas gland of the snail *L. auricularia* which exposed for 48 h to algal toxin extract (Mcs) was undergone from some histopathological

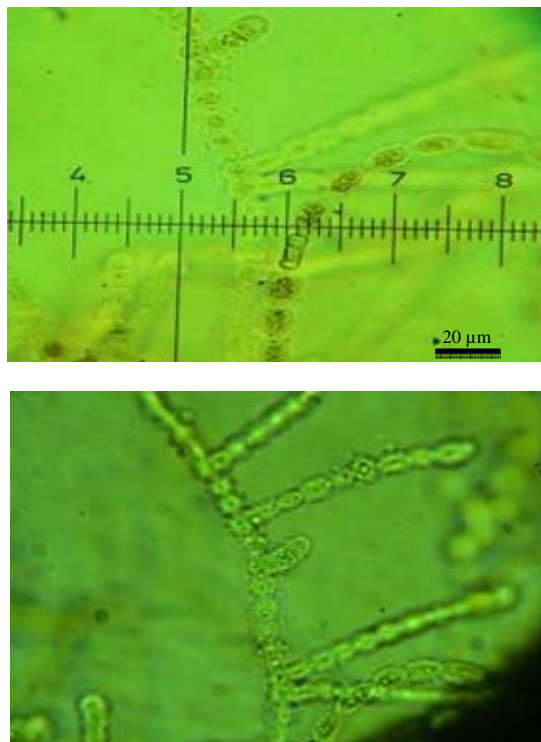


Fig. 1: Vegetative form of blue-green alga *H. aureus* 40x

changes which represented by degeneration and aggregation of non-living things in hepatocytes (Fig. 3). While, after two weeks of exposure, a considerable histopathological symptoms were seen which characterized by aggregation of non-living components in the epithelial cells of hepatopencreas with hyperpigmentation (hyperchromic), necrosis and degeneration (Fig. 4-7).

Digestive canal: Figure 8 showed the normal tissue of intestine (Control group), while after 48 h of exposure to toxin extraction the digestive canal sections revealed disappearance of brush border of epithelial cells (Fig. 9) and necrosis (Fig. 10), whereas, after 2 weeks of exposure showed degeneration of epithelial cells, loss of epithelial tissues and necrosis (Fig. 11, 12) and hypertrophy of epithelial tissue (Fig. 13).

Prostate gland: Figure 14 was showed the normal tissue of prostate gland. Also this gland of snail did not show any histopathological changes after 48 h of exposure. While, after the chronic exposure, the gland tissues appeared obvious histopathological changes which, represented by dilation in alveolar of prostate gland with metaplasia of epithelial tissue of alveolar (Fig. 15).

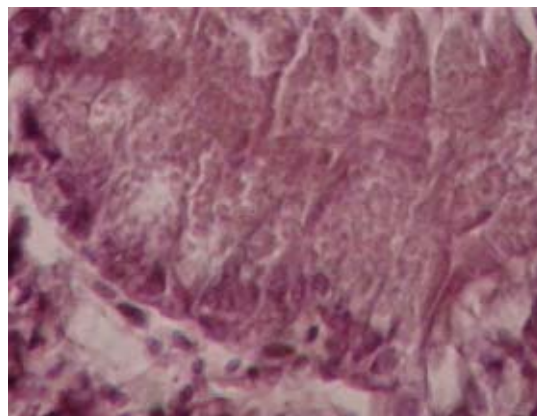


Fig. 2: Image of control group show hepatopencreas of fresh water snail *L. auricularia* 400x

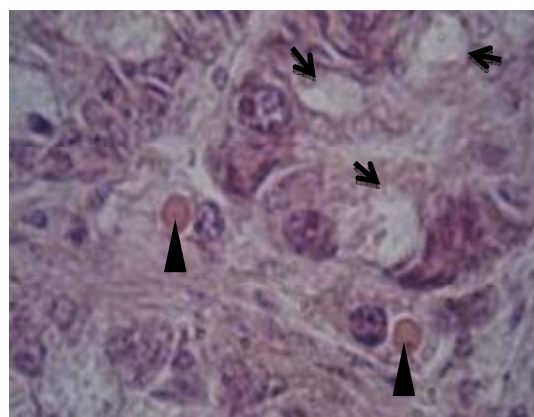


Fig. 3: Image of hepatopencreas of snail *L. auricularia* at acute exposure of microcystin extract ($7.5 \mu\text{g L}^{-1}$) of alga *H. aureus* show degeneration (short arrow) and aggregation of non-living components in the cytoplasm epithelial tissue of hepatopencreas (head arrow) 400x

DISCUSSION

There are several national and international studies drew attention to some famous genus and species of blue-greens algae which producing liver toxins (Microcystins) such as *Microcystis aeruginosa*, *M. flos-aque*, *Calothrix parietina*, *Nostoc muscurum*, *N. carneium*, *Hapalosiphon welwitschii*, *Oscillatoria agardhii* and *Anabaena circinalis*^{11-13,46-49}. So, the current study was focused on the diagnosis of this species of filamentous blue-green alga *H. aureus* and state the ability to producing hepatotoxin (Microcystin). In addition to

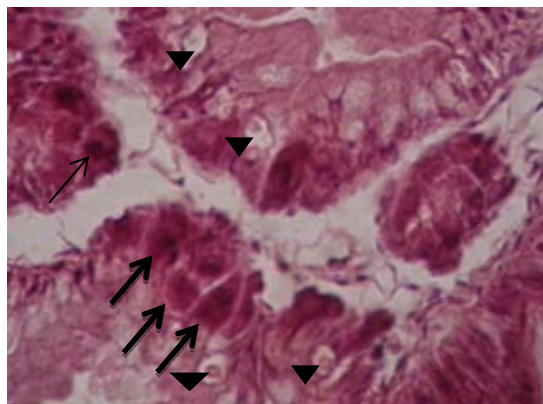


Fig. 4: Image of hepatopancreas of snail *L. auricularia* at chronic exposure of microcystin extract ($7.5 \mu\text{g L}^{-1}$) of alga *H. aureus* show aggregation of non-living components in the epithelial tissue of hepatopancreas (head arrow) and hyperchromic (arrow) 400x

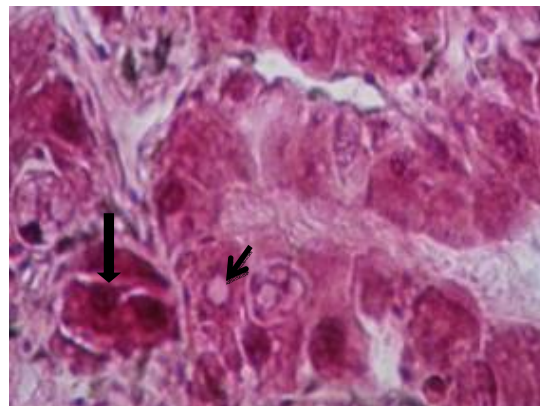


Fig. 6: Image of hepatopancreas of snail *L. auricularia* at chronic exposure of microcystin extract ($7.5 \mu\text{g L}^{-1}$) of alga *H. aureus* show necrosis the epithelial cells (short arrow) and hyperchromic (big arrow) 400x

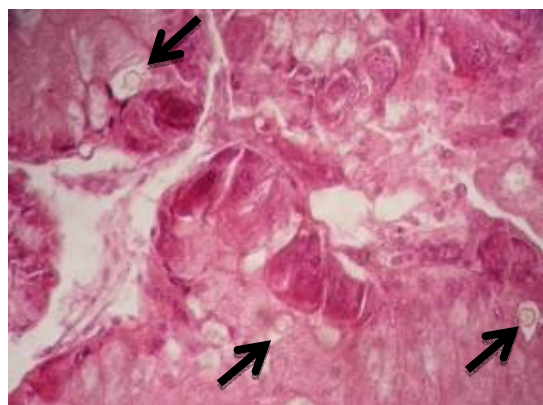


Fig. 5: Image of hepatopancreas of snail *L. auricularia* at chronic exposure of microcystin extract ($7.5 \mu\text{g L}^{-1}$) of alga *H. aureus* show necrosis the epithelial cells after aggregation of non-living components (arrow) 400x

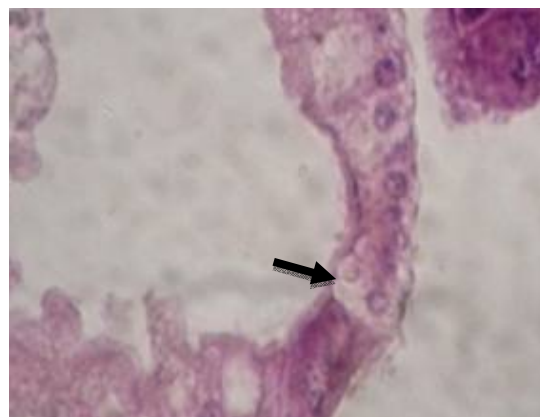


Fig. 7: Image of hepatopancreas of snail *L. auricularia* at chronic exposure of microcystin extract ($7.5 \mu\text{g L}^{-1}$) of alga *H. aureus* show degeneration the epithelial cells (arrow) 400x

investigate the histopathological effects of this toxin extract on some tissues of fresh water snail *L. auricularia* in Basra Southern of Iraq. The results was showed the ability of alga *H. aureus* to produce a high concentration of hepatotoxin type microcystin which reached to $50.332 \mu\text{g g}^{-1}$ from lyophilized dry weight. This concentration of toxin is considered high when compare with previous mentioned species which reached¹² between ($37.7-44.41 \mu\text{g g}^{-1}$) and less than the toxin concentration found in *Nostoc carneum* reach⁵⁰ to $50.67 \mu\text{g g}^{-1}$.

Several studies was observed histopathological and physiological effects of microcystins on laboratory mice⁵¹⁻⁵³

and on fishes^{12,47-50,54-56} but a few studies examined the toxicity of cyanobacteria on mollusks^{57,58}. The present findings shed light on some of the histopathological effects caused by microcystin producing from filamentous blue-green alga *H. aureus* on important gastropod *L. auricularia*. Therefore, this results may give an interesting indication to the ecological benefits of this algal species, because this snail is an environmental and medical important as it is considered an intermediate host of *Fasciola* and *Shistosoma* which cause rashes to swimmers³⁵. Furthermore, the gastropods play the important role in structuring fresh water communities as herbivorous grazers and preys of numerous predators⁵⁹. So, this highly toxicity of this alga may causes negative impact on

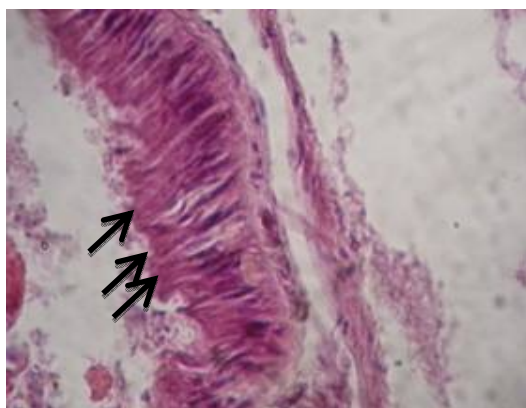


Fig. 8: Image control group show intestine of snail *L. auricularia* 400x

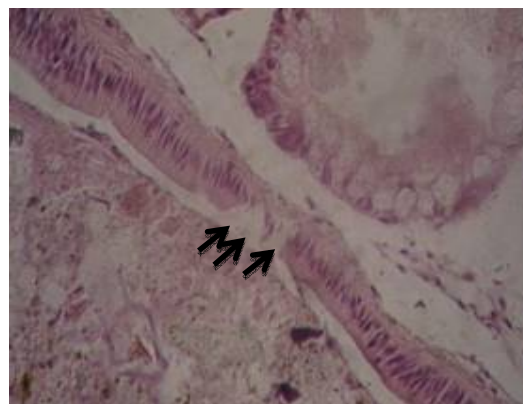


Fig. 10: Image of intestine of snail *L. auricularia* show necrosis epithelial cells at acute exposure of microcystin extract ($7.5 \mu\text{g L}^{-1}$) of alga *H. aureus* 400x

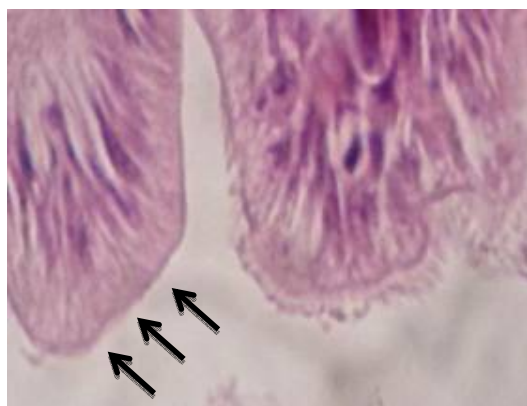


Fig. 9: Image of intestine of snail *L. auricularia* show disappearance of brush border of epithelial tissue at acute exposure of microcystin extract ($7.5 \mu\text{g L}^{-1}$) of alga *H. aureus* 1000x

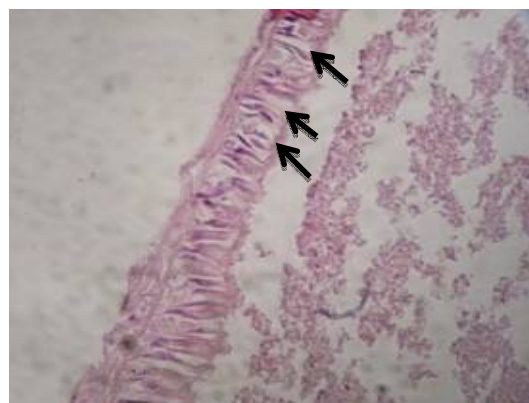


Fig. 11: Image of intestine of snail *L. auricularia* at chronic exposure of microcystin extract ($7.5 \mu\text{g L}^{-1}$) of alga *H. aureus* show degeneration of epithelial tissue and loss 400x

gastropods may have a potential cascading effects on the equilibrium and functioning of ecosystem⁵⁸.

Findings showed some histopathological changes in hepatopencreas of snail in acute exposure and these changing became more apparent with increasing of period exposure which represented by necrosis, degeneration aggregation of non-living things and hyper pigmentation. This results agree in some effects of MCs with several studies on fish and mice^{51,55,60}. Hepatotoxicity is primary effects when exposed to microcystins because this toxin are active transported via organic anion transporters and concentrate in liver cells. The toxicity of microcystins results from the inhibition of the catalytic subunit of protein phosphatase 1 and 2A which play an important role in balance of phosphorylation and

dephosphorylation of structural proteins in the cells. These effects of microcystins was led to hyperphosphorylation of cytoskeletal proteins which causes the deformation of hepatocytes⁶¹. This initial rapid response of hepatocytes to microcystin exposure represented by cell deformation caused by disruption of the cytoskeletal as a results of hyperphosphorylation of proteins. Moreover, hepatotoxins cause disruption of liver texture by hypovolemic shock and excessive blood bleeding in the liver⁶¹⁻⁶⁴.

The exposure to microcystin extract showed a large histopathological impacts on intestine represented by disappearance of brush border of epithelial cells and hypertrophy which were not observed in previous studies,

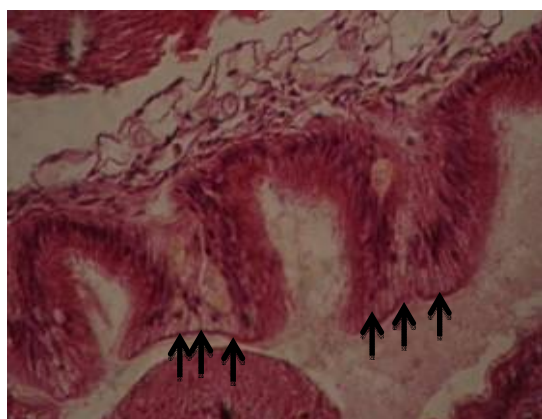


Fig. 12: Image of intestine of snail *L. auricularia* show necrosis of epithelial tissue at chronic exposure of microcystin extract ($7.5 \mu\text{g L}^{-1}$) of alga *H. aureus* 400x

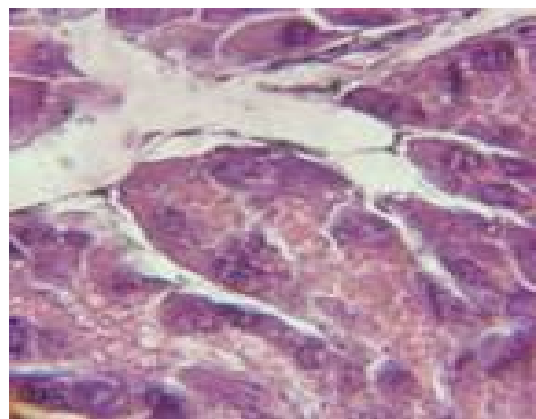


Fig. 14: Image control group show prostate gland of snail *L. auricularia* 400x

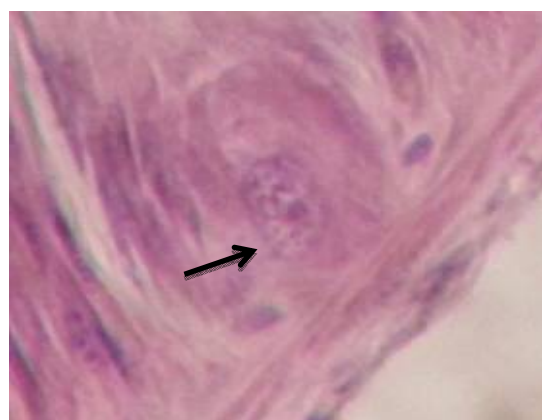


Fig. 13: Image of intestine show hypertrophy of epithelial tissue of intestine of snail *L. auricularia* at chronic exposure of microcystin extract ($7.5 \mu\text{g L}^{-1}$) of alga *H. aureus* 400x

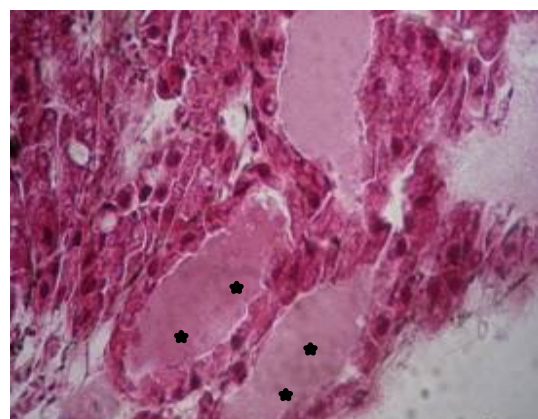


Fig. 15: Image of prostate gland show dilation of alveolar (stars) and metaplasia of epithelial tissues of snail *L. auricularia* at chronic exposure to microcystin extract ($7.5 \mu\text{g L}^{-1}$) of alga *H. aureus* 400x

while other effects match with earlier studies especially after 2 weeks of exposure to the microcystin extract which causing widespread cell lysis and necrosis, these effects can be attributed to the co-localized with strong presence of covalently bound MCs and inhibit the activity of PP1 and PP2A in any eukaryotic cells and their inhibition leads to hyperphosphorylation of cytoskeletal proteins⁶⁴. Similar pathological changes were already described for *L. stagnalis* was exposed to dissolved MC-LR³⁰ and fish fed with MC-producing cyanobacteria¹³. Lance *et al.*⁵⁷ found that snail *L. stagnalis* when exposed to MC-LR or to toxic cyanobacteria showed a diminution of the digestive epithelium area, because the

digestive epithelium tissues contains glycogen stores that can be mobilized by this snail during starvation or toxin exposure.

Prostate gland showed less effect than other organs or tissues in snail through a acute exposure, while the adverse effects were observed after 2 weeks of exposure, so this results did not found in previous studies which represented by dilation in alveolar and metaplasia of epithelial tissue of gland. Moreover, whatever intoxication route of MCs occurred in the genital gland including spermatozoid and oocytes (immature and mature) and the genital glands are known to be the second major site of MC accumulation in gastropods after the digestive gland²³⁻²⁵. Finally, freshwater snails as primary

consumers, constitute an important link between primary producers (potentially toxic cyanobacteria) and higher consumers such as crayfish, fish, water fowl⁶¹ which they can represent an intoxication route to predators in food web. Intoxication of mollusks may occur via feeding on toxic cyanobacteria and absorption of cyanotoxins dissolved in water or adsorbed on food particles. Consumption of toxic cyanobacteria and absorption of dissolved MC were experimentally demonstrated in gastropods, resulting in MC accumulation and detrimental effects on life traits^{27,28,65,66}.

CONCLUSION

The current study was showed diagnosis and classified a new toxic blue-green alga *H. aureus* which found in Al-Ashar river in Basra Governorate Southern of Iraq. Therefore this alga is considered know a toxic alga and it has the ability to produce the hepatotoxin (Microcystins) with highly concentration. Also, the low concentration of its microcystin extract $7.5 \mu\text{g L}^{-1}$ was led to several histopathological changes in some important organs hepatopencreas, intestine and prostate gland of snail *L. auricularia* in acute and chronic exposures. So this results which revealed that the toxic effect may be transferred to another organisms in the food chain down to human due to accumulation of toxins in snail tissues. This toxic effects of alga may be using as biological control to eliminate the snail because it considered an intermediate host of several parasites.

SIGNIFICANT STATEMENTS

This study have included isolation and purification of new species of blue-green algae *Hapalosiphon aureus* from Al-Ashar river at Basra Southern of Iraq.

An evaluation of his toxic effects against fresh water snail *Lymnaea auricularia*. This alga showed its ability to produce microcystin in high concentration reach to $52.33 \mu\text{g g}^{-1}$. This study have confirmed that this alga has ability to produce hepatotoxins (Microcystins).

This study may be considered as a first study in Iraq and in the world about this species. In addition, the microcystin extract at low concentration $7 \mu\text{g L}^{-1}$ of this alga was led to several histopathological effects on snail, these effects can be transmitted to human through food chain.

ACKNOWLEDGMENT

This study was sponsored by Basra University, College of Education For Pure Science. The author would like to thank Ali Abdul Latif Al-Ali (Biology Department/College of Education for Pure Sciences/University of Basra/Iraq) for his help in diagnosis of histopathological effects. Special thanks for Murtada Yousif AL-Abad (Biology Department/College of Education for Pure Sciences/University of Basra/Iraq) for his technical efforts in snail classification.

REFERENCES

1. Garcia-Pichel, F., J. Belnap, S. Neuer and F. Schanz, 2003. Estimates of global cyanobacterial biomass and its distribution. *Algological Stud.*, 109: 213-227.
2. Haande, S., 2008. On the ecology, toxicology and phylogeny of cyanobacteria in Murchison Bay of Lake Victoria, Uganda. Ph.D. Thesis, University of Bergen, Norway.
3. Okello, W., C. Portmann, M. Erhard, K. Gademann and R. Kurmayer, 2010. Occurrence of microcystin-producing cyanobacteria in Ugandan freshwater habitats. *Environ. Toxicol.*, 25: 367-380.
4. Hitzfeld, B.C., S.J. Hoger and D.R. Dietrich, 2000. Cyanobacterial toxins: Removal during drinking water treatment and human risk assessment. *Environ. Health Perspectives*, 108: 113-122.
5. Briand, J.F., S. Jacquet, C. Bernard and J.F. Humbert, 2003. Health hazards for terrestrial vertebrates from toxic cyanobacteria in surface water ecosystems. *Vet. Res.*, 34: 361-377.
6. Chorus, I. and J. Bartram, 1999. Toxic Cyanobacteria in Water: A Guide to Their Public Health Consequences, Monitoring and Management. CRC Press, London, UK, ISBN-13: 9780419239307, pp: 41-111.
7. Paerl, H.W., R.S. Fulton, P.H. Moisander and J. Dyble, 2001. Harmful freshwater algal blooms, with an emphasis on cyanobacteria. *Scient. World J.*, 1: 76-113.
8. Zurawell, R., H. Chen, J. Burke and E. Prepas, 2005. Hepatotoxic cyanobacteria: A review of the biological importance of microcystins in freshwater environments. *J. Toxicol. Environ. Health Part B: Crit. Rev.*, 8: 1-37.
9. Botes, D.P., H. Kruger and C.C. Viljoen, 1982. Isolation and characterization of four toxins from the blue-green alga, *Microcystis aeruginosa*. *Toxicon*, 20: 945-954.
10. Carmichael, W.W., J.T. Eschdor, G.M. Patterson and R.E. Moore, 1988. Toxicity and partial structure of a hepatotoxic peptide produced by the cyanobacterium *Nodularia spumigena* Mertens emend. L575 from New Zealand. *Applied Environ. Microbiol.*, 54: 2257-2263.

11. Al-Aarajy, M.J. and E.Y.A. Al-Sultan, 2008. Effects of some toxic microalgae on larval stage of the common carp (*Cyprinus carpio* L.) and silver carp (*Hypophthalmichthys molitrix*). *Basrah J. Agric. Sci.*, 23: 67-87.
12. Al-Sultan, E.Y.A., 2007. Bioassay of some toxic microalgae. Ph.D. Thesis, College of Education, University of Basrah, Iraq.
13. Al-Sultan, E.Y.A., 2011. The isolation, the purification and the identification of hepatotoxin microcystin-LR from two cyanobacterial species and studying biological activity on some aquatic organisms. *J. Basrah Res. Sci.*, 37: 39-57.
14. Dietrich, D. and S. Hoeger, 2005. Guidance values for microcystins in water and cyanobacterial supplement products (blue-green algal supplements): A reasonable or misguided approach? *Toxicol. Appl. Pharmacol.*, 203: 273-289.
15. Ross, C., L. Santiago-Vazquez and V. Paul, 2006. Toxin release in response to oxidative stress and programmed cell death in the cyanobacterium *Microcystis aeruginosa*. *Aquat. Toxicol.*, 78: 66-73.
16. Vasconcelos, V., 2006. Eutrophication, toxic cyanobacteria and cyanotoxins: When ecosystems cry for help. *Limnetica*, 25: 425-432.
17. Amorim, A. and V. Vasconcelos, 1999. Dynamics of microcystins in the mussel *Mytilus galloprovincialis*. *Toxicon*, 37: 1041-1052.
18. Malbrouck, C. and P. Kestemont, 2006. Effects of microcystins on fish. *Environ. Toxicol. Chem.*, 25: 72-86.
19. Ibelings, B.W. and I. Chorus, 2007. Accumulation of cyanobacterial toxins in freshwater seafood and its consequences for public health: A review. *Environ. Pollut.*, 150: 177-192.
20. Martins, J.C. and V.M. Vasconcelos, 2009. Microcystin dynamics in aquatic organisms. *J. Toxicol. Environ. Health B Crit. Rev.*, 12: 65-82.
21. Kotak, B.G., R.W. Zurawell, E.E. Prepas and C.F.B. Holmes, 1996. Microcystin LR concentration in aquatic food web compartments from lakes of varying trophic status. *Can. J. Fisher. Aquat. Sci.*, 53: 1974-1985.
22. Zurawell, R.W., B.G. Kotak and E.E. Prepas, 1999. Influence of lake trophic status on the occurrence of microcystin-LR in the tissue of pulmonate snails. *J. Freshwater Biol.*, 42: 707-718.
23. Chen, J., P. Xie, L. Guo, L. Zheng and L. Ni, 2005. Tissue distributions and seasonal dynamics of the hepatotoxic microcystins-LR and -RR in a freshwater snail (*Bellamya aeruginosa*) from a large shallow, eutrophic lake of the subtropical China. *Environ. Pollut.*, 134: 423-430.
24. Xie, L., A. Yokoyama, K. Nakamura and H. Park, 2007. Accumulation of microcystins in various organs of the freshwater snail *Sinotaia histrica* and three fishes in a temperate lake, the eutrophic Lake Suwa, Japan. *Toxicon*, 49: 646-652.
25. Zhang, D., P. Xie, Y. Liu, J. Chen and G. Liang, 2007. Bioaccumulation of the hepatotoxic microcystins in various organs of a freshwater snail from a subtropical Chinese lake, Taihu Lake, with dense toxic *Microcystis blooms*. *Environ. Toxicol. Chem.*, 26: 171-176.
26. Gerard, C., A. Carpentier and J.M. Paillisson, 2008. Long-term dynamics and community structure of freshwater gastropods exposed to parasitism and other environmental stressors. *J. Freshwater Biol.*, 53: 470-484.
27. Gerard, C., L. Brient and B. Le Rouzic, 2005. Variation in the response of juvenile and adult gastropods (*Lymnaea stagnalis*) to cyanobacterial toxin (microcystin-LR). *J. Environ. Toxicol.*, 20: 592-596.
28. Lance, E., L. Brient, M. Bormans and C. Gerard, 2006. Interactions between cyanobacteria and gastropods: I. Ingestion of toxic *Planktothrix agardhii* by *Lymnaea stagnalis* and the kinetics of microcystin bioaccumulation and detoxification. *Aquat. Toxicol.*, 79: 140-148.
29. Zurawell, R.W., C.F. Holmes and E.E. Prepas, 2006. Elimination of the cyanobacterial hepatotoxin microcystin from the freshwater pulmonate snail *Lymnaea stagnalis jugularis* (Say). *J. Toxicol. Environ. Health Part A*, 69: 303-318.
30. Zurawell, R.W., J.I. Goldberg, C.F.B. Holmes and E.E. Prepas, 2007. Tissue distribution and oral dose effects of microcystin in the freshwater pulmonate snail *Lymnaea stagnalis jugularis* (Say). *J. Toxicol. Environ. Health Part A*, 70: 620-626.
31. Clench, W.L., 1959. Mollusca. In: *Fresh Water Biology*, Edmondson, T.W. (Ed.). 2nd Edn., John Wiley and Sons Inc., New York, pp: 1117-1160.
32. Al-Hussain, R.A.H., 1997. Study of larval stage of digeniatrematode on snails of several Shutt al-Arab branches and physiological effects of parasite *Ornithobilharzia trunc estanicum* in laboratory rabbit. M.Sc. Thesis, Science College/Basrah University, Iraq.
33. Al-Abbad, M.Y., 2009. Identification and biology of species *Chaetogaster limnaeivon* Baer 1827 (Oligochaeta: (Naididae) Isolated from some Basra marshes in the South of Iraq. Ph.D. Thesis, College of Education, University of Basrah, Iraq.
34. Sailm, A., 1986. Epidemiological study of liver helix *Fasciola gigantica* in snail *Lymnaea auricularia* in some Shut-Alarab branches. M.Sc. Thesis, Science College, Basrah University, Iraq.
35. Chandler, A.C. and C.P. Read, 1961. *Introduction of Parasitology*. 10th Edn., John Wiley and Sons, New York, Pages: 822.
36. Stein, J.R., 1975. *Handbook of Phycological Methods: Culture Methods and Growth Measurements*. Cambridge University Press, Cambridge, Pages: 448.
37. Wiedeman, V.E., P.L. Walne and F.R. Trainor, 1964. A new technique for obtaining axenic cultures of algae. *Can. J. Bot.*, 42: 958-959.

38. Desikachary, T.V., 1959. Cyanophyta. 1st Edn., Indian Council of Agriculture Research, New Delhi, India, Pages: 686.
39. Prescott, G.W., 1975. Algae of the Western Great Lake Area. 6th Edn., William C. Brown Co. Publishers, Dubuque, Iowa, Pages: 977.
40. Harada, K.I., H. Nagai, Y. Kimura, M. Suzuki and H.D. Park *et al.*, 1993. Liquid chromatography/mass spectrometric detection of anatoxin-a, a neurotoxin from cyanobacteria. *Tetrahedron*, 49: 9251-9260.
41. Park, H.D., B. Kim, E. Kim and T. Okino, 1998. Hepatotoxic Microcystins and Neurotoxic Anatoxin-a in Cyanobacterial Blooms from Korean Lakes. John Wiley and Sons, New York, pp: 225-235.
42. Weller, M.G., A. Zeck, A. Eikenberg, S. Nagata, Y. Ueno and R. Niessner, 2001. Development of a direct competitive microcystin immunoassay of broad specificity. *Anal. Sci.*, 17: 1445-1448.
43. Metcalf, J.S., K.A. Beattie, S. Pflugmacher and G.A. Codd, 2000. Immuno-crossreactivity and toxicity assessment of conjugation products of the cyanobacterial toxin, microcystin-LR. *FEMS Microbiol. Lett.*, 189: 155-158.
44. Ahmed, M.M., 1975. Systematic study on mollusca from Arabian Gulf and Shatt Al-Arab, Iraq. Center for Arab Gulf Studies, University of Basrah, pp: 87.
45. Humason, G.L., 1972. Animal Tissue Techniques. 3rd Edn., W.H. Freeman and Co., San Francisco, Pages: 614.
46. Runnegar, M.T., I.R. Falconer and J. Silver, 1981. Deformation of isolated rat hepatocytes by a peptide hepatotoxin from the blue-green alga microcystis aeruginosa. *Naunyn Schmiedeberg's Arch Pharmacol.*, 317: 268-272.
47. Al-Sultan, E.Y.A. and A.A.A. Al-Ali, 2010. Histopathological effect biological effects of toxic alga Hapalosiphon Welwitschii on molly fish *Poecilia sphenopsis* Valenciennes. *J. Agric. Sci.*, 23: 169-185.
48. Al-Sultan, E.Y., A.A.A. Al-Ali and F.Y.A. Al-Sultan, 2011. Toxic effects of cyanobacterial alga *N. muscurum* on some physiological parameters in blood of *Ctenopharyngodon idella* Val. 1844. *J. Thi-Qar Sci.*, 3: 42-54.
49. Al-Ali, A.A.A., E.Y.A. Al-Sultan and F.A. Al-Sultan, 2011. Histopathological effects of toxic alga nostoc muscurum on juvenile grass carp fish (*ctenopharyngodon idella* Val. 1844). *J. Marsh Bull.*, 6: 32-61.
50. Talib, S.G., 2013. Comparative study of some organs for two osteichthyes fishes fed on blue-green alga Nostoc carneum (Agardh, 1884) producing microcystin. M.Sc. Thesis, Basrah University, College of Education for Pure Sciences, Biology Department, Iraq, pp: 161.
51. Kateregga, J.N., M. Babu, R. Abuine and J.G. Ndokui, 2014. Hematological and histopathological effects of cyanobacteria (Blue-Green Algae) from lake Victoria shores of Uganda in Swiss mice. *Int. J. Applied Sci. Technol.*, 4: 128-133.
52. Al-Sultan, E.Y.A., M.I. Abd Al Majeed and A.A.K. Abbas, 2015. Study of physiological and histological effects under very low concentration of cyanobacterial toxin MC-LR on lab. mice (*Mus musculus*). *Res. J. Pharm. Biol. Chem. Sci.*, 6: 1064-1072.
53. Abd Al-Majeed, M.I., E.Y. Al-Sultan and A.A.K. Abbas, 2016. Toxic effects of low concentration of cyanotoxin (Microcystin-LR). On mice and study of protective efficacy of the antioxidants vitamins (C and E) and *Capparis spinosa* L. root extract. *J. Nat. Sci. Res.*, 6: 34-42.
54. Rabergh, C.M.I., G. Bylund and J.E. Eriksson, 1991. Histopathological effects of microcystin-LR, a cyclic peptide toxin from the cyanobacterium (blue-green alga) Microcystis aeruginosa, on common carp (*Cyprinus carpio* L.). *Aquatic Toxicol.*, 20: 131-146.
55. Atencio, L., I. Moreno, A.I. Prieto, R. Moyano, A.M. Molina and A.M. Camean, 2008. Acute effects of microcystins MC-LR and MC-RR on acid and alkaline phosphatase activities and pathological changes in intraperitoneally exposed tilapia fish (*Oreochromis* sp.). *Toxicol. Pathol.*, 36: 449-458.
56. Panagiotis, B., P. Theodoti, P. Evi, K. Konstantinos and K. Ifigenia, 2014. Brain and liver histopathological examination of Carassius gibelio from a newly reconstructed lake with toxic cyanobacteria. *Turk. J. Fisher. Aquat. Sci.*, 14: 213-219.
57. Gerard, C., V. Poullain, E. Lance, A. Acou, L. Briant and A. Carpentier, 2009. Influence of toxic cyanobacteria on community structure and microcystin accumulation of freshwater molluscs. *Environ. Pollut.*, 157: 609-617.
58. Lance, E., C. Josso, D. Dietrich, B. Ernst and C. Paty *et al.*, 2010. Histopathology and microcystin distribution in *Lymnaea stagnalis* (Gastropoda) following toxic cyanobacterial or dissolved microcystin-LR exposure. *Aquat. Toxicol.*, 98: 211-220.
59. Dillon, R.T., 2000. Gastropods Autecology. In: The Ecology of Freshwater Molluscs, Dillon, R.T. (Ed.). Cambridge University Press, Cambridge, ISBN: 0-521-35210-X, pp: 57-116.
60. Rangel, M., J.C. Martins, A.N. Garcia, G.A. Conserva, A. Costa-Neves, C.L. Sant'Anna and L.R. de Carvalho, 2014. Analysis of the toxicity and histopathology induced by the oral administration of *Pseudanabaena galeata* and *Geitlerinema splendidum* (Cyanobacteria) extracts to mice. *Mar. Drugs*, 12: 508-524.
61. Falconer, I.R., 2005. Cyanobacterial Toxins in Drinking Water Supplies: Cylindrospermopsins and Microcystins. CRC Press, Boca Raton, Florida, Pages: 279.
62. Carmichael, W.W., 1992. Cyanobacteria secondary metabolites-the cyanotoxins. *J. Applied Bacteriol.*, 72: 445-459.

63. Ransom, R., F.J. San Soong, L. Fitzgerald, O. Turczynowicz and D. Elsaadi *et al.*, 1994. Health Effects of Toxic Cyanobacteria (Blue-Green Algae). Australian Government Publishing Service, Canberra, pp: 27-69.
64. Fladmark, K.E., O.T. Brustugun, R. Hovland, R. Boe, B.T. Gjertsen, B. Zhivotovsky and S.O. Doskeland, 1999. Ultrarapid caspase-3 dependent apoptosis induction by serine/threonine phosphatase inhibitors. *Cell Death Differ.*, 6: 1099-1108.
65. Gerard, C. and V. Poullain, 2005. Variation in the response of the invasive species *Potamopyrgus antipodarum* (Smith) to natural (cyanobacterial toxin) and anthropogenic (herbicide atrazine) stressors. *Environ. Pollut.*, 138: 28-33.
66. Lance, E., C. Paty, M. Bormans, L. Brient and C. Gerard, 2007. Interactions between cyanobacteria and gastropods II. Impact of toxic *Planktothrix agardhii* on the life-history traits of *Lymnaea stagnalis*. *Aquat. Toxicol.*, 81: 389-396.