BJS

BJS, September 4,1998
Current Concept

CURRENT MANAGEMENT OF INGUINAL HERNIA

Mazin H. Al-Hawaz* & Yaseen Malalla@

*Arab Board Certified Surgeon, Assistant Professor of Surgery, University of Basrah College of Medicine and Specialist Surgeon, Basrah General Hospital. @FRCS, Consultant Surgeon and Director, Basrah Military Hospital. Basrah, IRAQ.

Summary *Concepts in the epidemiology, pathophysiology, classification and surgical treatment of inguinal hernia in the last decade have been revolutionized. Recent reports have documented the safety and efficacy of laparoscopic hernia repair using pdypropylene mesh. However, there is concern regarding the use of polypropylene mesh in young adults with small hernias. Individual laproscopic hernia repair is proposed according to the Nyhus hernia classification.*

Introduction

Thousands of inguinal hernia are diagnosed and treated each year with over all recurrent rate of 10-15%. The high incidence of this disease makes inguinal hernia repair the most frequent procedure in general surgery, accounting for 10-15% of all operations[1]. Incidence of inguinal hernia is race related. Grion hernias are at least three times more common in black Africans than in the white population. About 80-90% of repairs are done in males, the most frequent type (about 30%) being the right indirect inguinal hernia[2]. The integrity of the abdominal wall is dependent on the oblique orientation of the inguinal canal, a sphincter-like structure of the internal ring, and the transversalis fascia. All groin hernias represent a defect of the transversalis fascia[3]. Generally the diagnosis of groin hernia implies surgical repair. Therefore, elective repair of a diagnosed inguinal hernia should done as early as possible. Surgery should be only postponed for proper assessment and improvement of underlying risk factors and concomitant disease[2]. Inguinal hernia repair has undergone various stages of development. Several types of repair are now available to the surgeon. Better under standing of the anatomy, the development of various sutures and synthetic materials, introducing laparoscopy and proper long term follow up had clarified many aspects concerning the management of this common condition. The large number of methods for inguinal hernia repair has been further increased by the introduction of mesh techniques and laproscopic approaches. However, these developments have contributed to the uncertainty about the ideal method of repair. Grieteria for choice are safety, convenience for the patient and recurrence rate. Most of published studies are unreliable because of inadequate length of follow up or the patients lost to follow up[1,4,5]. Within these limitations the technique introduced by Shouldice in 1945 can be regarded as the gold standard of open hernia repair, with recurrent rate of 0.5 to 2.8% after follow up of more than 5 years[6,7]. The technique for Shouldice repair include

1. Division of the cremaster muscle: complete exposure of the posteriors wall of the canal and the internal ring can be achieved by resection of the cremaster muscle.
2. Incision and repair of the transversalis

Correspondence to:
Mazin Al-Hawaz
Department. Of Surgery. University of Basrah
College of Medicine. IRAQ.

fascia: a running suture with doubling of the fascia will result in a dynamic closure of the posterior wall with negligible suture tension.

In the USA especially, the use of prosthetic meshes is gaining popularity. The so called "tension free" mesh repair has been used with low recurrence rate that rival the Shouldice repair[8,9]. In Europe the Stoppa procedure with preperitoneal mesh implantation has produced good results, especially in cases of multiple recurrences[10]. However, Stoppa himself limits his procedure to patients above 50 years of age because of unknown long term fate and side-effects of the implanted mesh material. Indeed, almost nothing is known about the biological compatibility of these materials in the very long term. Therefore, the use of meshes can only be recommended when the inguinal ligament or transversalis fascia is unusually weak. The mesh should be placed in the preperitoned plane, and its dimension must be large enough for generous coverage of the defect and all hernial orifices. With respect to tissue reaction and durability, knitted polypropylene is currently the prosthesis most widely advocated[11].

Lapraoscopic hernia repair has been developed with various techniques (table 1)[12].

Technique	*Follow up in month*	*Recurrence rate %*
Suture/Clip	24	2.0
Plug/Patch	8	>10.0
Transperitoneal mesh	5	0.9
Pre peritoneal mesh	7	0-0.9

Table 1. Results of Laparoscopic hernia repair with various techniques

Clip and Plug procedures are obsolete because of their high recurrence rate. The technically most sound procedure is the placement of a large mesh prosthesis in the preperitoned space[9]. The laparosco pic approach to the preperitoneal space can be either transabdominal (thereby transforming the hernia repair into an intraperitoneal procedure) or preperitoneal. Early results are encouraging with both techniques being associated with low recurrence rates(0% to 2%) comparable to the best reported for standard open repair (Shouldice). Indications for the endoscopic approach are multiple recurrence and bilateral hernias especially in the elderly. In younger patients the conventional Shouldice technique or

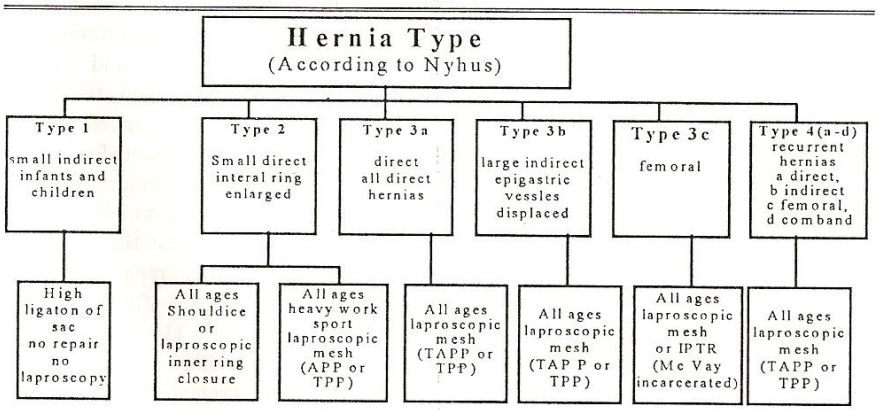

Fig I: Hernia classification according to Nyhus and proposed hernia repair.
TAPP-Trans abdominal preperitonal; TPP=Total preperitoneal; IPTR= Iliopubic tract repair.

inner ring closure seems to be procedure of choice. Fig 1. The laproscopic technique is performed under local, regional and general anaesthesia. No gastric tube or Foley Catheter in the bladder was used except for bilateral hernias when a Foley catheter was inserted. Surgery was covered by a single shot prophylactic antibiotic. The preperitonenl space is created through a 12mm subumbilical incision and dissection is performed under visual control using the Oscope as a blunt dissector. Two additional working parts (10 and 12 mm) are inserted. First, the pelvic floor was inspected in both sides in order to classify the hernia. After dissection of hernial sac, the sac was reduced but not resected except in large hernia. In young adults with type 2 hernias, the inner ring was normally closed with 2-3 non-absorbable sutures without inserting the mesh. In all type 3 and 5 hernias, poly propylene mesh was placed, covering all hernia orifices and inguinal floor and fixed by staples or sutures. In all patients adrain is placed in the preperitoneal space and taken out 24 hrs. after operation. The main complications for the procedure were urinary retention neurological complication due to involvement of ilioinguinal ∞ genitofemenal nerve, trocar hematoma and trocar hernia[11,12].

Over view

-The diagnosis of inguinal hernia indicates surgery.

-The Shouldice procedure is the gold standard and indicated for all patients with primary hernias and those younger than 60 years with recurrent inguinal hernias.

-In patients older than 60 years with bilateral or recurrent hernias, prosthetic reinforcement of the inguinal wall can be considered.

-The mesh repair can be carried out as an open procedure (either unilateral or bilateral) or with apreperitoneal laparo scopic approach.

-Short-term and long-term safety and reliability of laparscopic hernia repair must still be proven.

References

1. Lichtenskein IL, Shulman AG, Amid PK. The cause, prevention and treatment of recurrent groin hernia. Surg Clin North Am. 1993; **73:** 529-44.
2. Rutkow IM, Robbins AW. Demographic, classificatory, and socioeconomic aspects of hernia repair in the United States. Surg Clin North Am. 1993; **73:** 413-26.
3. Lovett J, Kirgan D, McGregor B. Ingunial herniation justifies sigmoidoscopy. Am J Surg. 1989; **158:** 615-17.
4. Rutledge RH. The cooper ligament repair. Surg Clin North Am. 1993; 73: 471-85.
5. Schaap HM, Vandepavoordt HDWM. The preperitoneal approach in the repair of recurrent inguinal hernias. Surg Gynecol Obstrt. 1992; **174:** 460-64.
6. Berliner SD. An approach to groin hernia. Surg Clin North Am. 1984; **64:** 197.
7. Wantz GE. The Canadian repair: personal observations. World J Surg. 1989; **13:** 516-21.
8. Amid PK, Shulman AG, Lichtenstein IL. Critical scruting of the open "tension free" hernioplasty. Am J Surg. 1993; **165:** 369-71.
9. Shulman AG, Amid PK, Lichtenstein IL. The safety of mesh repair for primary inguinal hernias: results of 3,019 operations from five diverse surgical sources. Am Surg. 1992; **58:** 255-57.
10. Stoppa RE. The treatment of complicated groin and incisional hernias. World J Surg. 1989; **13:** 515-54.
11. Horton MD, Florence MG. Simplified preperitoneal marlex hernia repair. Am J Surg. 1993; **165:** 595-99.
12. MacFadyen BV, Arregui ME. Complications of laproscopic herniorraphy. Surg Endosc. 1993; 7: 155-58.