

## **Comparative studies between propolis, dexametason and gentamycin treatments of induced corneal ulcer in rabbits**

**A. A. Alfaris<sup>1</sup>, R. K. Abdulsamad<sup>1</sup> and A. A. Swad<sup>2</sup>**

<sup>1</sup>Department of Veterinary Internal and Preventive Medicine, Surgery & Obstetrics, <sup>2</sup> Department of Anatomy, College of Veterinary Medicine, University of Basrah, Basrah, Iraq

### **Abstract**

The aim of this study was to investigate the effect of dexamethasone, propolis and gentamicin in the treatment of experimental induced corneal ulcer in rabbit. A bilateral corneal ulcer burn was induced by a filter paper disk (5mm diameter) immersed in 1N NaOH and then put it for 30 seconds on the central axis of corneas in 80 rabbits. These animals were divided equally into four groups. The corneal ulcers were treated topically as follows: Animals of the first group (control group) treated with sterile normal saline; were the animals of the second group treated with dexamethasone 0.1% eye drops> Animals of the third group were treated with aqueous extract of propolis 1%; and the animals of the forth group were treated with gentamicin eye drops 0.3%. Drugs were instilled 2 times daily (every 12 hours) for 7 days. The clinical signs of corneal ulcer were evaluated by ophthalmoscope and fluorescent technique. After sacrificing the animals the corneas underwent routine histopathological examination on the day 1<sup>st</sup>, 3<sup>rd</sup>, 5<sup>th</sup> and 10<sup>th</sup> days after the treatments. The propolis and Dexamethasone show improvement in corneal ulcer, for the first 3 days after the injury and without any signs of complication, obvious conjunctival edema and eyelid swelling were observed in control and gentamicin groups. In control group became inflamed with pus formations while in propolis and gentamicin groups remained clear without pus. Histopathological examination reveals that the infiltration of inflammatory cells in both groups of dexamethasone and propolis were fewer when it compare with groups of control and gentamicin. These findings indicate that propolis may be an alternative to others treatment of corneal ulcer.

**Keywords:** Corneal ulcer, Treatment, Rabbit.

Available online at <http://www.vetmedmosul.org/ijvs>

### **دراسة مقارنة لاستخدام البروبوليز والديكساميثازون والجنتاميسين لعلاج قرحة العين المستحدثة في الارانب**

**عبد الباري ساهي الفارس<sup>١</sup> ، رنا خلف عبد السلام<sup>١</sup> وعلاء عبد الخالق سواد<sup>٢</sup>**

<sup>١</sup> فرع الطب الباطني والوقائي، الجراحة والتوليد، <sup>٢</sup> فرع التشريح، كلية الطب البيطري، جامعة البصرة، البصرة، العراق

### **الخلاصة**

ان الهدف من الدراسة هو لمعرفة تأثير عكبر العسل والديكساميثازون والجنتاميسين في علاج قرحة القرنية المستحدثة تجريبيا بواسطة هيدروكسيد الصوديوم بتركيز ١ نورمالتي على العين في الارانب. استحدثت قرحة القرنية بواسطة وضع أقراص ورق الترشيح (قطرها ٥ ملم) مشبعة بمادة هيدروكسيد الصوديوم وبتركيز ١ نورمالتي على القرنية لكلا العينين في ٨٠ أرنب لمدة ٣٠ ثانية. قسمت الارانب إلى أربع مجاميع: المجموعة الأولى (سيطرة) عولجت بالمحلول الملحي المتعادل المعقم و المجموعة الثانية عولجت بالديكساميثازون بتركيز ٠,١% و المجموعة الثالثة عولجت بالمستخلص المائي لعكبر العسل وبتركيز ١% اما المجموعة الرابعة عولجت بمحلول الجنتاميسين وبتركيز ٠,٣% بشكل قطرات للعين. أعطى العلاج مرتين باليوم ولمدة ٧ أيام. تم تقييم العلامات السريرية لقرحة العين بواسطة جهاز ناظور العين وتقنية الفلورسين. اخذت القرنية بعد قتل الحيوانات لغرض التقطيع النسيجي عند

اليوم ١، ٣، ٥ و ١٠ بعد العلاج. أظهر كل من الديكساميثازون وعكبر العسل تحسن في إصابات العين للأيام الثلاثة الأولى من الإصابة وبدون أي مضاعفات، شوهدت وذمة الملتحمة الواضح وتورم الجفون في مجاميع السيطرة والجنتاميسين بينما انعدمت هذه العلامات السريرية في مجاميع عكبر العسل والديكساميثازون. أظهرت القرنية في مجموعة السيطرة تكوين قرح بينما كانت القرنية واضحة وبدون قرح في مجاميع عكبر العسل والجنتاميسين. أظهر الفحص النسيجي المرضي، ارتشاح الخلايا الالتهابية في مجاميع الديكساميثازون وعكبر العسل وكانت أقل مقارنة مع مجاميع السيطرة والجنتاميسين. وهذه تعطي مؤشراً بإمكانية استخدام عكبر العسل كعلاج بديل لقرحة القرنية.

## Introduction

The cornea frequently undergoes external traumas that often lead to abrasions, lacerations and corneal ulcers, which interfere with the vision. Pathogens virus, bacteria and fungi cause corneal infection and ulceration that leading to corneal ulceration and corneal blindness. Corneal inflammation is one of the most common ocular diseases in both humans and animals and can lead to blindness or even cause lost of the eye itself (1,2). Corneal ulceration is an important cause of reduced vision. Thus, the severity of corneal lesions and their repair mechanisms during several morbid processes make necessary the fast institution of effective therapeutic measures. These are employed with the aim of avoiding the lesion progress, allowing a fast and appropriate healing with minimal scar formation, which can be achieved with clinical and surgical procedures. The institution of one or another treatment depends on the right diagnosis of the primary cause and on the analysis of secondary agents, besides the problem prognosis (3,4). Therefore, several researchers have studied the mechanisms of corneal healing in order to develop appropriate methods to treat corneal lesions, restoring its clearness and contributing to visual rehabilitation.

Propolis is a natural hive product collected from buds and produced by the honeybee. It has long been used by folk medicine. It has been proved on a scientific basis that it possesses versatile biological activities, including antimicrobial, anti inflammatory, regenerative and antioxidant (5,6). It has been found that propolis has a therapeutic effect on wound healing, infective wounds and inflammations of the skin and on other skin diseases. In addition, propolis has been proposed to have a therapeutic effect on chemical and thermal injuries of the cornea (7).

Thus we try to find simple and safe technique represent by using therapy with no side effects and because there isn't available references concerning such technique.

## Materials and methods

80 rabbits of both sexes weighing between 2.5-3.5 kg were used in this study. The rabbits were clinically healthy and kept in the cages at animal house, College of Veterinary Medicine, University of Basrah. All the rabbits

were treated with Ivermectin at dose rate of 0.2 mg/kg body weight subcutaneously. Food and water were given freely during the adaptation period. Rabbits were anesthetized by intramuscular injection of 10 mg/kg xylazine and 25 mg/kg ketamine HCl (8). The experiment was carried out on the both eye of each animal.

## Surgical Technique for Induce Ulcer

A round 5-mm diameter circular filter paper disk produced by standard paper bunch, this filter paper disk was immersed in 1 N NaOH for 5 second; filter paper (Whatman No.3) was used because it is easily molded to the cornea when wet. When the rabbit anesthetized the eyelid was secured in the open position using a wire lid speculum. The immersed filter paper disk was placed on the central corneal surface, centered on the pupil and held gently in position with thumb forceps for 30 second (9). Corneal ulcer induced bilateral in each rabbit (figure 1).

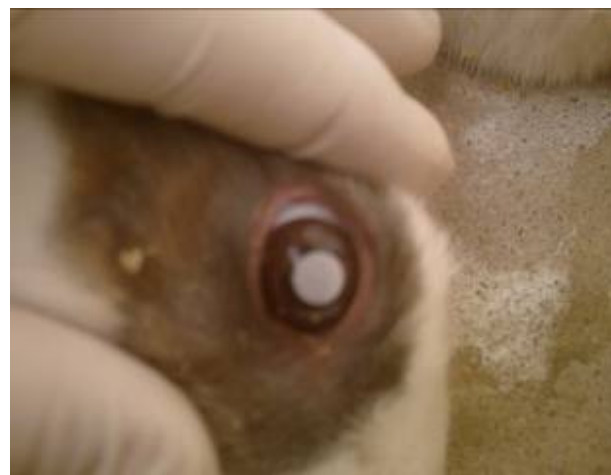

Figure 1: Induce alkali corneal injury.

## Fluorescent technique

A piece of blotting paper containing fluorescen dye will be touched to the surface of cornea. Blinking spreads the dye around and coats the "tear film" covering the surface of the cornea (figure 2). By ophthalmoscope a blue light is then directed at rabbit eye. The experimental ulcer on the

surface of the cornea will be stained by the dye and appear green under the blue light (figure 3). This test used to determine the size, location, and shape of corneal ulcer depending on the manner of spreading of the dye between the damaged tissues of cornea (10).

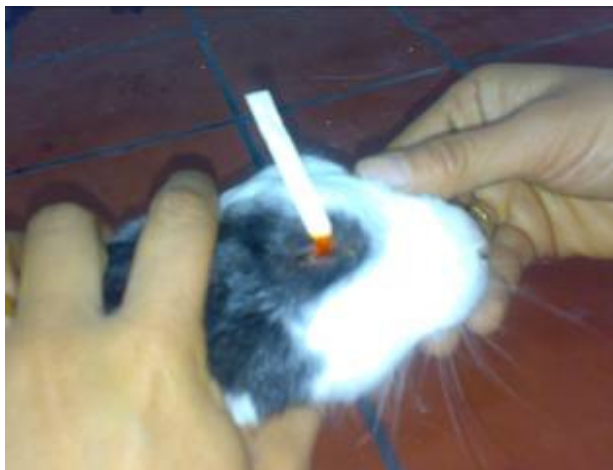

Figure 2: fluorescent strip put in eye after injury.

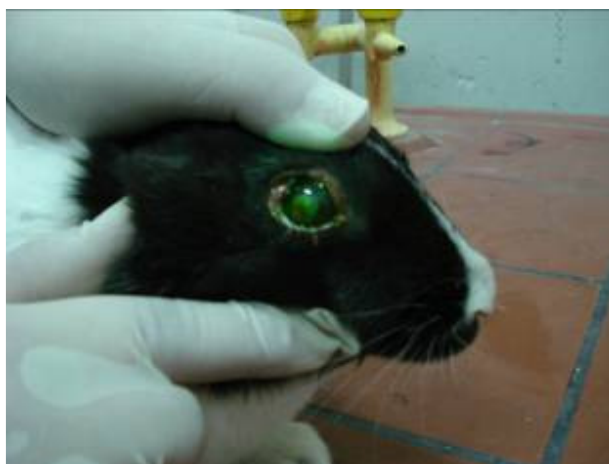

Figure 3: Ulcer is stained with green color.

### Clinical evaluation

External and detailed ophthalmic examinations of each eye were done once daily. Eyes were examined for the presence of perforation, vascularization, lacrimation, photophobia, eye lids adhesion, pus, or infection.

### Histopathological examination

On the day 1<sup>st</sup>, 3<sup>rd</sup>, 5<sup>th</sup>, 10<sup>th</sup>, post induced corneal ulcer sacrificing the animals, the anterior chamber of eye was entered with a scalpel blade, and the entire cornea was excised from the eye with corneal scissors. Corneas were immediately placed in 10% formalin. Following fixation, routine tissue processing, the tissues section were stained with Hematoxylin–Eosin (H&E) (11). Histopathological section and staining were done at Anatomy Department of Veterinary Medicine College / Basrah University.

### Results

#### Clinical findings

The clinical observation was exhibited by examination of the eye after induced corneal ulcer immediately. Table (1) represents the results.

#### Histopathological findings

**Control group:** At day 1 of induced corneal ulcer, the site of ulcer characterized by vascularization and inflammatory cells (neutrophil). (figure 4), at day 3 and 5, show congestion, proliferation of layer of cornea and increase of fibroblast. While at day 10, shows thickness and appear scar tissue (figure 5).

**Propolis treated group:** At day 1 post induced corneal ulcer show uniform of epithelium and increase of inflammatory cells (figure 6) at day 3 show proliferation of corneal epithelium. At day 5 show increase the inflammatory cells infiltration of epithelial stroma). While at day 10 the corneal healing is complete (figure 7).

Table (1): Clinical finding of induced corneal ulcer in rabbits with different treatment on different days post ulcer induced.

Group	day 1	day 3	day 5	day 10
Control	Ulcer with photophobia lacrimation	Ulcer with conjunctival edema & pus	Ulcer with conjunctival edema & pus	Opacity
Dexamethasone	Ulcer with photophobia lacrimation	Ulcer with pus	Normal	Normal
Gentamicin	Ulcer with photophobia lacrimation	Ulcer with conjunctival edema	Normal	Normal
Propolis	Ulcer with photophobia lacrimation	Clear ulcer	Normal	Normal

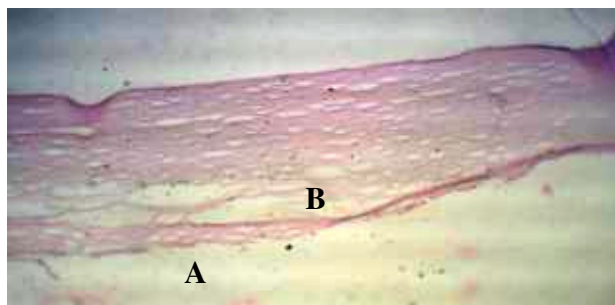


Figure 4: Histopathological section shows vascularization (A) and inflammatory cells (neutrophil) (B) on day 1 post induced ulcer in control group (H&E, 40x).

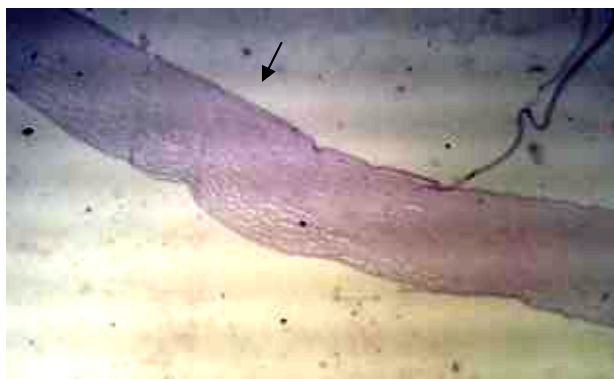


Figure 5: Histopathological section shows thickness and appear scar tissue. On day 10 post induced ulcer in control group. (H&E, 40x).

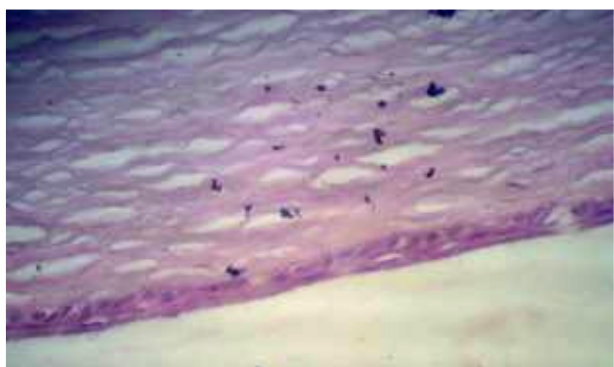


Figure 6: Histopathological section show uniform of epithelium and increase of inflammatory cells on day 1 post induced ulcer in propolis group. (H&E, 100x).

**Gentamicin treated group:** At day 1 post induced corneal ulcer show proliferation of corneal epithelium associated with increase the neutrophil and PMN cells in subepithelium (figure 8). At day 3 show proliferation of

corneal epithelium. At 5 days show increase the inflammatory cells (neutrophil and PMN). While at day 10 show remodeling began the normal cornea (figure 9).

**Dexamethasone treated group:** At day 1 post induced corneal ulcer show increase vascularization with present of inflammatory cells in subepithelium layer. At day 3 increase congestion (figure 10). While day 5 increase thickness and normal epithelium (figure 11).

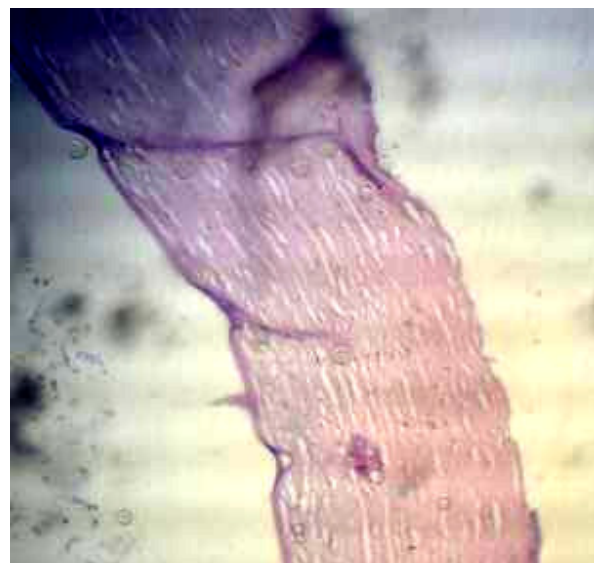


Figure 7: Histopathological section show normal cornea on day 10 post induced ulcer in propolis group. (H&E, 40x).

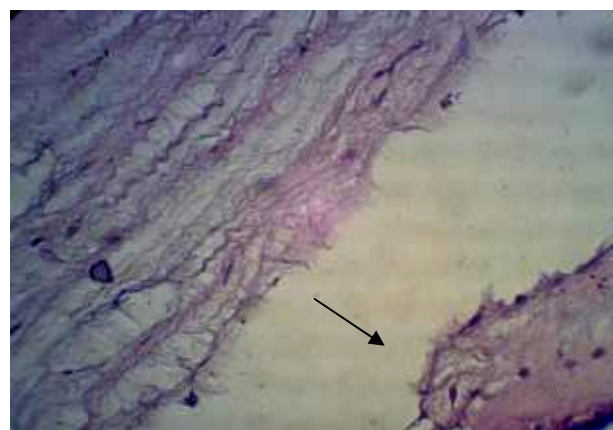


Figure 8: Histopathological section shows proliferation of corneal epithelium associated with increase the neutrophil and PMN cells in subepithelium layer on day 1 post induced ulcer in gentamicin group (H&E, 100x).



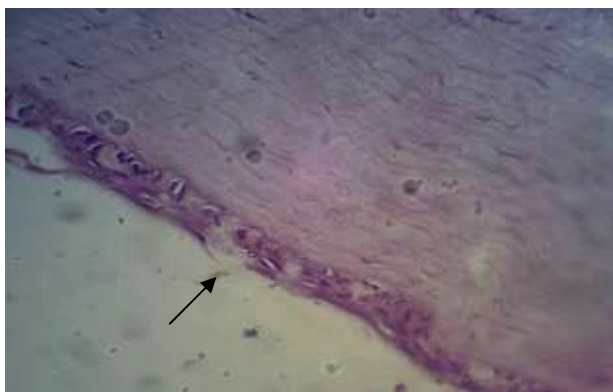


Figure 9: Histopathological section shows remodeling began the normal cornea on day 10 post induced ulcer in gentamicin group (H&E, 100x).

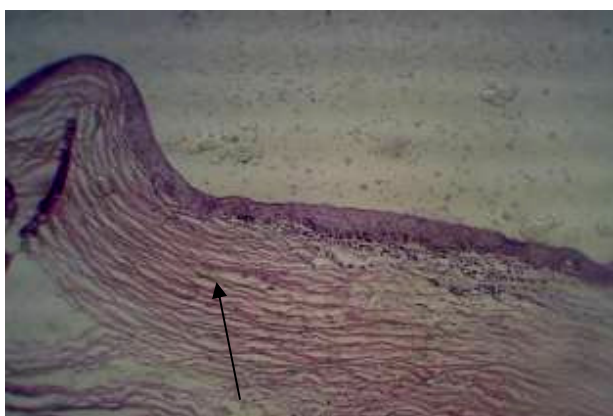

Figure 10: Histopathological section shows vascularization present inflammatory cells in subepithelium layer on day 1 post induced ulcer in dexamethasone group (H&E, 100x).

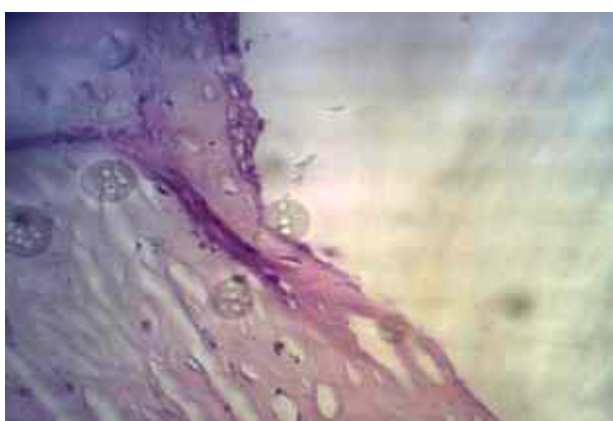

Figure 11: Histopathological section shows normal epithelium layer on day 5 post induced ulcer in dexamethasone group (H&E, 40x).

## Discussion

According to our results, dexamethasone and propolis showed an improvement corneal ulcer, for the first 3 days after the injury, conjunctival edema and eyelid swelling were observed in control and gentamicin groups while these clinical signs are not present in propolis and dexamethasone groups. In histopathological examinations, inflammatory cells infiltration in both the dexamethasone and propolis groups was lower as compared to control and gentamicin groups. These findings indicate that propolis may be an alternative to dexamethasone of corneal ulcer as anti-inflammatory agent.

Also propolis 1% reduced the time necessary for treatment of burn lesions of the eye that agrees with (12). Also other worker said that the propolis was reported to cause inhibition of leukotriene production and prostaglandin formation and to have an important anti-inflammatory effect (13,14).

In previous studies, it has been shown that propolis extract possesses significant anti-inflammatory properties in chronic and acute inflammation comparable to hydrocortisone (13). Aqueous extract of propolis has been found to have an inhibitory activity on the enzyme dihydrofolate reductase similar to the report on well-known Corticosteroids. These properties may explain a part of its anti-inflammatory effect. The anti-inflammatory effect of propolis could be attributed to its contents of flavonoids, phenolic acid and caffeic acid. Flavonoids are reported to inhibit the activity of enzymes involved in the conversion of membrane polyunsaturated fatty acids such as phospholipase A2, cyclooxygenase and lipoxygenase (15).

According to the established anti-inflammatory properties of propolis, one may expect a greater effect of propolis than dexamethasone in our model. We investigated the anti-inflammatory effects of propolis in an acute corneal inflammation model. From the results of this study, propolis has beneficial effects comparable to dexamethasone in the treatment of corneal ulcer.

## References

1. Whitley R C and Gilger BC. Diseases of cornea and Sclera In: Gelatt, K.N: Vet. Opth. Ed3th. Philadelphia, PA, Lippincott Williams And Wilkins. 1999. 635-673.
2. Olivier F H. Bacterial corneal diseases in dogs and cats Clin Tech Small Anim pract. 2003; 18:193-198.
3. Srtatup F G. Corneal ulceration in the dogs. J Small Anim Pract. 1984; 25:737-752.
4. Kern T J. Ulcerative keratitis. Vet clin North Amer Small Anim pract. 1990. 20:643-666.
5. Bankova V. Immunomodulatory action of propolis on macrophage activation. J Venom Anim Toxins. 2000; 6: 205-19.
6. Mirzoeva O K, Calder P C. The effect of propolis and its components on eicosanoid production during the inflammatory response. Prostaglandins Leukot Essent Fatty Acids. 1996; 55:441-449.

7. Ivanovska N, Stefano Z, Valeva V, Neychev H. Immunomodulatory action of propolis: VII. A comparative study on cinnamic and caffeic acid lysine derivatives. *Biol Immun.* 1993; 46:115-117.
8. Hall LW, and Clark K V. *Veterinary anaesthesia* 9<sup>th</sup>.Ed., Great Britain by press Avon. Ltd. Fily, North.Your-shir: 1991.330-350.
9. Ormerod LD, Abeslon M B and Kentton K R. Standard models of corneal injury using Alkali immersed filter discs. *Invest Ophthalmol. Vis Sic.*1989; 30:2148-2153.
10. Feenstra R P and Tseng SC. Comparison of Fluorescein and Rose Bengal Staining. *ophthalmic Res.*1992.605-617.
11. Luna L G. *Manual of histological staining methods of armed forces institute of pathology.*3<sup>rd</sup> ed. New York. McGraw HillBook Company. 1968. pp38-76.
12. Faruk O, Emin K and Sami I. The effect of propolis extract in experimental chemical corneal injury. *ophthalmic Res.* 1999; 32:13-18.
13. Dobrowolski JW, Vohoraq S B, Sharma K and Shah SA. Antibacterial, antifungal, anti-inflammatory and antipyretic studies on propolis bee products.*J Ethno.* 1991; 35:77-82.
14. Volpert R and Elstner EF. interactions of different extracts of propolis with leukocytes and leukocytes enzymes. *Arzneimittelforschung.* 1996; 46:47-51.
15. Krol W, Scheller S, Czuba Z, Matsumo T, Zydowicz G, Shani J, Mos M. Inhibition of neutrophils' chemiluminescence by ethanol extract of propolis (EEP) and its phenolic components. *J Ethnopharmacol.* 1996; 55: 19-25.